TURKISH ASSOCIATION OF ORAL AND MAXILLOFACIAL SURGERY

TAOMS'20

27th INTERNATIONAL SCIENTIFIC CONGRESS

27th- 30th SEPTEMBER

PROCEEDING BOOK

www.taoms2020.org

CONTENTS

TAOMS'20

COMMITTEES

www.taoms2020.org

TAOMS'20

Turkish Association Of Oral and Maxillofacial Surgery

27th INTERNATIONAL SCIENTIFIC CONGRESS

27th – 30th SEPTEMBER 2020

President of the Association
Mustafa Sancar ATAÇ

Secretary of the Association
Sırmahan ÇAKARER

Presidents of Congress
Çağrı DELİLBAŞI

Secrataries of Congress
Sabri Cemil İŞLER
Gökhan GÜRLER

SCIENTIFIC COMMITTEE

Ergun YÜCEL (Başkan)
Ahmet ARSLAN
Ashraf MESSIHA (İngiltere)
Ayşegül TÜZÜNER
Bahar GÜRSOY
Banu G. KÖSEOĞLU
Barış ŞIMŞEK
Belgin GÜLSÜN
Chingiz RAHİMOV (Azerbaycan)
Enis REDZEP (Makedonya)
Gabriella MILLESEI (Avusturya)
Hasan YELER
Henri DIEDERICH (Lüksemburg)
Hülya K. BERBEROĞLU
Jean Paul MENINGAUD (Fransa)
Jan de VISSCHER (Hollanda)
Manile GALIE (İtalya)
Nur MOLLAOĞLU
Nükhet KÜTÜK
Rabul JAYARAM (İngiltere)
Rana MAJEED (Almanya)
S.M BALAJI (Hindistan)
Siegfried JAENICKE (Almanya)
Tomas ALBREKTSSON (İsveç)

ORGANIZATION COMMITTEE

Çetin KASAPOĞLU (Başkan)
Başak KESKİN YALÇIN
Burak ÇANKAYA
Ertan YALÇIN
Fatma ZOR
Hatice HOŞGÖR
Kemal TÜMER
Mehmet Emin TOPRAK
Nergiz YILMAZ
Onur Lokman UYANIK
Ömür DERECİ
Süleyman BOZKAYA
Yeliz KILINÇ
Zekai YAMAN
Zeynep GÜMRÜKÇÜ

TECHNICAL COMMITTEE

Mehmet Ali ERDEM (Başkan)
Berk KASAPOĞLU
Çağrı BURDURLU
Sercan KÜÇÜKKURT
Sümer MÜNEVVEROĞLU

AWARD COMMITTEE

Hanife ATAOĞLU (Başkan)
Gökçe MERAL
Nurhan GÜLER
Uğur TEKİN

TAOMS'20

INVITED SPEAKERS

www.taoms2020.org

TAOMS'20

Turkish Association Of Oral and Maxillofacial Surgery

27th INTERNATIONAL SCIENTIFIC CONGRESS

27th – 30th SEPTEMBER 2020

Tomas ALBREKTSSON
Professor em.
Dept. Biomaterials, Uni of Gothenburg

Süleyman BOZKAYA
Associate Professor
Dokuz Eylül University Faculty of Dentistry.

Erol CANSIZ
Associate Professor
Istanbul University, Faculty Of Dentistry, Oral and Maxillofacial Surgery Department

Henri DIEDERICH
DDS
Private Dental Clinic

Ümit ERTAŞ
Professor
Atatürk Universty

Manlio GALIE
Professor
Hospital And University "St.anna" Ferrara – Italy

Siegfried JAENICKE
Professor
General Hospital Osnabrueck Germany

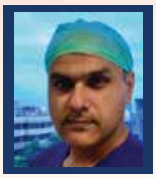

Rahul JAYARAM
Professor
St.George Hospital London

Erdem KILIÇ
Professor
Bezmialem Vakif University

Majeed RANA
Professor Dr.
Duesseldorf University Hospital
Center for Operative Surgery

Meningaud JEAN-PAUL
Professor
Henri Mondor Teaching Hospital

Ashraf MESSIHA
Professor
St.George Hospital London

Gabriele MILLESI
Dr Dept of CranioMaxillofacial Surgery,
Medical University Vienna

Chingiz RAHIMOV
Azerbaijan Medical University, Department of Oral and Maxillofacial surgery, Azerbaijan, Baku

TAOMS'20

FULL TEXTS

www.taoms2020.org

ORAL PRESENTATIONS / FULL TEXT

OP-2

Retrospective Evaluation of the Characteristics of Admissions to the Oral and Maxillofacial Surgery clinic in Early Covid-19 Period

Mehmet Melih Ömezli [a], Ferhat Ayrancı [b], Damla Torul[c], Tolunay Avcı [d]

[a]Department of Oral and Maxillofacial Surgery, Faculty of Dentistry, Ordu University, Ordu mmelihomezli@odu.edu.tr

[b]Department of Oral and Maxillofacial Surgery, Faculty of Dentistry, Ordu University, Ordu ferhatayranci@odu.edu.tr

[c]Department of Oral and Maxillofacial Surgery, Faculty of Dentistry, Ordu University, Ordu damlatorul@gmail.com

[d]Department of Oral and Maxillofacial Surgery, Faculty of Dentistry, Ordu University, Ordu tolunayavci@odu.edu.tr

Abstract

Objective: The new type of coronavirus 2019-nCoV, which emerged in Wuhan, China in late 2019, and has rapidly spread all over the world, has changed the routine practice in many fields as well as in dentistry. In the period between mid-March to June, only non-deferral, emergent treatments were performed. The aim of this report is to retrospectively evaluate characteristics of admissions in this period.

Methods: Patients who were applied to our clinic between 19/03/2020-01/06/2020 examined retrospectively. Patient information, date of visit, reasons for application were obtained from the archival records.

Results: Between 19/03/2020-01/06/2020, a total of 437 patients were admitted to our clinic. The ages of the patients were between 2-86 years. The complaints of the patients admitted in this period were include pulpitis, infection and abscess(%50), trauma(0.8%), pericoronitis(6%),temporamandibular disorder(1%), oro-antral communation(0.4%),cyst (0.2%), alveolar osteitis(1%), suture(5%) and other reasons (35.6%).

Conclusion: In pandemic periods, it can be imperative to perform non-deferral treatments, such as dental emergencies, but high risk of transmission for the physician and the patient also present. Thus, it is important to consider applications such as patient triage, determination of non-deferrable emergencies, performing interventions by taking necessary precautions, posponing non-emergent treatments. and to reduce unnecessary patient crowd in clinics. The choice of surgical technique should be based on careful evaluation, compliance with treatment principles to simplify the intervention and reduce working times.

Keywords: Covid-19, Emergencies, Oral Surgery

Introduction

In December 2019, a disease characterized by flu-like symptoms caused by a new type of coronavirus occurred in Wuhan, China. This new type of coronavirus, which rapidly spreads and has been declared a pandemic, has been named the World Health Organization 2019-nCov. The virus is thought to spread from person to person, mainly through respiratory droplets and close contact, or through direct contact with the blood and body fluids of infected patients.

The new type of coronavirus disease (COVID-19) has a long incubation period and is highly contagious.(1-3). Infection control measures are necessary to prevent further spread of the virus and help control the outbreak situation (4). It is inevitable for the oral and maxillofacial surgeons to contact the oral cavity, airway and the patient's secretions (saliva, mucus, blood, etc.) during the diagnosis and treatment process. This makes oral and maxillofacial surgeons one of the occupational groups in the high-risk category (5).

This study is aimed to analyze the characteristics of patients who were applied to our clinic during the period between 19.03.2020- 01.06.2020.

Methods

Patients who visited our clinic between 19.03.2020-01.06.2020 were scanned retrospectively from the archive records. In patients who applied to the clinic between this time period body temperature was measured first and a consent for special for COVID-19 was given before dental treatment. In the consent form following informations were provided.

1.Do you have fever or have you experienced fever within the past 14 days?

2. Have you experienced a recent onset of respiratory problems, such as a cough or difficulty in breathing within the past 14 days?

3. Have you, travelled to risk areas or visited neighborhood within the past 14 days, with documented 2019-nCoV transmission?
4. Have you come into contact with a patient with confirmed 2019-nCoV infection within the past 14 days?
5. Have you recently participated in any gathering, meetings, or had close contact with many people you are not acquainted with?

Patient information such as date of visit, gender, age were recorded. The total number of patient visits and type of visits were compared with statistics corresponding to the same time period in 2019.

Results

The total number of patients admitted to the oral and maxillofacial surgery clinic between 19.03.2020-01.06.2020 was 473, and 52% of these patients were female. The mean age of the patients was 29.94. The youngest patient was 2 years old, the oldest was 86 years old. Pain (pulpitis, infection, abscess) constituted 60% of the reasons for application. The reason for applications were include pulpitis, infection and abscess(%50), trauma(0.8%), pericoronitis(6%),temporamandibular disorder(1%), oro-antral communation(0.4%),cyst (0.2%), alveolar osteitis(1%), suture(5%) and other reasons (35.6%).Tooth extraction was the most common procedure during this period. Unless necessary, procedures that form aerosol were avoided. None of the patients had any confirmed or suspected history of COVID-19 or showed symptoms of COVID-19.

Discussion

Patient screening is very important during the outbreak(6). In a previous study, fever was reported to be the most common clinical symptom (98%) in 41 patients diagnosed with COVID-19(7). Therefore, fever should be measured in all patients who were applied.

However, various infections of the oral cavity can manifest with fever. Therefore, the only sign and symptom of COVID-19 to be evaluated should not be fever alone. Oral pathologies needs to be

accurately diagnosed. The diagnosis of COVID-19 is currently based on a combination of epidemiological information, clinical symptoms, chest computed tomographic imaging findings, and laboratory tests such as reverse transcription polymerase chain reaction (RT-PCR) (8).

The incubation period of COVID-19 is estimated to be between 2 and 14 days. Patients who have no symptoms or were in incubation period may also infect others (9). In addition, positive RT-PCR test results have been reported in healed patients(10). Therefore, maxillofacial surgeons should take precautionary measures with N95 masks, gloves, shoe covers, face shields and aprons, and the other necessary protective equipment.

In this epidemic period, we have adopted the principles of simplifying the operation by trying to avoid very complicated surgical techniques in order to shorten the operation time (5).

Because of 2019-nCoV is vulnerable to oxidation, mouthwash containing 1% hydrogen peroxide or 0.2% povidone can be used. Studies have shown that povidone iodine effectively reduces the number of droplets and aerosols produced during oral operations(11-13).

The mean age of patients applying for emergencies was 29.94. More importantly, older age and the presence of underlying comorbidities are associated with the worse COVID-19 prognosis(14, 15)

Conclusions

Significant changes in the outpatient, inpatient and operating theater infrastructures are needed to take adequate precautions for the COVID-19. The choice of surgical technique should be based on careful evaluation and compliance with treatment principles to simplify the intervention and reduce working times. The main purpose is to protect patients and the healthcare team from unnecessary infections and to ensure that the health system works effectively.

References

1.Yang Y, Soh HY, Cai ZG, Peng X, Zhang Y, Guo CB. Experience of Diagnosing and Managing Patients in Oral Maxillofacial Surgery during the Prevention and Control Period of the New Coronavirus Pneumonia. Chin J Dent Res. 2020;23(1):57-62.

2.Lu R, Zhao X, Li J, Niu P, Yang B, Wu H, et al. Genomic characterisation and epidemiology of 2019 novel coronavirus: implications for virus origins and receptor binding. Lancet. 2020;395(10224):565-74.

3.Zou L, Ruan F, Huang M, Liang L, Huang H, Hong Z, et al. SARS-CoV-2 Viral Load in Upper Respiratory Specimens of Infected Patients. N Engl J Med. 2020;382(12):1177-9.

4.Tian-jia Z, Ting L, Song-yuan L, Li-ya Y, Yan X, Min Z, et al. Instructions for management of oral, maxillofacial trauma during prevention, control stage of the novel coronavirus infection. 2020;18(2):100.

5.Barca I, Cordaro R, Kallaverja E, Ferragina F, Cristofaro MG. Management in oral and maxillofacial surgery during the COVID-19 pandemic: Our experience. Br J Oral Maxillofac Surg. 2020.

6.Samaranayake LP, Peiris M. Severe acute respiratory syndrome and dentistry: a retrospective view. J Am Dent Assoc. 2004;135(9):1292-302.

7.Huang C, Wang Y, Li X, Ren L, Zhao J, Hu Y, et al. Clinical features of patients infected with 2019 novel coronavirus in Wuhan, China. Lancet. 2020;395(10223):497-506.

8.Meng L, Hua F, Bian Z. Coronavirus Disease 2019 (COVID-19): Emerging and Future Challenges for Dental and Oral Medicine. J Dent Res. 2020;99(5):481-7.

9.Sohrabi C, Alsafi Z, O'Neill N, Khan M, Kerwan A, Al-Jabir A, et al. World Health Organization declares global emergency: A review of the 2019 novel coronavirus (COVID-19). Int J Surg. 2020;76:71-6.

10.Lan L, Xu D, Ye G, Xia C, Wang S, Li Y, et al. Positive RT-PCR Test Results in Patients Recovered From COVID-19. Jama. 2020.

11.Kariwa H, Fujii N, Takashima I. Inactivation of SARS coronavirus by means of povidone-iodine, physical conditions, and chemical reagents. Jpn J Vet Res. 2004;52(3):105-12.

12.Eggers M, Koburger-Janssen T, Eickmann M, Zorn JJId, therapy. In vitro bactericidal and virucidal efficacy of povidone-iodine gargle/mouthwash against respiratory and oral tract pathogens. 2018;7(2):249-59.

13.Peng X, Xu X, Li Y, Cheng L, Zhou X, Ren B. Transmission routes of 2019-nCoV and controls in dental practice. Int J Oral Sci. 2020;12(1):9.

14.Chen N, Zhou M, Dong X, Qu J, Gong F, Han Y, et al. Epidemiological and clinical characteristics of 99 cases of 2019 novel coronavirus pneumonia in Wuhan, China: a descriptive study. Lancet. 2020;395(10223):507-13.

15.Wang D, Hu B, Hu C, Zhu F, Liu X, Zhang J, et al. Clinical Characteristics of 138 Hospitalized Patients With 2019 Novel Coronavirus-Infected Pneumonia in Wuhan, China. Jama. 2020.

OP- 5

LARGE RADICULER CYSTS OF MAXİLLA: CASE SERIES

Hilal Alan [a], Canan Gökçe Kulfel [a], Ferhat Musulluoğlu [a]

A- Inonu University, Faculty of Dentistry, Department of Oral and Maxillofacial Surgery, Turkey, ferhat.musulluoglu@inonu.edu.tr

Abstract

Objectives: Radicular cysts, which are odontogenic cysts, usually grow slowly, rarely reach large size and cause the dextration of surrounding structures. Cysts can cause mobility, displacement and root resorption in adjacent teeth. In this case series, we aimed to present the treatment stages of large odontogenic cyst cases in the maxilla.

Case report: Case 1: A 19-year-old male patient presented to our clinic with complaints of pain and swelling in the maxillary right area. After examination, a radiolucent lesion with prominent borders and extending into the inftaorbital region was detected. The cyst was enucleated under general anesthesia and the treatment of the relevant teeth was completed.

Case 2: A 44-year-old male patient presented to our clinic with pain and swelling in the maxillary left area, with bad smell and pus flow through the nose. After examination, a large, radiolucent lesion was detected in the maxillary left region. The cyst was enucleated under general anesthesia and the treatment of the relevant teeth was completed.

Case 3: A 19-year-old woman presented to our clinic with pain in the maxillary left area. After examination, a large, distinctive, radiolucent lesion was detected. The patient was operated under general anesthesia and the treatment of the related teeth was completed.

Conclusion: The usual surgical treatments for radicular cysts include total enucleation of small lesions, marsupialization for decompression of larger cysts or a combination of these techniques. It was successfully treated with surgical removal of the cyst following treatment of the affected teeth in all cases.

Key words: Odontogenic cyst, radicular cyst, maxilla

1.Introduction

Radicular cysts are one of the most common cysts in the maxillofacial region. The incidence of radiculer cyst is greater in the third to sixth decades and shows a slight male predominance (1). Most of the radicular cysts are found in the maxilla, especially around incisors and canines (2).

Radicular cysts are commonly asymptomatic unless infected, and discovered during routine radiographic examination (1,3). Radicular cysts appear as round or oval, unilocular or multilocular, radiolucent lesions with prominent borders. they are usually asymptomatic and grow slowly. They rarely reach large sizes and can cause dextrication in adjacent tissues, mobility and displacement of adjacent teeth. The purpose of our case is to describe the presentation and treatment of large radicular cysts that include the maxillary sinus.

2. Case Report

Case 1: A 19-year-old male patient presented to our clinic with complaints of pain and swelling in the maxillary right area and pain in the head movements. After intraoral and radiographic examination, a radiolucent lesion with prominent borders including the premolar and molar tooth roots and extending into the infraorbital region was detected (Figure 1). Computed tomography was taken

from the patient for three-dimensional evaluation (Figure 3). Enucletion of cyst under general anesthesia was performed. Root of tooth number 15 in the relevant region was removed. Root canal treatment was applied to tooth number 16 during surgery and apical resection was performed. In the 9-month follow-up, the patient was asymptomatic and new bone formation was observed radiographically in the region (Figure 2). In the postoperative period, the maxillary sinus mucosa healed and no symptoms were observed.

Case 2: A 44-year-old male patient presented to our clinic with pain and swelling in the maxillary left area, with bad smell and pus flow through the nose. After the intraoral and radiographic examination, a large, radiolucent lesion including the maxillary left premolar and molar teeth extending from the lateral wall of the nose to the infraorbital region was detected (Figure 4,5). Under general anesthesia, enucleation of the cyst was performed and supernumerary tooth in the maxillary anterior were removed (Figure 6), and apical resection was performed on teeth 21-22-23 and 24 (Figure 7). New bone formation was observed in the relevant region after 6 months (Figure 9).

Case 3: A 19-year-old woman presented to our clinic with pain in the maxillary left area. As a result of the intraoral and radiographic examination, a large, distinctive, radiolucent lesion containing maxillary left premolar and molar tooth roots and containing the number 28 tooth was detected (Figure 10). Computed tomography was taken from the patient for three-dimensional evaluation (Figure 11). Under general anesthesia, enucleation of the cyst was performed and apical resection was applied to teeth number 25 and 26 after root canal treatment (Figure 12). Teeth 27 and 28 associated with the cyst were removed. The area was sutured and a drain was placed (Figure 13). The patient was asymptomatic after 1 year of follow-up (Figure 15).

3. Discussion

Radicular cysts are discovered either by bone deformation and inflammation or by chance during routine radiographic examination (2). The most common of maxillary lesions are odontogenic cysts with 52 % of jaw cystic lesions and it presents 60 % times more in maxilla than in mandible (1).

Radicular cysts generally originate after trauma or dental caries. Dental caries cause inflammation of the pulp cavity, leading to pulp necrosis (4). The infection then spreads to the tooth apex of the root, causing periapical periodontitis, which leads to either an acute abscess or a chronic granuloma. Persistent chronic infection can lead to formation of a periapical cyst (5).

As in our case, panoramic radiography is insufficient, especially in large cysts associated with maxillary sinuses. CBCT has advantages such as full evaluation of the relationship of the lesion with anatomical structures such as nasal cavity and orbit, and providing more detailed information about the size of the lesion. It is also useful for comparing pre and postoperative lesions.

The treatment of the radicular cysts is determined in association with the type and volume of the lesion. Small cysts usually heal up with successful endodontic treatment (6). In large lesions, complete removal of the cyst after marsupialization is one of the treatment options. In our cases, the cyst was completely enucleated due to the fact that the cyst was associated with the maxillary sinus and the risk of developing a pathological fracture was low due to its location.

4. Conclusion

The orthopantomography performed once a year may discover the presence of the maxillary cysts in incipient stages, thus avoiding the massive bone destructions, which may result due to the extensive growth of cystic lesions. In such cases, we believe that patients should be evaluated preoperatively with computed tomography in addition to panoramic radiographs and their treatment should be planned in cooperation with the department of endodontics.

5. References

1. Shear, M. & Speight, P. Cysts of the Oral and Maxillofacial Regions. Oxford, Wiley-Blackwell, 2007. pp.123-42.

2. Riviş, M., and ADINA NORA Văleanu. "Giant maxillary cyst with intrasinusal evolution." *Rom J Morphol Embryol* 54.3 (2013): 889-892.

3. Neville BW, Damm DD, Allen MC, Bouquot JE. Oral and Maxillofacial Pathology. 3rd ed. Philadelphia: Elsevie; 2010.

4. LM Lin, GT Huang, PA Rosenberg. Proliferation of epithelial cell rests, formation of apical cysts, and regression of apical cysts after periapical wound healing. J Endod. 2007;33:908–16.

5. AL Weber, T Kaneda, SJ Scrivani, Jaw Aziz S. Head and neck imaging. 4th Edition. Mosby: St. Louis, MO; 2003. tumors and nontumorous lesions. In: Som PM, Curtin HD, eds; pp. 930–934.

6. Kose, Emre, et al. "Giant radicular cyst with bilateral maxillary sinus involvement." *Journal of Oral and Maxillofacial Radiology* 2.2 (2014): 52.

6. Figures

Figure 1: Preoperative Radiographic View Of Case 1

Figure 2: Radiographic view of case 1 after 9 months postoperatively

Figure 3: Coronal and Sagittal Section CT View Of Case 1

Figure 4: Preoperative Radiographic View Of Case 2

Figure 5: Coronal Section CT View Of Case 2

Figure 6: Cyst Epithelium And Maxillary Defect Of Case 2

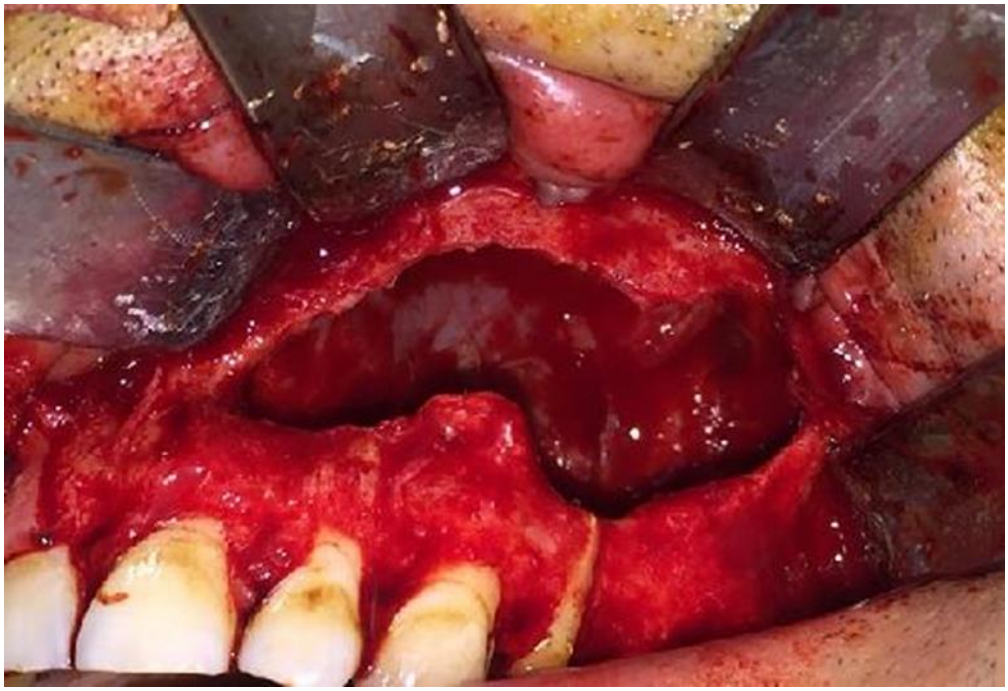

Figure 7: Removal The Cyst Of Case 2

Figure 8: Surgical Specimen Of Case 2

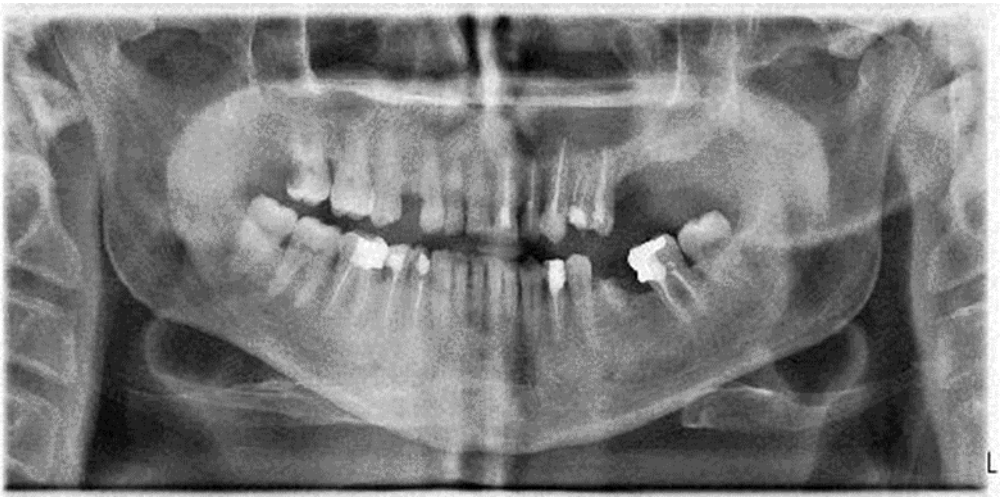

Figure 9: Radiographic View Of Case 2 After 6 Months Postoperatively

Figure 10: Preoperative Radiographic View Of Case 3

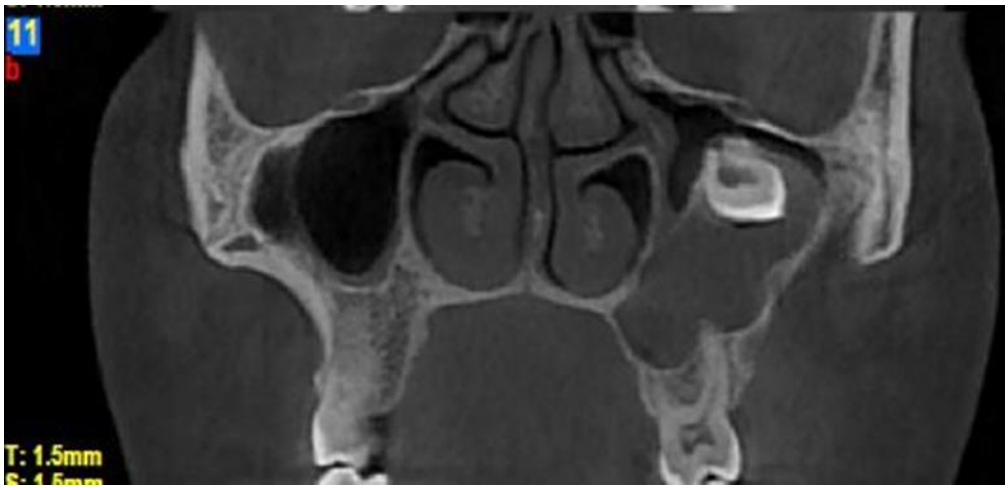

Figure 11: Coronal Section CT View Of Case 3

Figure 12: Cyst Epithelium And Maxillary Defect Of Case 3

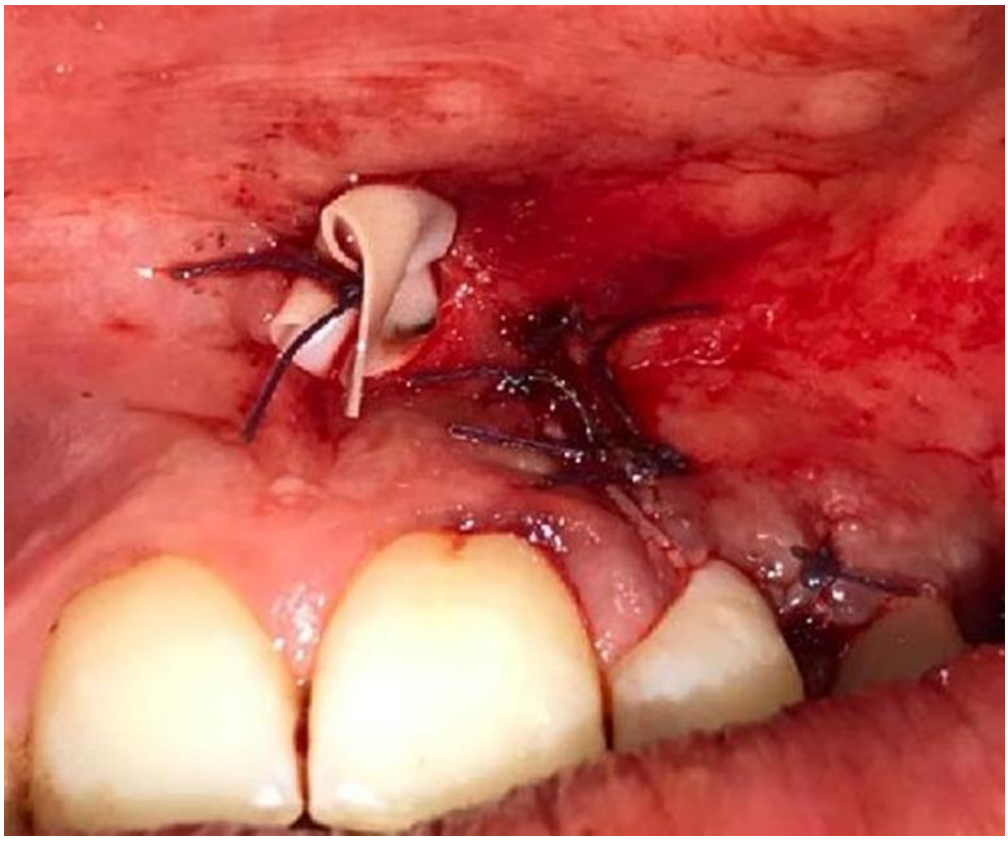

Figure 13: Suturing Of The Area And Drain Placement Of Case 3

Figure 14: Surgical Specimen Of Case 3

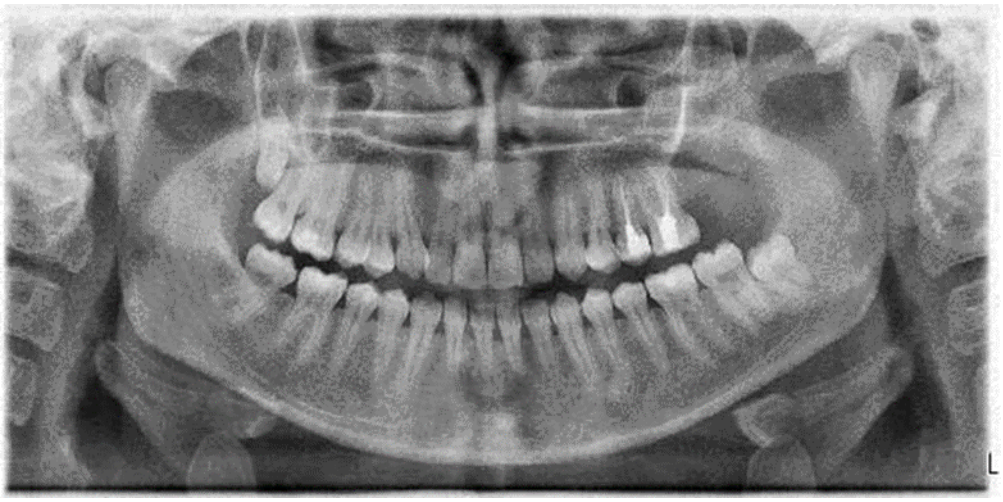

Figure 15: Radiographic View Of Case 3 After 12 Months Postoperatively

OP-6

CONDYLAR HYPERPLASIA AND IT'S SURGICAL TREATMENT IN AN ADULT PATIENT

Efe Gökahmetoğlu[a], İrem Barış Akbaş[b], Sevil Kahraman[c]

A- Gazi University,Faculty of Dentistry, Department of Oral and Maxillofacial Surgery, Turkey
dtefegok@gmail.com

B- Gazi University,Faculty of Dentistry, Department of Oral and Maxillofacial Surgery, Turkey
irembaris94@gmail.com

C- Gazi University,Faculty of Dentistry, Department of Oral and Maxillofacial Surgery, Turkey
skahraman@gazi.edu.tr

Abstract

Objectives: Condylar hyperplasia is a bone disease characterized by increased growth in a mandibular condyle. Generally painless condition leads to facial asymmetry and occlusion disorder. There is no clear consensus between orthodontists and surgeons in the treatment of this rare condition. In this report, it was aimed to discuss the course, clinical, diagnostic and therapeutic aspects of the disease and explain the role of condylectomy through a case we manage.

Case report: A 35-year-old male patient was admitted to our clinic with the complaint of the lower jaw shifting to the right when opening mouth. After the radiological and clinical examination, it was found that the left mandibular condyle head was 2 times larger than the right condyle head and the lower dental midline was shifted 10 mm to the right while in function and at rest.With extraoral access, the hypertrophic joint head was completely removed and the capsule was preserved and the surgical procedure was

completed. Immediately after the surgical procedure, it was observed that the dental midline was in place and maintained its position during functional movements. In the patient who underwent intermaxillary fixation with a 2- week interval, no postoperative change in the mandible was observed during the 6-month post-operative follow-up.

Conclusion: This extremely rare condition can lead to an aesthetic appearance and various functional clinical problems. Therefore, having information about the management, differential diagnosis and treatment of these cases is important for all dentists

Keywords: Facial assymetry, condylar hyperplasia, condylectomy

1. Introduction

Condylar hyperplasia characterized by excessive growth of condyles is a rare, unilateral, pathological condition of the mandible that is likely to occur in both sexes. The cause of this hyperplasia has not been fully revealed. However, possible etiological factors include local circulation problems, hormonal disorders, trauma and exposure to abnormal force.2 Solitar condylar hyperplasia is often seen unilaterally and can cause deviation of the jaw to the unaffected side, cross-closure on the unaffected side, back-open closure on the affected side due to the growth rate of the condyle and hyper eruption of the maxillary teeth, and resulting in varying severity of facial asymmetry and malocclusion. Generally reported symptoms are restricted mouth opening, deviation, pain in the TMJ region, and joint sounds. (1)

Various methods including histopathological examination, clinical and radiographic evaluation and scintigraphy are used in the diagnosis of condylar hyperplasia.2 Differential diagnosis of condylar lesions includes condylar hyperplasia, giant cell tumor, fibroosteoma, myxoma, fibrous dysplasia, fibrosarcoma, chondrosarcoma, and osteochondroma. (1,2)

Condylar hyperplasia is treated with various surgical methods or orthodontic splints, depending on the type of disease, the age of the patient, the level of growth activity and the severity of facial asymmetry. (1)

2. Case Report

35-year-old male patient was admitted to our clinic with the complaint of the lower jaw shifting to the right when opening mouth which developed in 6 months. His main complaint was having difficulty in eating. The patient had no previous treatment or trauma history and no systemic disease.

On clinical examination, it is observed that the tip of the jaw was positioned to 10mm right in relation to the facial midline, and the mandible was prognathic. There was no pain, edema and noise in the TMJ examination, but there was limited mouth opening and significant deviation to the right side while mouth opening. In intraoral examination, class 2 relationship on the right , class 3 canine and molar relationships on the left side and cross bite in the right posterior segment are detected.

When panoramic and CT images were evaluated, approximately 2 times more homogenous growth was detected in the left condylar head compared to the right.

With extraoral access, the hyperplastic joint head was completely removed and the capsule was preserved and the surgical procedure was completed. Immediately after the surgical procedure, it is observed that the dental midline was in place and maintained its position during functional movements. The histopathological result of the extracted material overlaps with hyperplasia. Reactive osteoid and cartilage tissue were observed on the bone tissue surface.

In the patient who underwent intermaxillary fixation with a 2-week interval, no postoperative change in the mandible was observed during the 6-month post-operative follow-up. Aesthetic and functional complaints of the patient are disappeared.

3. Discussion

CH resulting in facial asymmetry is not only an esthetic problem for an individual, but also a functional disturbance to the TMJs and occlusion. CH of the TMJ is a rare pathology that was first described by Adam's in 1836 as overgrowth of the mandibular condyle; comparable pathology has not been described in any other joint. The etiology of CH is still unclear. Previous authors have debated whether intrinsic or extrinsic factors regulate the growth of the condyle. Based on these theories, local circulatory problems, previous trauma, hormonal disturbances, abnormal loading and cartilaginous exostosis have been suggested as possible etiologic factors.(3) In our case, parafunctional occlusion and bruxism were thought to be an etiological factor.

If the deformity has occurred before growth is complete the occusal plane is usually slanted because of dental compensation, whereas posterior open bite is usually apparent if the deformity occurs after completion of growth as shown in our case. treatment varies depending on the presence of active growth. While orthognathic surgery is applied in inactive cases, condylectomy is preferred in cases with active growth. (3)

It has been stated that mandibular growths that develop after the age of twenty are generally associated with osteochondroma, osteoma or other proliferative condylar pathologies. (4) However, our case supports benign hyperplastic growth as a result of histopathological examination. Obwegeser and Makek reported that the term "condylar hyperplasia" only describes the hyperplasia of the condyle, and the conditions accompanied by mandibular growth are mandibular anomalies that differ from solitary HR and from each other. this case exemplifies solitary condylar hyperplasia with an increase in growth only at the head of the condyle seen in ct examinations.(1)

4. Conclusion

It should be taken into consideration that active growth may continue as well as pathological conditions involving bone in adult patients presenting with a rapidly developing facial asymmetry. Detailed TMJ examination should be performed for diagnosis. Although panoramic radiographs are helpful, detailed CBCT imaging and scintigraphy method are also important in determining growth areas.

5. References

1 Yılancı ÖA kkaya N., Özbek M., Terminology and classification of condylar hyperplasia: Two case reports and review, Kulak Burun Bogaz Ihtis Derg 2015;25(6):367-374 367 Derleme / Review doi: 10.5606/kbbihtisas.2015.08068

2 Giray B., Aktaş A., Ötemer K., Taner T., Akcan C., Meral G., Öten S., Condylar Hyperplasia in an Adult Patient Hacettepe Diş Hekimliği Fakültesi Dergisi Cilt: 32, Sayı: 3, Sayfa: 450, 2008

3 Saravana C. Bharathi, S. Senthilnathan, Lokesh D. Kumar, Anand C. S. Mohan, M. Taranath, Unilateral condylar hyperplasia: A case report and review of literatüre J Int Soc Prev Community Dent. 2014 Jan-Apr; 4(1): 67–70. doi: 10.4103/2231-0762.127853

4 Alyamani A., Abuzinada S., Management of patients with condylar hyperplasia: A diverse experience with 18 patients, Ann Maxillofac Surg. 2012 Jan-Jun; 2(1): 17–23, doi: 10.4103/2231-0746.95311

6. Figures

Figure 1: Preoperative appearence

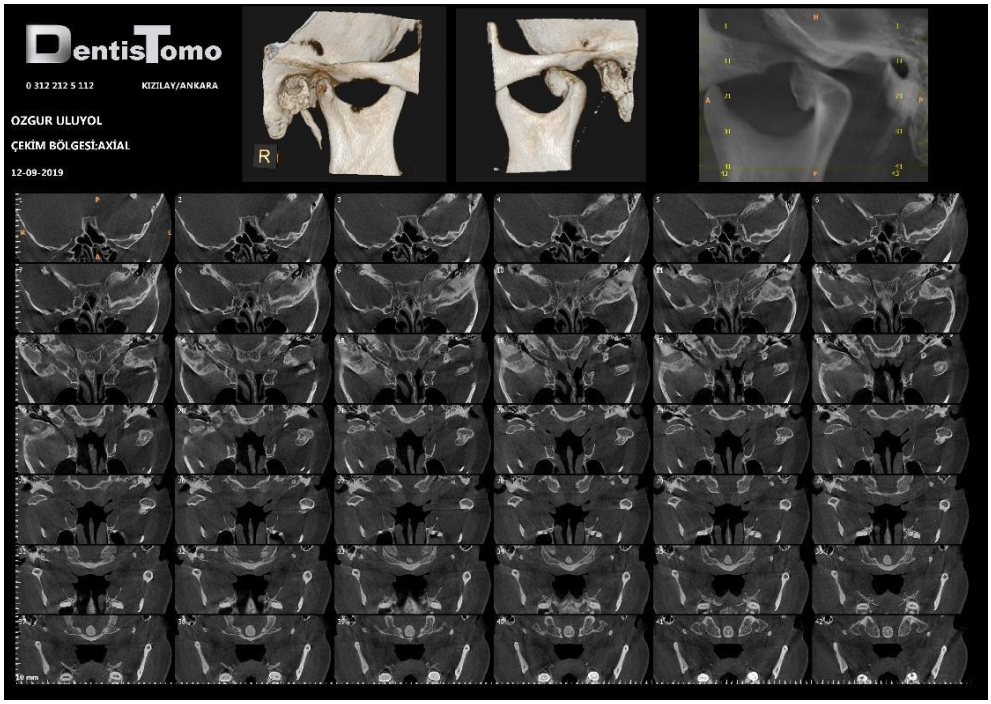

Figure 2: CT views

Figure 3: Removed material

Figure 4: Postoperative control

OP- 9

AN ALTERNATIVE FULL-FACE MASK FOR COVID-19 PROTECTION IN ORAL SURGERY

Anıl Özyurt [a]

A-Trakya University, Faculty of Dentistry, Department of Oral and Maxillofacial Surgery, Turkey
anilozyurt@trakya.edu.tr

Abstract

Objective: This study aims to introduce a SCUBA full-face mask system for COVID-19 protection and to test it in terms of comfortability.

Materials and Methods: An oral surgeon tested the SCUBA full-face mask system on himself by with or without using. **E**nd-tidal carbon dioxide ($EtCO_2$), respiratory rate (RR), peripheral oxygen saturation (SpO_2), heart rate (HR), blood pressure (BP) and body temperature (BT) were recorded.

Results: $EtCO_2$ showed that there was no increase in CO_2 density inside of the SFFM, even decreasing. The correlation between RR and $EtCO_2$ might point out that SFFM provided comfortable breathing conditions in terms of vital signs. SpO_2, HR, BP, BT values were in the optimal value range for both measurements, and the subject did not report any discomfort or unusual feeling.

Conclusion: The SCUBA full-face mask system may be alternative personal protection equipment against virus transmissions during surgical interventions.

Key words: COVID-19, Full Face Mask, Personal Protection Equipment

1. Introduction

The virus called SARS-CoV-2 (severe acute respiratory syndrome coronavirus 2) causes COVID-19 (coronavirus disease 2019) pandemic, which is newly described as a major challenge for the world. The first case of "World War C" was reported on December 30, 2019, from Wuhan, China. The new type of coronavirus is ~%80 similar to SARS-CoV, which is in the Sarbecovirus subfamily (1).

The most common symptoms of COVID-19 are fever, cough, fatigue, and myalgia; besides, some patients have very mild or no symptoms. Air sharing environments such as hospital wards and operating rooms may be streamlined for the transmission of SARS-CoV-2. Inevitably, healthcare workers are in close contact with infected patients. The virus load is mostly in the lungs; therefore, dentists, ophthalmologists, otolaryngologists, and the other medical staff are under high-risk of COVID-19 due to respiratory droplets. Also, non-COVID-19 patients may be under risk, vice versa (2).

There are well-described barrier techniques for blocking the transmission of the viruses and bacterias. Personal protection equipment (PPE) such as FFP (Filtering Facepiece) masks and PAPR (Powered Air Personal Purifier) systems begun to use spreadly during the pandemic. However, the SARS-CoV-2 virus protection efficiency of PPEs is still being discussed. Some PPEs provide proper protection but limit comfort and visual ability. Also, PPE should be chosen depending on the planned treatment procedure in order to save resources (3). New published COVID-19 guidelines advise that all patients should be assumed to be infective, and the most effective barrier techniques must be used during treatment procedures for high risky healthcare workers. However, airborne transmission can not wholly be excluded (4) (5) (6) (7) (8).

Full-face masks can cover the mouth, nose, and eyes. Considering this situation, the full-face mask, which uses for scuba diving, might be an alternative option as PPE with supplying portable clean air. This study aims to introduce a SCUBA full-face mask system for COVID-19 protection and to test it in terms of comfortability.

2. Materials and Methods

2.1. Preface of Scuba Full Face Mask System

"Scuba" is an abbreviation of "self-contained underwater breathing apparatus". Scuba full-face mask (SFFM) system supplies positive pressure air with a tank connected to a regulator device. The system can be combined and separated into three main parts easily; mask, regulator, and tank.

The mask covers a large area of the face, which includes mouth, nose, and eyes. There is a circled shaped rubber seal that fits comfortably on the skin and provides required isolation for various face types against liquids and outside air. Different size options as small/medium/large are produced by manufacturers. Adjustable belts of the mask are fastened behind the head. The inside gap of the mask allows breathing normally through nose or mouth (Fig.1). The tank is filled with a 200 bar (can be up to 300 bar depends on tank type) of filtered atmosphere gas mixture (~%79 nitrogen, ~%21 oxygen) from the outdoor air which has filtered from humidity and particles (Fig.2). The regulator device firstly reduces 200 bar pressure to 8 – 10 bar, then transmits air into the mask by equalizing outside pressure. Airflow direction is one-way thanks to pressure difference from the tank to mask.

2.2. Protection Efficiency of the Scuba Full-Face Mask

The adaptation and tightness are critical features that mask have to be. Peripheral edges of the mask are made of rubber seals that cover the skin softly and hermetically. Hence, the mask can be adapted to various face types. If there would be an air leak on a zone of edge, positive pressure air might push aerosols coming from outside and resist the inflowing of contaminated air. On the other hand, a disposable mask must be covered onto the exhaust valve of the full-face mask to protect the patient from the dentist's exhalation (Fig.3).

2.3. Comfortability of the Scuba Full-Face Mask System

The visual angle of the surgeon is “sine qua non” for intervention. In this study, Neptune Space SFFM (Ocean Reef Inc., California, USA) was tested to evaluate one such design. According to the author, SFFM enabled satisfying vision during the intervention trial (Fig.4). Notably, the presence of continuous airflow in the mask prevented fogging. The weight of the SFFM is ~0.9 kilograms and did not occur a severe problem to the head and neck.

MK25 Evolution Deep Blue Regulator (Scuba Pro Johnson Outdoor Inc., Wisconsin, USA) was connected to SFFM with a 1,5-meter length hose. Thus natural head movements were not restrained (Fig.5). The author reported that breathing through the nose or mouth was comfortable, and it was able to communicate even using SFFM.

S Tech 11,1 liters aluminum scuba tank (**Sea Technologies Cylinders** Tüp San. ve Dış Ticaret Ltd.Şti., İstanbul, TURKEY) was filled up to 200 bar with filtered air via Junior II Air Compressor (**Bauer Comp Holding GmbH, Munich, Germany). Total air volume (was ~2220 liters) can be calculated with pressure multiply by tank volume.**

Disinfection of the SFFM system could be done by submerging into 1:10 sodium hypochlorite within 1-minute exposure then clean water (9)**. However, the total weight of the SFFM system including air was ~18.5 kilograms and was strenuous to carry by one person.**

2.4. Vital Signs Monitoring During SFFM System Usage

In this study; the author (oral surgeon) tested the SFFM system on himself by with or without using. He, also a scuba diving instructor and had experienced using the SFFM system, was thirty-four years old, non-smoker, and had no systematic disease. T**he author consumed air for 45 minutes duration at the trials and could follow the remaining air with a wireless gauge (Fig.6). E**nd-tidal carbon dioxide ($EtCO_2$ – mmHg), respiratory rate (RR – bpm), peripheral oxygen saturation (SpO_2 – %), heart rate (HR – bpm), blood pressure (BP – mmHg) and body temperature (BT – ^oC) were recorded per five minutes. Both trials were performed under similar conditions (Non-effort sitting position, same room, 1 atm pressure, 25^oC temperature) in order to an appropriate comparison could be obtained for a pilot study. No ethical permission was required due to the author personify as a volunteer.

A capnography probe was placed into the nostrils, and a pulse oximeter was put on the volunteer's right middle finger. A sphygmomanometer was wrapped around the left upper arm, and a thermal thermometer was held straight from the temporal artery with a 5 cm distance. Measurement devices had been calibrated before the experiment.

3. Results

Data were shown at Table-1 (without SFFM usage, control data) and Table-2 (with SFFM usage, experiment data) for between 0 – 45 minutes. The similarity of vital signs at the start time indicated that external factors were able to be maintained for convenient comparison.

When $EtCO_2$ was compared between Table-1 and Table-2, the values were less for SFFM usage. $EtCO_2$ showed that there was no increase in CO_2 density inside of the SFFM, even decreasing. Although RR showed variable results in both tables, values were less for SFFM usage like $EtCO_2$ values. The correlation between RR and $EtCO_2$ might point out that SFFM provided comfortable breathing conditions in terms of vital signs.

SpO_2 values were above 95%, showed stable oxygen saturation for both measurements, and no remarkable change was observed. HR, BP, BT values were in the optimal value range for both measurements, and the subject did not report any discomfort or unusual feeling during the experiment. Total air consumption was 45 atm for 45 minutes (Table-2).

4. Discussion

PPEs are gaining importance for healthcare services in the COVID-19 pandemic crisis. Proper covering of eyes-nose-mouth is the most fundamental rule against SARS-CoV-2 transmission. The most crucial point to be considered is the non-leakage covering of the face, so suitable SFFM size must be chosen. The constant test is performed to determine the right size (Place mask against the face, inhale a breath and hold. If mask sticks, it is a good fit).

In the literature, different types of PPE were categorized and advised according to the surgical intervention level (10). In the French guidelines, Lepelletier et al. (4) stated that FFP masks are very effective for surgical protection, and FFP3 filters at least 99% of aerosols. In addition, it is recommended to perform in negative pressure rooms when available for aerosol-generating procedures (11). In our study, the SFFM system offers breathing isolation in the operating room so that the protection level may become safer.

Carvalho et al. (12) suggested a full-face mask that is modified from a full-face snorkeling mask. The author attached an HME (Heat and Moisture Exchanger) virus filter to the top of the mask, and tested it in terms of comfortability by measuring $EtCO_2$. They stated that the modified full-face snorkeling mask was able to use as a PPE with attention to fit-testing on the face.

Erickson et al. (13) suggested a helmet modification for positive airflow for surgical interventions. Chen et al. (14) explained PAPR training for infection prevention during intubation performing.

The SFFM system is independent and portable; however, there are some challenges for regular use. The weight of the system could be reduced by replacing it with lighter components, especially tank. Carbon fiber cylinders can be connected instead of an aluminum cylinder; however, it supplies less air depending on the volume of the cylinder.

Visibility is partially limited due to the edges of the SFFM. The author removed some components to expand the view angle. The disinfection of the SFFM system is simple thanks to the waterproof and long-lasting features.

5. Conclusion

The SFFM system may be alternative protection against viral transmissions during surgical interventions. Further studies with multiple usages need to be performed for obtaining statistical results, and the SFFM system should be developed as more portable for regular use.

6. Acknowledgments

The author thanks Dr. Özyurt, Dr. Ceylan, Dr. Şenol, Dr. Kayaoğlu and Mr. Kulakaç.

7. References

1. Cevik M, Bamford C, Ho A. COVID-19 pandemic - A focused review for clinicians. Clin Microbiol Infect. 2020.

2. Baghizadeh Fini M. What dentists need to know about COVID-19. Oral Oncol. 2020;105:104741.

3. Al-Jabir A, Kerwan A, Nicola M, Alsafi Z, Khan M, Sohrabi C, et al. Impact of the Coronavirus (COVID-19) pandemic on surgical practice - Part 1 (Review Article). Int J Surg. 2020.

4. Lepelletier D, Grandbastien B, Romano-Bertrand S, Aho S, Chidiac C, Gehanno JF, et al. What face mask for what use in the context of COVID-19 pandemic? The French guidelines. J Hosp Infect. 2020.

5. Zimmermann M, Nkenke E. Approaches to the management of patients in oral and maxillofacial surgery during COVID-19 pandemic. J Craniomaxillofac Surg. 2020;48(5):521-6.

6. Al-Jabir A, Kerwan A, Nicola M, Alsafi Z, Khan M, Sohrabi C, et al. Impact of the coronavirus (COVID-19) pandemic on surgical practice - Part 2 (surgical prioritisation). Int J Surg. 2020.

7. Cheng VC, Wong SC, Chuang VW, So SY, Chen JH, Sridhar S, et al. The role of community-wide wearing of face mask for control of coronavirus disease 2019 (COVID-19) epidemic due to SARS-CoV-2. J Infect. 2020.

8. Eikenberry SE, Mancuso M, Iboi E, Phan T, Eikenberry K, Kuang Y, et al. To mask or not to mask: Modeling the potential for face mask use by the general public to curtail the COVID-19 pandemic. Infect Dis Model. 2020;5:293-308.

9. Rubio-Romero JC, del Carmen Pardo-Ferreira M, García JAT, Calero-Castro S. Disposable masks: Disinfection and sterilization for reuse, and non-certified manufacturing, in the face of shortages during the COVID-19 pandemic. Safety Science. 2020:104830.

10. Panesar K, Dodson T, Lynch J, Bryson-Cahn C, Chew L, Dillon J. Evolution of COVID-19 Guidelines for University of Washington Oral and Maxillofacial Surgery Patient Care. Journal of Oral and Maxillofacial Surgery. 2020.

11. Moletta L, Pierobon ES, Capovilla G, Costantini M, Salvador R, Merigliano S, et al. International Guidelines And Recommendations For Surgery During Covid-19 Pandemic: A Systematic Review. International Journal of Surgery. 2020.

12. Greig P, Carvalho C, El-Boghdadly K, Ramessur S. Safety testing improvised COVID-19 personal protective equipment based on a modified full-face snorkel mask. Anaesthesia. 2020.

13. Erickson MM, Richardson ES, Hernandez NM, Bobbert II DW, Gall K, Fearis P. Helmet Modification to PPE with 3D Printing During the COVID-19 Pandemic at Duke University Medical Center: A Novel Technique. The Journal of Arthroplasty. 2020.

14. Chen Q, Lim B, Ong S, Wong W-Y, Kong Y-C. Rapid ramp-up of powered air-purifying respirator (PAPR) training for infection prevention and control during the COVID-19 pandemic. BJA: British Journal of Anaesthesia. 2020.

8. Figures

Figure 1: SFFM system allows breathing normally

Figure 2. Tank filling via using air-compressor

Figure 3. The disposable mask covering onto exhaust valve

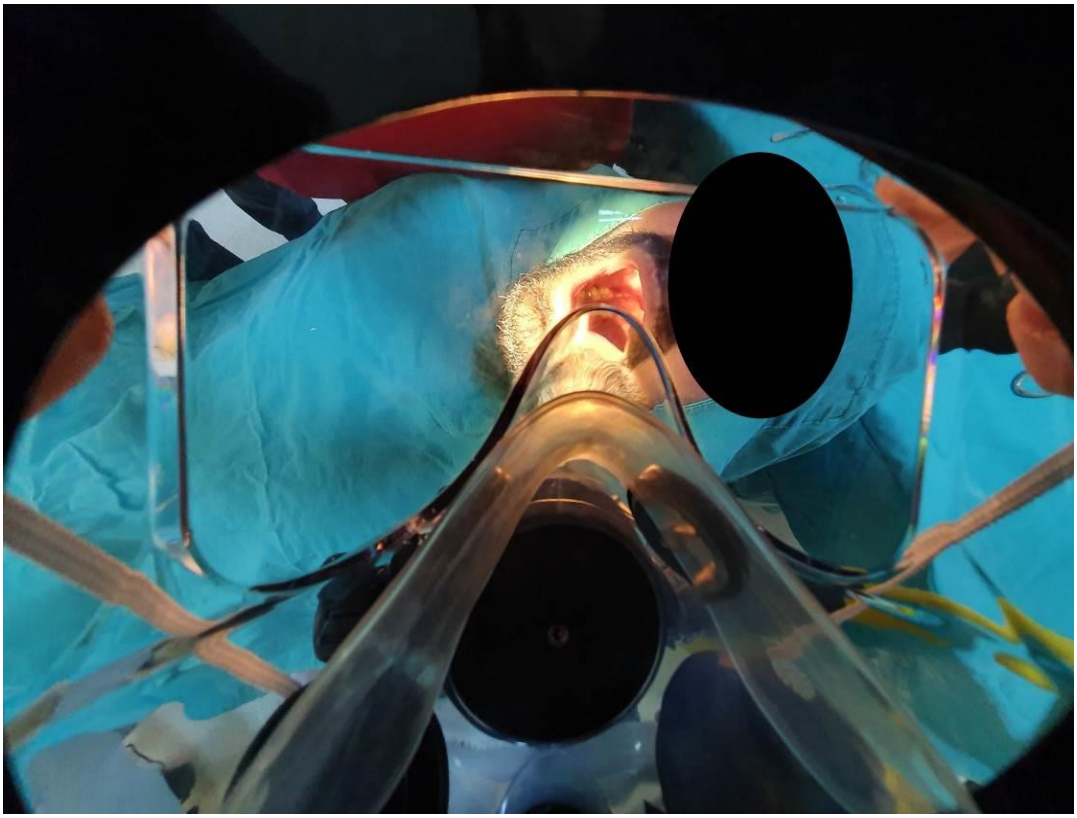

Figure 4. View angle inside from the mask

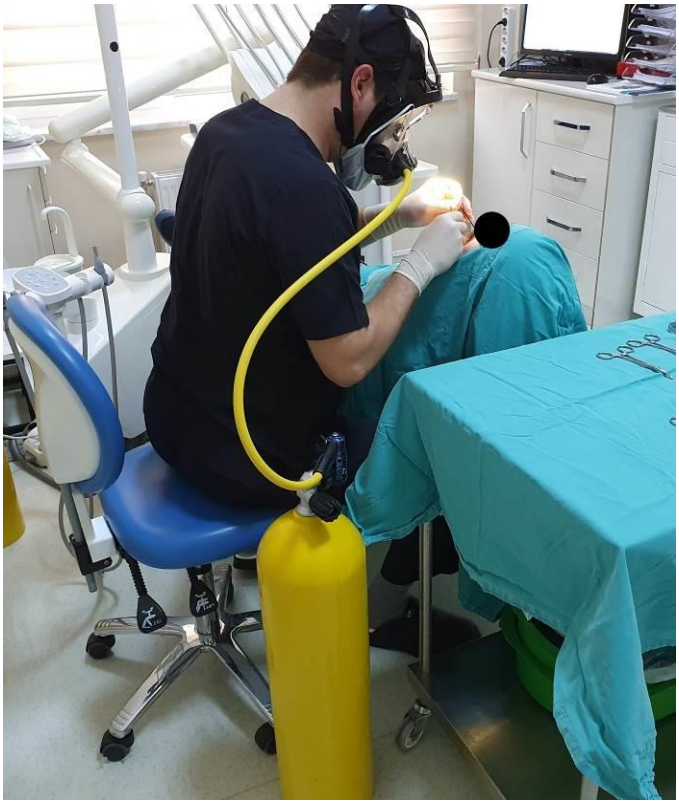

Figure 5. Hose length allows head and neck movements

Figure 6. Wireless transmitter system shows remaining air supply

9. Tables

Table 1: Data from without SFFM usage

Without SFFM	0. minute	5. minute	10. minute	15. minute	20. minute	25. minute	30. minute	35. minute	40. minute	45. minute
$EtCO_2$ (mmHg)	34	35	35	35	35	35	34	34	34	34
RR (bpm)	16	15	18	14	16	18	18	15	15	16
SpO_2 (%)	96	98	99	97	98	99	97	97	98	97
HR (bpm)	80	75	73	79	78	71	76	76	75	76
BP (mmHg)	125/80	130/80	133/87	128/84	119/79	127/91	124/87	127/88	120/82	126/88
BT (^oC)	35,6	35,3	35,4	35,9	36,0	35,6	35,5	36,0	35,8	36,0

Table 2: Data from with SFFM usage

With SFFM	0. minute	5. minute	10. minute	15. minute	20. minute	25. minute	30. minute	35. minute	40. minute	45. minute
$EtCO_2$ (mmHg)	34	30	28	30	32	31	32	31	32	31
RR (bpm)	15	13	11	12	11	13	12	10	12	13
SpO_2 (%)	98	97	99	99	99	99	97	99	98	99
HR (bpm)	80	75	75	77	80	72	76	75	75	76
BP (mmHg)	122/79	118/83	129/89	130/91	119/79	109/98	134/81	109/83	122/78	126/84
BT (^oC)	35,6	35,1	36,0	35,3	35,7	35,8	35,5	35,0	35,8	36,0
Tank Air Pressure (atm)	200	195	189	182	178	175	171	166	159	155

OP- 11

IMMEDIATE IMPLANT PLACEMENT WITH AUTOGENOUS BLOCK GRAFT INTO INFECTED SOCKET: A CASE REPORT

Mustafa YALÇIN [a]

[a] Gaziantep University, Faculty of Dentistry, Department of Oral and Maxillofacial Surgery, Turkey, mustafayalcin.omfs@gmail.com

Abstract

Objectives: There are various treatment protocols and surgical techniques for implant placement in the fresh extraction socket. The defect type of the post-extraction socket, presence of the infection, quality and quantity of the soft tissue are determinant factors for the timing of the implant placement.

Case report: A young female patient was admitted to our clinic with a persistent primary molar and second premolar deficiency in the left mandible. The persistent primary molar was extracted and curettage, irrigation of the socket with sterile saline was performed to remove the odontogenic infection. ramus block graft (about 15x10 mm) was harvested according to the template of the socket. Extraorally, bone graft was drilled and Ankylos implant (Dentsply Ankylos, Mannheim, Germany) which was 3.5 mm diameter and 9.5 mm length, placed in bone graft subcrestally. Two periapical radiographs were taken at the 1st and 3rd month. At the end of the 3rd month, the mucoperiosteal flap was reflected, no bone resorption was detected and the implant healing cap was placed prior to the prosthetic superstructure.

Conclusion: Autogenous block graft can be used safely for immediate implant placement where primary stability cannot be achieved in the infected post-extraction socket.

Key words: Block graft, infected socket, immediate implant placement

1. Introduction

Many factors affect the decision of the implant placement after extraction of teeth (1). The patient expectation in the esthetic region, quantity, and quality of the bone and soft tissue, odontogenic infection, and primary stability determine the time of the implant placement. Four treatment options after extraction of teeth were defined by the ITI in ITI Consensus Conference(2008): i) immediate implant placement (on the same day), ii) early implant placement (within 4-8 weeks, with soft tissue healing), iii) early implant placement (within 12-16 weeks, with partial bone healing), iv) late implant placement (> 6 months, complete bone healing). According to the ITI consensus, soft and partial or complete bone tissue healing was admitted as a reference for implant placement for post-extraction (2). Post-extraction socket with well preserved soft tissue and dentoalveolar bone might be treated with immediate implant placement (3).

Quality and quantity of the dentoalveolar bone, the integrity of the soft tissue before immediate implant placement is determinant factors for primary stability due to provide the optimal position of the endosteal implant, osteointegration and wound healing in the post-extraction socket. Especially trauma, traumatic extraction, periodontal and/or endodontic infection might lead to excessive bone destruction of the dentoalveolar bone. Extraction defect sounding classification(EDS) is crucial for obtaining treatment guidelines, achieving predictable osteointegration and esthetics before implant placement (4). For a general assessment of the post-extraction socket, several factors are evaluated to decide treatment protocols which are; i) number of the affected socket walls, ii) periodontal biotype (thin or thick), iii) crestal or interproximal bone loss, iv) post-extraction buccal/palatal/lingual plate thickness (4). We aimed to present a case report including immediate implant placement concerning odontogenic infection with intraoral autogenous bone graft.

2. Case report

A young female patient was admitted to our clinic with a persistent primary molar and second premolar deficiency in the left mandible. In the radiological examination, lack of the second premolar, odontogenic infection associated with a persistent primary molar and widespread bone destruction in the periapical region were detected (Figure 1). In the intraoral examination, there was no bleeding, pocket in the probing, fistula, marginal or interproximal papilla recessions, fenestration or dehiscence, cortical bone expansion (Figure 2).

As a treatment protocol, extraction of the primary molar and then implant placement was planned for prosthetic rehabilitation. The persistent primary molar was extracted and curettage, irrigation of the socket with sterile saline was performed to remove the odontogenic infection (Figure 3). Buccal (except 1-2 mm mesiobuccal bone resorption) and a lingual cortical plate of the socket was considerably preserved and thickness of the buccal and lingual plate was approximately 1.5 mm (Figure 3). The interseptal bone between mesial and distal roots was destructed. Two treatment protocols were considered: i) socket preservation with bone graft and membrane, ii) immediate implant placement with autogenous bone graft. Immediate implant placement was planned but there was no sufficient bone to ensure primary stability of the implant in the socket. To ensure primary stability, ramus block graft (about 15x10 mm) was harvested according to the template of the socket (Figure 4). Extraorally, bone graft was drilled and Ankylos implant (Dentsply Ankylos, Mannheim, Germany) which was 3.5 mm diameter and 9.5 mm length, placed in bone graft subcrestally (Figure 5). Then, the graft and implant were placed together in the socket and adapted. Primary stability was only between the coronal part of the implant and block graft (Figure 6). There was no primary stability in the middle and apical part of the implant. The block graft also contributed to osteointegration as a guided bone regeneration material. A mucoperiosteal flap was closed primarily and the patient was followed-up. Two periapical radiographs were taken at the 1st and 3rd month (Figure 7). At the end of the 3rd month, the mucoperiosteal flap was reflected, no bone resorption was detected and the implant healing cap was placed prior to the prosthetic superstructure (Figure 8).

3. Discussion

Treatment options for the post-extraction socket might be subdivided into three options. Conventionally, the socket is allowed to heal naturally and implant placement can be performed six months later if there is no need for any augmentation (5). Another option is the preservation of the post-extraction socket with graft, membrane or connective tissue and then an implant is placed with a second surgery (6). The third option is immediate implant placement but sufficient alveolar bone and periodontal tissue are necessary for long-term and predictable success (7). Graft materials, membranes, and connective tissue may be used to ensure optimal osseointegration, soft and hard tissue healing in immediate implant placement protocols. Also, sufficient bone in the fresh post-extracted socket is required in order to attain primary stability. If there is no sufficient bone in the socket, the implant is generally placed after the healing process (8).

Giesenhagen et al. reported that a single-tooth bone defect with buccal and lingual wall resorption was reconstructed using cylindrical freeze-dried bone allograft and simultaneous implantation and attain vertical bone augmentation (8). In our case, the allogenic bone ring was not proper due to the extended rectangular-shaped post-extraction socket and lack of supporting bone for primary stability. For this reason, we used a rectangular-shaped autogenous block graft to obtain primary stability and/or act as guided bone regeneration.

Odontogenic infection is one of the reasons for the tooth-extraction and ongoing infection may be a contraindication for immediate implant placement as the infection might affect the healing process and osteointegration (9-12). Zufetti et al. conducted a multicenter retrospective clinical study including post-extraction implant placement into infected versus non-infected sites and reported that endodontically or periodontally infected sockets for implant placement was reliable and did not affect significantly the implant survival rate (13).

4. Conclusion

Autogenous block graft can be used safely for immediate implant placement where primary stability cannot be achieved in the infected post-extraction socket. Block graft can act as guided bone regeneration. Atraumatic tooth extraction and preservation of the alveolar bone surrounding the socket is vital for immediate implant placement.

5. References

1. Bhola M, Neely AL, Kolhatkar S. Immediate implant placement: clinical decisions, advantages, and disadvantages. J Prosthodont. 2008;17(7):576-81. doi: 10.1111/j.1532-849X.2008.00359.x.

2. Chen ST, Buser D. ITI Treatment Guide Vol 3: Implants in extraction sockets. In: Buser D, Belser U, Wismeijer D, eds. Implants in post-extraction sites: a literature update. Berlin: Quintessence Publishing Co, Ltd; 2008. p. 9-16.
3. Chen ST, Wilson TG, et al, Immediate or early placement of implants following tooth extraction: review of biologic basis, clinical procedures, and outcomes. Int J Oral Maxillofac Implants 2004;19:12-25.
4. Caplanis N, Lozada JL, Kan JY. Extraction defect assessment, classification, and management. J Calif Dent Assoc. 2005;33(11):853-63.
5. Jovanovic SA, Spiekermann H, Richter EJ. Bone regeneration around titanium dental implants in dehisced defect sites: a clinical study. Int J Oral Maxillofac Implants. 1992;7(2):233-45.
6. Sclar AG. Strategies for management of single-tooth extraction sites in aesthetic implant therapy. J Oral Maxillofac Surg. 2004;62(9 Suppl 2):90-105.
7. Becker W. Immediate implant placement: diagnosis, treatment planning and treatment steps/or successful outcomes. J Calif Dent Assoc. 2005;33(4):303-10.
8. Giesenhagen B, Martin N, Donkiewicz P, Perić Kačarević Ž, Smeets R, Jung O, Schnettler R, Barbeck M. Vertical bone augmentation in a single-tooth gap with an allogenic bone ring: Clinical considerations. J Esthet Restor Dent. 2018;30(6):480-483. doi: 10.1111/jerd.12392.
9. Schwartz-Arad D, Chaushu G. The ways and wherefores of immediate placement of implants into fresh extraction sites: a literature review. J Periodontol. 1997;68:915–923.
10. Casap N, Zeltser C, Wexler A, Tarazi E, Zeltser R. Immediate placement of dental implants into debrided infected dentoalveolar sockets. J Oral Maxillofac Surg. 2007;65:384–392.
11. Quirynen M, Gijbels F, Jacobs R. An infected jawbone site compromising successful osseointegration. Periodontol 2000. 2003;33:129–144.

12. Rosenquist B, Grenthe B. Immediate placement of implants into extraction sockets: implant survival. Int J Oral Maxillofac Implants. 1996;11:205–209.
13. Zuffetti F, Capelli M, Galli F, Del Fabbro M, Testori T. Post-extraction implant placement into infected versus non-infected sites: A multicenter retrospective clinical study. Clin Implant Dent

Relat Res. 2017;19(5):833-840. doi: 10.1111/cid.12523.

6. Figures

Figure 1: Odontogenic infection related to left mandibular primary molar in orthopantogram

Figure 2: Preoperative intraoral view of the left mandible

Figure 3: Intraoral view of the post-extraction socket

Figure 4: Intraoral view of the mandibular ramus block graft

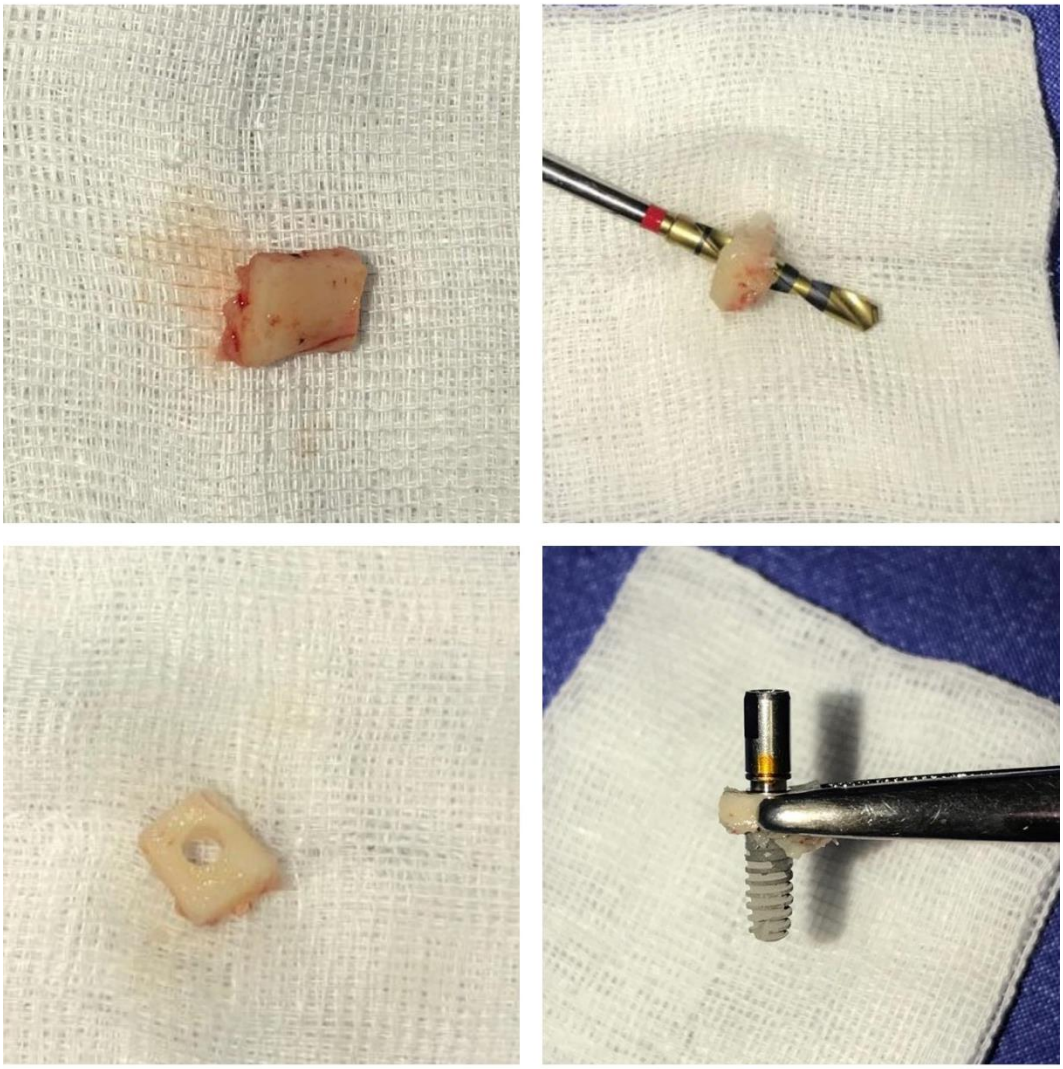

Figure 5: Extraorally, drilling the bone graft and placement of the implant

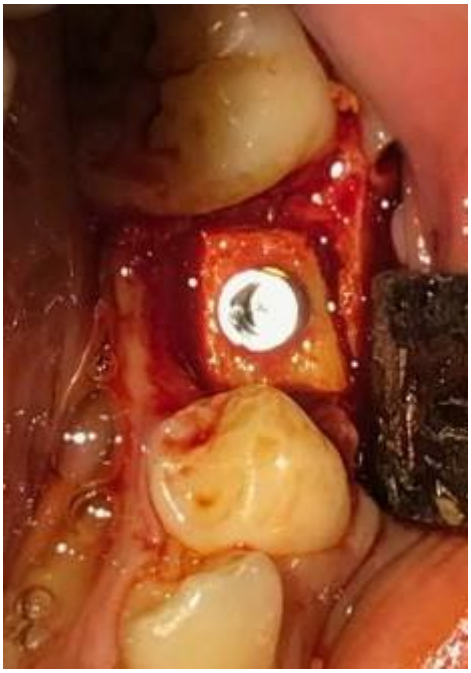

Figure 6: Placement and adaptation of the block graft with the implant

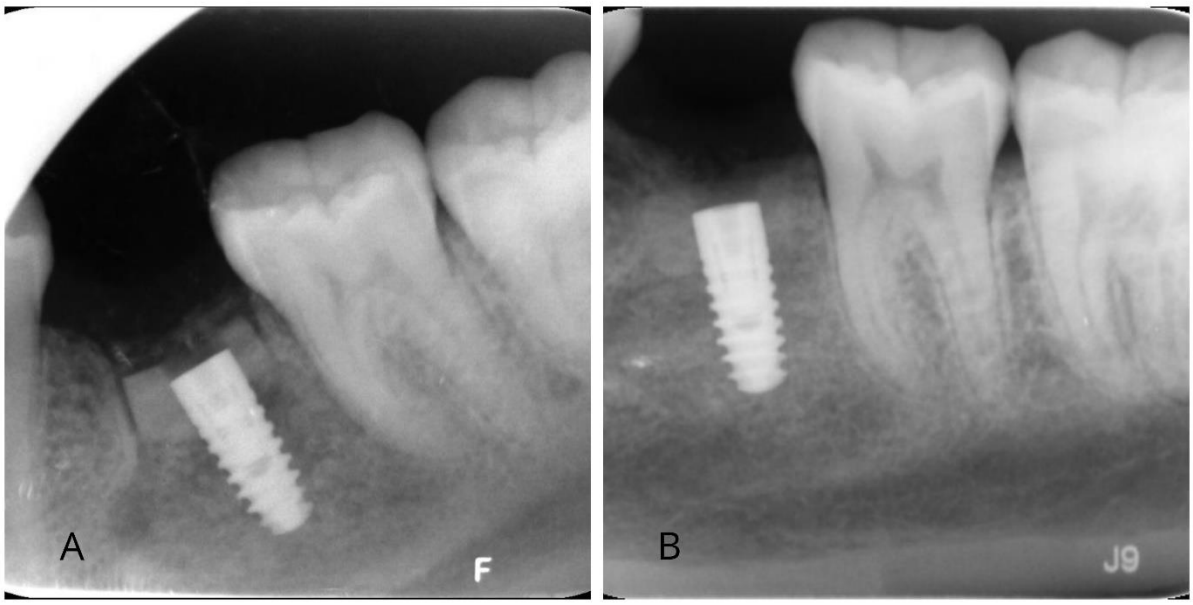

Figure 7: Postoperative periapical radiograph at 1st month (A) and 3rd month (B)

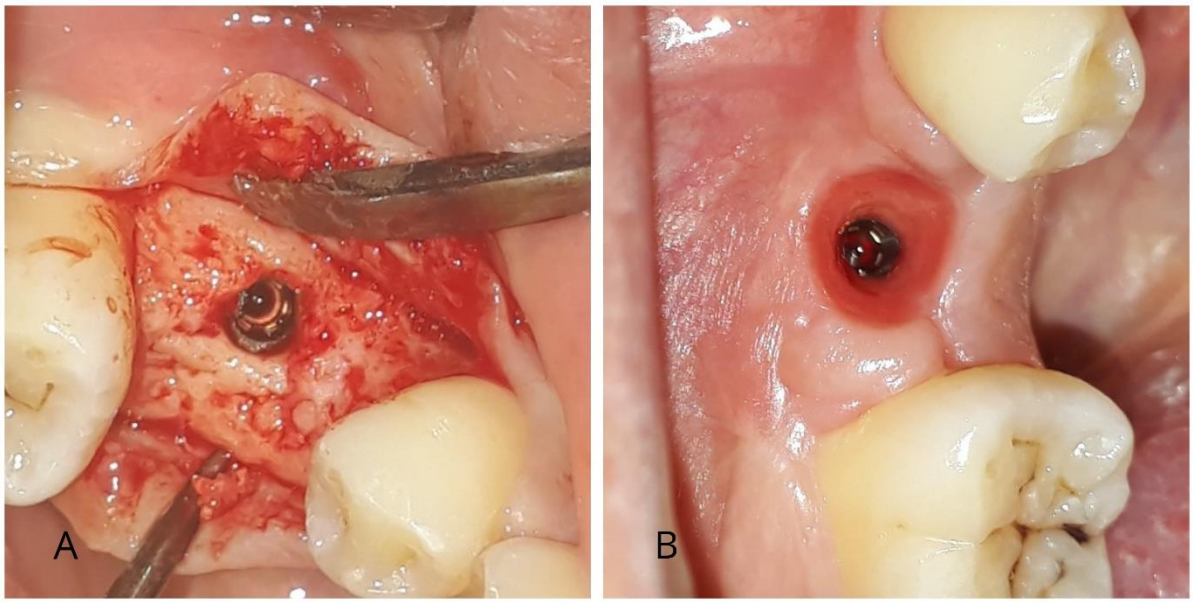

Figure 8: (A) Introral view after the mucoperiosteal flap was reflected at the end of the 3rd month, (B) Healing cap was removed prior to the prosthetic superstructure

OP-14

Oral Bifosfonat Kullanım Öyküsü Nedeniyle İleri Augmentasyon Cerrahileri Uygulanamayan Şiddetli Atrofik Mandibulanın Konvansiyonel Kısa ve Dar Çaplı İmplantlarla Rehabilitasyonu

Mehmet Emin Toprak*, Serdar Polat**, Aykut Gönder**

*Gazi Üniversitesi Diş Hekimliği Fakültesi Ağız, Diş ve Çene Cerrahisi Anabilim Dalı

** Gazi Üniversitesi Diş Hekimliği Fakültesi Protetik Diş Tedavisi Anabilim Dalı

ÖZET

Giriş: Dental implant uygulamaları kontrol altında sistemik rahatsızlığı olan bireylerde güvenle kullanılabilmektedir. Kemik metabolizmasını direkt olarak etkileyen ve uzun yarılanma ömürleri olan bifosfonat türevlerinin intravenöz kullanımı implant uygulamaları için kesin kontrendikasyon oluştururken, oral kullanımda gerekli şartları taşıyan hastalara kemik içi implant uygulamaları yapılabilmektedir. Aşırı kemik atrofisi görülen hastalarda, doğal bir estetik oluşturmak ve kaybedilen bütün dokuları ileri augmentasyon cerrahileri ile rehabilite etmek mümkündür. Ancak kemik metabolizmasını etkileyen ilaç kullanımı olan hastalarda bu cerrahilerin yaratabileceği komplikasyonlar düşünülerek tedavi planlaması yapılmalıdır.

Olgu: 68 yaşındaki kadın hasta kliniğimize uzun süredir kullandığı total protezinin çiğneme ve konuşma fonksiyonlarını yerine getirememesi şikayetiyle başvurmuştur. Yapılan radyolojik incelemelerde spontan kırık oluşabilecek kadar şiddetli atrofik mandibuler kemik tespit edilmiştir. Standart implant cerrahileri öncesinde augmentasyon cerrahileri düşünülen hastanın osteoporöz nedeniyle en son 5 yıl önce ve 2 yıl boyunca oral bifosfonat kullandığı (Fosamax) tespit edilmiştir. Rezorpsiyonun şiddetinden dolayı yeni bir total protezden veya otojen greftlemelerden istenilen düzeyde fayda göremeyecek olan hastanın mandibula anteriordaki 10mm'lik rezidüel bazal kemiğine 3 adet 3.5mm çapında 8mm boyunda kısa kemik içi implant (Medentika Microcone GmbH, Hügelsheim, Almanya) yerleştirildi. Kırılma riskini azaltmak için implantlar en düşük primer stabilite ile gönderildi. Protetik aşamada implantlar bar tutucularla splintlendi ve çiğneme kuvvetleri dağıtıldı. 2 yıllık takiplerde herhangi bir kemik nekrozu ve implantlarda rezorpsiyon olmadığı görüldü.

Sonuç: Sabit protez kullanımına engel olacak derecede atrofi görülen çenelerde, ileri cerrahi teknikler uygulanamıyorsa implant destekli overdenture protezler alternatif bir tedavi seçeneği olarak düşünülmelidir.

Anahtar kelimeler: MRONJ, kısa implant, barlı protez, alternatif tedavi

Rehabilitation of Severe Atrophic Mandible with Conventional Short and Narrow Diameter Implants as an Alternative to Advanced Augmentation Surgeries Due to Oral Bisphosphonate Usage

Mehmet Emin Toprak*, Serdar Polat**, Aykut Gönder**

*Gazi University Faculty of Dentsitry Department of Oral and Maxillofacial Surgery

** Gazi University Faculty of Dentsitry Department of Prosthodontics

ABSTRACT

Introduction: Dental implant operations can be used safely in patients with controlled systemic disorders. While intravenous usege of bisphosphonate derivatives, which directly affect bone metabolism, is a definite contraindication for endosseous implant surgeries, implants can be applied to patients with the necessary conditions in oral usege. In patients with severe bone atrophy, it is possible to create a natural aesthetic and rehabilitate all tissues with advanced augmentation surgeries. However, treatment planning should be made by considering the complications of these surgeries in patients with drug use affecting bone metabolism.
Case report: A 68-year-old female patient was admitted to our clinic with the complaint of total prosthesis that she had been using for a long time and couldn't perform the chewing and speech functions. In the radiological examinations, severe atrophic mandible was detected, even if the spontaneous fracture is possible. The routine augmentation surgeries were considered prior to standard implants, but it was determined that the patient had used oral bisphosphonates due to osteoporosis for 2 years (Fosamax) 5 years ago. Due to the severity of resorption, 3 3.5mm in diameter and 8mm length short endosseous implants (Medentika Microcone GmbH, Hügelsheim, Germany) were placed in the 10mm residual basal bone of the patient, who would not benefit from a new total prosthesis or autogenous grafts. To reduce the risk of jaw break, implants were placed with the lowest primary stability. In the prosthetic stages, implants were splinted with bar holders and chewing forces were distributed. During 2-year follow-up, there was no bone necrosis and no resorption.

Conclusion: Implant-supported overdenture prostheses should be considered as an alternative treatment option if advanced surgical techniques cann't be applied in the jaw with severe atrophy that prevents the use of fixed dentures.

Keywords: MRONJ, short implant, bar retained prosthesis, alternative treatment

GİRİŞ

Modern diş hekimliğinin amacı hastanın oral bölgesinde normal konturları, fonksiyonu, rahatlığı, konuşmayı, estetiği ve ağız sağlığını yeniden sağlamaktır. Ancak kaybedilen diş sayısı arttıkça başarıya ulaşmak o oranda zor olmaktadır. Günümüzde sürdürülen araştırmaların sonuçları, diagnostik aletler, tedavi planlaması, implant dizaynı, materyali ve yapım teknikleri sayesinde çok sayıda tedavisi güç vakanın rehabilitasyonunun başarı ile gerçekleştiğini göstermektedir (1).
İmplant üstü bir protez, kullanılan implant sayısına göre sabit ya da hareketli olacak şekilde planlanabilir. Buna göre implant üstü hareketli protezler, implant tutuculu overdenture veya implant destekli overdenture olarak sınıflandırılabilir.
Overdenturelarda implant ile protez arasındaki hassas bağlantı, tek (stud) tutucular veya bar tutucular ile iki farklı şekilde sağlanabilir (2). Barlar rutin olarak, maksiller overdenture'larda, atrofik residuel kretli mandibulada ve belirgin kret konturuna bağlı olarak ikiden fazla implantın yerlestirildiği mandibular overdenture'larda, tutuculuk ve stabilite ihtiyacının fazla olduğu vakalarda tavsiye edilir. İntraoral defektler varsa, yaralanabilir yumuşak dokulardaki yükü azaltmak amacıyla rijit barlar tercih edilir İnterokluzal mesafenin yetersiz olduğu, rezorpsiyona uğramamış kretlerin varlığında, hastanın ekonomik durumunun yetersiz olduğu (fazla sayıda implant gerekliliği), ağız hijyeninin iyi sağlanamayacağı düşünülen vakalarda tercih edilmemelidir. Ayrıca, hekim ve teknisyenin bilgi, beceri ve tecrübesi, protetik restorasyonun tipine karar verilirken dikkat edilmesi gereken hususlardan biridir (2,3).

Amerikan Oral ve Maksillofasiyal Cerrahi Derneği (AAOMS), daha önce baş ve boyun bölgesinden radyoterapi almamış, geçmişte bisfosfonat kullanmış ya da kullanmakta olan hastalarda çene kemiklerinde sekiz haftadan uzun süren kemik ekspozunu 'bisfosfonata bağlı çene kemiği osteonekrozu (BRONJ)'olarak tanımlamıştır. Bifosfanatların yanı sıra diğer antirezorptif ve antianjiojenik ilaçların da çenelerde osteonekroza sebep olduğu gösterilmiştir. Bu nedenle 2014 yılında, AAOMS BRONJ terminolojisinin 'ilaçlara bağlı çene kemiği osteonekrozu (MRONJ)' olarak değiştirilmesinin daha doğru olduğunu bildirmiştir (4).

Bisfosfonat grubu ilaçların intravenöz yolla alınması, oral yoldan alınmasına kıyasla osteonekroz gelişme riskini yaklaşık 80 kat arttırmaktadır. İntravenöz yolla bifosfonat tedavisi gören hastalarda 1 yıl sonunda osteonekroz gelişme riski %1 iken, 4 yılın sonunda bu oranın %13'e çıkmaktadır. Literatürler zoledronik asit kullanımında 12-24 ay, pamidronat kullanımında 19- 30 ay, ibandronatta 13-21,5 ay arasında çene kemiklerinde osteonekroz gelişebildiğini bildirmektedir (4,5).

Oral bifosfonat kullanan hastalarda MRONJ gelişme riskini belirlemede en önemli tanı araçlarından biri C-terminal cross-linked telopeptide (CTx) değerleridir. CTx değeri ile tip 1 kollajenin karşı zincirindeki C-terminal telopeptidin serumdaki seviyesi ölçülmektedir (6,7)

Osteoklastik aktivitenin güvenilir bir belirteci olan serum CTx seviyesi kemik turnoverı ve rezorpsiyonunu değerlendirmede kullanılır. Serum CTx seviyesi oral bifosfanat kullanımında kemik yıkımı ve yeni yapılan kemik miktarının değerlendirilmesinde faydalıdır ve 150 pg/ml üzerindeki değerler güvenli olarak kabul edilmektedir (7,8).

Bu vaka sunumunda atrofik mandibuler kemik yapısına sahip, yaşı ve bifoasfanat kullanımı nedeniyle ileri cerrahi işlemler yapılamayacak, tam dişsiz hastanın 3 kısa implant üzerine bar tutucu ile yapılan overdenture uygulaması anlatılmıştır.

VAKA RAPORU

68 yaşındaki kadın hasta kliniğimize uzun süredir kullandığı total protezinin çiğneme ve konuşma fonksiyonlarını yerine getirememesi şikayetiyle başvurmuştur. Yapılan radyolojik incelemelerde spontan kırık oluşabilecek kadar şiddetli atrofik mandibuler kemik tespit edilmiştir. Mandibula anteriorda bile rezidüel kemik boyu 10 mm olarak ölçülmüştür. Standart implant cerrahileri öncesinde augmentasyon cerrahileri düşünülen hastanın osteoporöz nedeniyle en son 5 yıl önce 2 yıl boyunca oral bifosfonat kullandığı (Fosamax) tespit edilmiştir. Hastanın CTx laboratuvar testi sonucu 210 pg/ml olarak gelmiştir. Rezorpsiyonun şiddetinden dolayı yeni bir total protezden veya otojen greftlemelerden istenilen düzeyde fayda göremeyecek olan hastanın mandibula anteriordaki 10mm'lik rezidüel bazal kemiğine 3 adet 3.5mm çapında 8mm boyunda kısa kemik içi implant (Medentika Microcone GmbH, Hügelsheim, Almanya) yerleştirildi (Resim 1). Kırılma riskini azaltmak için implantlar en düşük primer stabilite ile gönderildi.

Resim 1. Preoperatif panoramik film

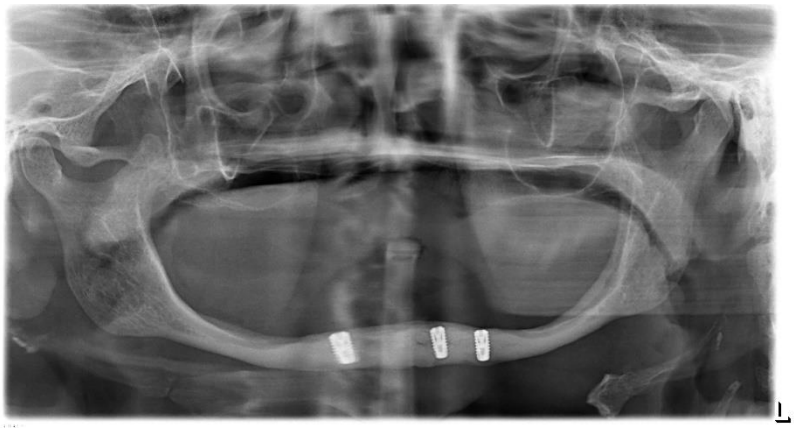

Resim 2. Postoperatif panoramik film

Osseointegrasyon için 10 hafta beklendi (Resim 2). Bu periyodun sonunda 5 mm yüksekliğinde standart iyileşme başlıkları takılarak aynı seansta vestibüler sulkusu derinleştirmek ve yapışık dişeti miktarını arttırmak için palatinal bölgeden serbest yapışık dişeti grefti alınarak implantların bukkaline yumuşak doku operasyonu yapıldı. 14 gün beklenilmesinin ardından protetik restorasyonun yapım aşamalarına başlandı.

İyileşme başlıkları çıkarılarak bunların yerine her implant için dişeti seviyesine uygun ve bar tutucuların yapımında kullanılacak multiunit abutmentler seçildi. Kemik yapı ve üretici firmanın önerileri doğrultusunda 30 N/cm tork kuvveti ile implantlara torklandı. Fabrikasyon ölçü kaşığı ve aljinatla alınan ilk ölçülerden modeller elde edildi ve bu modeller üzerinde açık kaşık tekniğiyle ölçü almak için akrilik kaşıklar hazırlandı. Multiunit abutmentlara transfer parçaları yerleştirildi, elastomerik ölçü maddesi kullanılarak ölçüler elde edildi. Ölçü içerisine implantların gingival seviye için yumuşak polimer sıkıldı ve kalan kısım için tip IV sert alçı dökülerek model hazırlandı. Üst model ile beraber alt model üzerinde ışık ile polimerize olan akrilikten geçici kaide plakları hazırlandı ve çeneler arası vertikal ve horizontal ilişki kayıtları alındı.

Model üzerinde multiunit analoglara uygun dökülebilir plastik kepler seçildi, ark konumuna uygun bar parçalar keplere birleştirilerek modelasyonları yapıldı. Selektif lazer sinterleme yöntemi ile bar tutucular hazırlandı (Resim 3).

Resim 3. Bar tutucular

Elde edilen barın ağız içinde uyumu ve pasifliği değerlendirildi, sonrasında overdenture yapı için bar üzerinde iskelet metal dökümü yapıldı ve bu metal alt yapılar ağız içerisinde kontrol edildi ve diş dizimi aşmasına geçildi. Diş diziminin klinik provası yapıldı. Sentrik ilişki, eksentrik hareketler değerlendirildikten sonra estetik ve fonasyon değerlendirmeleri, yumuşak doku konturlarının desteklenmesi değerlendirildi. Düzeltmelerden sonra protezlerin akrilik bitimleri gerçekleştirildi. Bitim aşamasında bar yapı multiunitler üzerine torklandı, protezlerde aşındırma işlemleri yapıldı ve hastaya protezlerle ilgili hijyen anlatılarak protez teslim edildi (Resim 4) ve rutin kontrollere başlandı, 2 yılın sonunda osteonekroz bulgusu veya implantlarda herhangi bir sorunla karşılaşılmadı (Resim 5).

Resim 4. Barlı protezin bitim hali

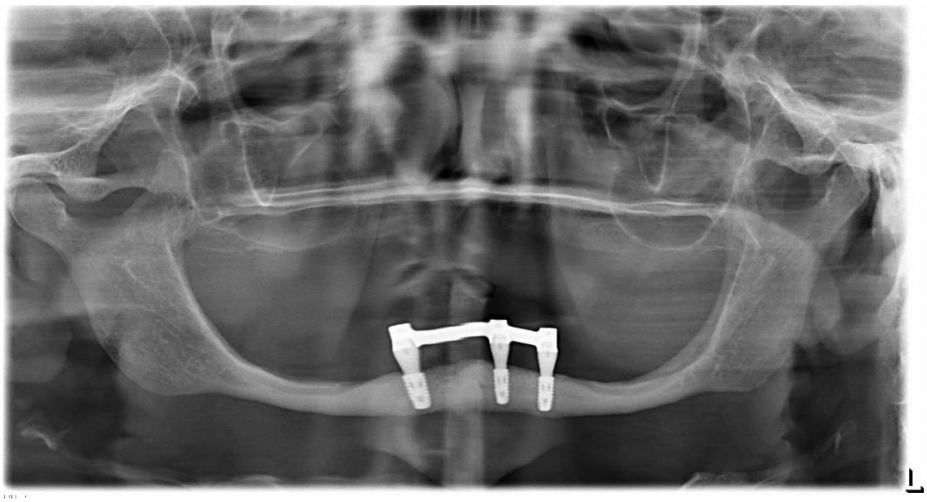

Resim 5. Bar tutuculu protezin 2 yıl sonraki kontrol filmi

TARTIŞMA

İmplant üstü protezlerin yapımı ile tam protez hastalarının yaşam konforu ve protezden memnuniyetleri çarpıcı şekilde artmaktadır. İmplant üstü protezlerin planlaması yapılırken, implant sayısı, implantların yerleri ve yapılacak protezin türüne karar verirken; vakanın uygunluğu, rezidüel kemik yapısı, karşılıklı çene ilişkileri, ekonomi ve hastanın istekleri önüne alınmalıdır. İnce, keskin ve aşırı rezorbe kretler, implant tedavisi öncesi uygun greftlemeyle augmentasyon gibi cerrahi operasyonlar gerektirebilir (2)

Bar tutuculu sistemler alt çenede ileri derecede rezorpsiyon varlığında, üst çene protezlerinde, oval kretlerde, çenelerde parsiyel rezeksiyon yapılan vakalarda, tutuculuğun ve stabilitenin fazla olmasının istendiği protezlerde endikedir. İnteroklüzal mesafe yetersiz ise, hastanın ekonomik durumu uygun değilse, hastanın oral hijyeni yeterince sağlayamayacağı düşünülen vakalarda kontrendikedir. Tutuculuk ve stabiliteyi olumlu yönde etkilemeleri avantaj olarak kabul edilirken, ekonomik olmaması ve yapım aşamalarının karmaşık olması dezavantajlarıdır (1).

MRONJ epidemiyolojisi ve patolojisi konusundaki bilgiler ve protokoller tam olarak açıklanamamıştır ve sürekli güncellenmektedir. Detaylı anamnez ve ayrıntılı bir medical muayene osteonekroz oluşma riskinin önüne geçmeyi kolaylaştırır. Bu nedenle diş hekimlerinin MRONJ hastası adayı bireylerde implant uygulamaları ile ilgili yeterli bilgiye sahip olması oldukça önemlidir. Hastaların olası riskler konusunda bilinçlendirilmesi ve diş hekimleri ile ilacı uygulayacak tıp hekiminin koordinasyonu MRONJ gelişim riskinin azaltılması konusunda önem taşımaktadır (9,10).

SONUÇ

Bu vakada implantlar kemiğin elverdiği en uygun yerlere ölçüde yerleştirilmiştir, 2 implantla yapılan overdenture uygulamalarında oluşan rotasyon hareketini önlediği için 3 implant yapmak son derece kritiktir. Bar tutucu yapımıyla implantlar splintlenerek kuvvet dağılımı sağlanmış, stabilize artmış, implant açılanmasına bağlı stud tutuculardaki görülen matris aşınma riski ortadan kaldırılmıştır.

KAYNAKLAR

1. Misch CE. Mandibular implant overdentures design and fabrication. İçinde: Misch CE, editör. Dental Implant Prosthetics. Mosby, St. Louis, 2005, 228-251.
2. Meijer HJ, Raghoebar GM, Van 't Hof MA. Comparison of implant-retained mandibular overdentures and conventional complete den- tures: a 10-year prospective study of clinical aspects and patient satisfaction. Int J Oral Maxillofac implants 2003; 18: 879-85.
3. Zarb G.A., Merıcske-Stern R. Clinical Protocol for Treatment with Implant-Supported Overdentures Implant Prosthodontic. In: Prosthodontic treatment for edentulous patients: Complete dentures and implant-supported prostheses, Ed.: C.L Bolender, G.A. Zarb. Twelfth ed. St.Louis 2004. Mosby,chapter 27.
4. *Schiodt M, Vadhan-Raj S, Chambers MS, Nicolatou-Galitis O, Politis C, Coropciuc R, Fedele S, Jandial D, Zhang J, Ma H, Saunders DP. A multicenter case registry study on medication-related osteonecrosis of the jaw in patients with advanced cancer. Support Care Cancer. 2018 Jun;26(6):1905-1915.*

5. *Dimopoulos MA, Kastritis E, Anagnostopoulos A, Melakopoulos I, Gika D, Moulopoulos LA, Bamia C, Terpos E, Tsionos K, Bamias A. Osteonecrosis of the jaw in patients with multiple myeloma treated with bisphosphonates: evidence of increased risk after treatment with zoledronic acid. Haematologica. 2006 Jul;91(7):968-71.*
6. *Marx RE, Cillo JE Jr, Ulloa JJ. Oral bisphosphonate-induced osteonecrosis: risk factors, prediction of risk using serum CTX testing, prevention, and treatment. J Oral Maxillofac Surg. 2007 Dec;65(12):2397-410.*
7. *Bagan JV, Jiménez Y, Gómez D, Sirera R, Poveda R, Scully C. Collagen telopeptide (serum CTX) and its relationship with the size and number of lesions in osteonecrosis of the jaws in cancer patients on intravenous bisphosphonates. Oral Oncol. 2008 Nov;44(11):1088-9.*
8. *Rosen HN, Moses AC, Garber J, Iloputaife ID, Ross DS, Lee SL, Greenspan SL. Serum CTX: a new marker of bone resorption that shows treatment effect more often than other markers because of low coefficient of variability and large changes with bisphosphonate therapy. Calcif Tissue Int. 2000 Feb;66(2):100-3.*
9. *Kalra S, Jain V. Dental complications and management of patients on bisphosphonate therapy: A review article. J Oral Biol Craniofac Res. 2013 Jan-Apr;3(1):25-30.*
10. *Viera-Negrón YE, Ruan WH, Winger JN, Hou X, Sharawy MM, Borke JL. Effect of ovariectomy and alendronate on implant osseointegration in rat maxillary bone. J Oral Implantol. 2008;34(2):76-82.*

OP-15

Şiddetli Atrofik Maksillanın Rehabilitasyonu İçin Alternatif Total Ridge Split Osteotomi Tekniği ve Keratinize Doku Miktarını Arttırmak Amacıyla Bağ Doku Grefti Uygulanması

Özet

Dental implant tedavisinin başarısı ve idamesi alveolar kretin aşırı rezorpsiyon durumlarından olumsuz etkilenmektedir. Kemik greftleme yöntemleri, yönlendirilmiş kemik rejenerasyonu, kret ayırma ve alveoler distraksiyon gibi alternatifler, tedavi yöntemleri içerisinde yer almaktadır. Kret ayırma ve genişletme yöntemi (ridge split), bukkal ve palatal kemik kortekslerini horizontal yönde iki kortikal laminaya ayırarak çeşitli kemik greftleriyle veya doğrudan implant yerleştirilmesi esasını kapsamaktadır. Ridge Split tekniğinin en önemli avantajı, bukkal kortikal tabanı korurken kemiği horizontal yönde genişletmeye müsade etmesidir. Bu olgu sunumunda, maksilla ve mandibulası total dişsiz olan hastaya, maksiller alveoler kretin horizontal yöndeki şiddetli rezorpsiyonu nedeniyle ileri greftleme ameliyatlarına alternatif total ridge split uygulanması ve osteointegrasyon sonrası serbest bağ dokusu grefti uygulanarak keratinize dişeti miktarının arttırılması işlemi anlatılmıştır.

Anahtar Kelimeler: Ridge Split, implant cerrahisi, keratinize dişeti, greftleme

Alternative Management of Severely Atrophic Maxilla with Total Ridge Split Osteotomy Technique for Implant Therapy And Connective Tissue Graft for Achieving the Buccal Keratinized Tissue

Abstract

The success and survive of dental implant treatments are negatively affected by the alveolar crest resorption. Alternative treatments such as bone augmentation, guided bone regeneration, ridge split technique and alveolar distraction have been implemented successfully. The split- crest technique (ridge split) covers the principle of separating the buccal and palatal cortical bone into two cortical plates in the horizontal plane and augmenting with various bone substitutes or placing implants directly. The most fundamental advantage of the ridge split technique is that it allows to expand the bone in a horizontal plane while preserving the buccal cortical base. In this case report, the procedure of a total maxillary ridge split technique as an alternative to extreme augmentation surgeries and applying connective tissue grafts for to achieving attached gingiva after the osteointegration stage.

Keywords: Ridge Split, ,implant Surgery, attached gingiva, bone grafting

Giriş

Dental implant tedavisinin başarısı ve uzun dönem sürdürülebilmesi alveolar kretin aşırı rezorpsiyon durumlarından olumsuz etkilenmektedir. Kemik rezorpsiyonlarının tedavisi için farklı kemik greftleme yöntemleri, yönlendirilmiş kemik rejenerasyonu, kret ayırma ve alveoler distraksiyon gibi

alternatifler, tedavi yöntemleri içerisinde yer almaktadır. Kret ayırma ve genişletme yöntemi (ridge split), bukkal ve palatal kemik kortekslerini horizontal yönde iki kortikal laminaya ayırarak çeşitli kemik greftleriyle veya doğrudan implant yerleştirilmesi esasını kapsamaktadır.(1,2) Ridge Split tekniğinin en önemli avantajı,ikinci bir cerrahi saha oluşturmadan, bukkal kortikal tabanı korurken kemiği horizontal yönde genişletmeye müsade etmesidir.(3) Bu olgu sunumunda, maksilla ve mandibulası total dişsiz olan hastaya, maksiller alveoler kretin horizontal yöndeki şiddetli rezorpsiyonu nedeniyle ileri greftleme ameliyatlarına alternatif total ridge split uygulanması ve osteointegrasyon sonrası serbest bağ dokusu grefti uygulanarak keratinize dişeti miktarının arttırılması işlemi anlatılmıştır.

Olgu

Altmış iki yaşında sistemik bir hastalığı bulunmayan kadın hasta maksiller ve mandibuler total dişsizliğin tedavisi için kliniğimize başvurmuştur. Hasta diş eksikliğinin hareketli total protez ile tedavi edilmesini istemediğinden, implant tedavi seçeneği önerilmiştir. Klinik ve radyografik muayeneler sonucunda yapılacak olan implant operasyonu için maksiller bölgede bukkopalatinal yönde kret genişliğinin yetersiz olduğu saptanmıştır. Hastaya sabit protez için ileri cerrahi greftleme teknikleri (iliak greftleme, mandibüler otojen bloklar, yapay greft materyalleri ile augmentasyon) gerektiği anlatılmış fakat hasta ikinici bir cerrahi alanı içerecek herhangi bir prosedürü istemediği için ve alt çeneye 2 implant üzerine locator uygulaması planlanmış maksilla 13-15-23-25 nolu dişlerin yerlerine denk gelecek şekilde rehabilitasyonu planlanmıştır. Maksillanın en posteriorda sinüs tabanından başlayarak bir bütün şeklinde ridge split tekniği ile ayrılması ve aynı seans implant uygulanması planlanmıştır. Yapılması planlanan cerrahi işlemler hakkında hastaya detaylı bilgi verilmiştir.

Üst çeneye lokal anestezi yapıldıktan sonra maksiller anterior ve posterior bölgelerden önce kemiği görecek şekilde tam kalınlık flep kaldırılıp, kret açığa çıkarılınca yarım kalınlıkta devam edilecek şekilde alveol kemik açığa çıkartılmıştır (Şekil-1).

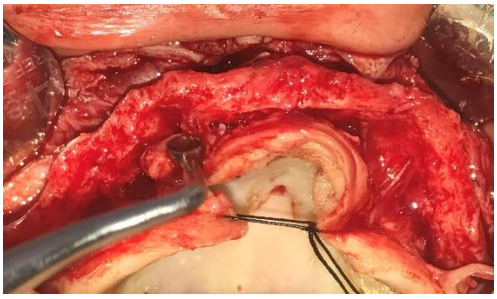

Şekil 1. Maksiller alveolar kemiğin açığa çıkarılması

Kret tepesinden ucu ince ve kesiti gittikçe kalınlaşan osteotomlar yardımıyla bukkal ve palatinal kemik iki kortikal laminaya ayrılarak implant yerleştirilmesi için yeterli mesafe elde edilmiştir (Şekil 2).

Şekil 2. Bukkal ve palatinal bölgedeki kemiğin ayrılması

Yeterli mesafenin elde edilmesi ile 13, 15, 23 ve 25 numaralı bölgelere implantlar yerleştirilmiştir. İmplantların tabanda kırığa sebep olmaması ve kemik fragmanlarının ayrılmaması için düşük torkta gönderilmesine özen gösterilmiştir. İmplantların primer stabilitelerinin yeterli olduğu görülmüş ve kapama vidaları takılarak osseointegrasyon sürecinin hareketsiz bir ortamda gerçekleşmesi amaçlanmıştır (Şekil 3).

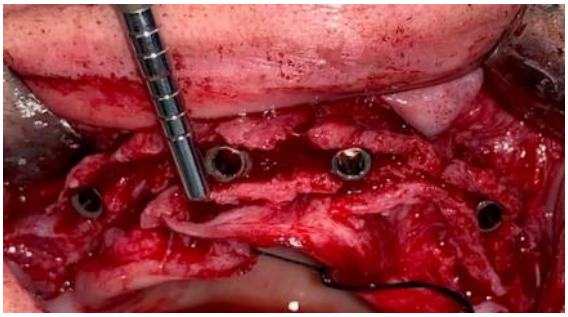

Şekil 3. İmplantların yerleştirilmesi

İmplant bölgesinin çevresindeki boşluklar işlem esnasında elde edilen otojen ve zenojenik greftlerle doldurulmuş ve üzeri rezorbe olabilen kollojen membranlar ile kapatılmıştır (Şekil 4).

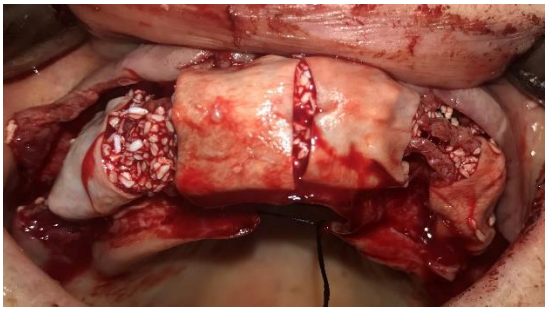

Şekil 4. Greft ve membranların yerleştirilmesi

Flebin operasyon bölgesini kapatabilmesi için künt disseksiyonla periost serbestleştirildikten sonra kilitli matriks ve basit süturlarla yumuşak doku primer olarak kapatılmıştır. Hasta ilk 3 hafta olası yumuşak doku ve greft ekspozlarını görebilmek amacıyla gün aşırı olacak şekilde kontrollere çağırılmıştır. Osteointegrasyon için beklenen 4 ayın sonunda iyileşme başlıkları takılarak (Şekil 5), implantların ve protezin başarısı ve idamesi için azalan hareketsiz diş eti miktarını arttırmak amacıyla vestibüloplasti işlemi (Şekil 6) ve 13-23-25 ve 43 numaralı bölgelere palatinal bölgeden elde edilen serbest diş eti grefti uygulanmıştır(Şekil 7, 8). Hasta rutin kontrollere çağırılmış, diş eti greftlerinin sağlıklı bir şekilde iyileştiği ve hareketsiz diş eti bandının bütün implantların çevresinde elde edildiği görülmüştür (Şekil 9,10,11).

Şekil 5. Yetersiz yapışık diş eti görüntüsü

Şekil 6. Vestibüloplasti işlemi

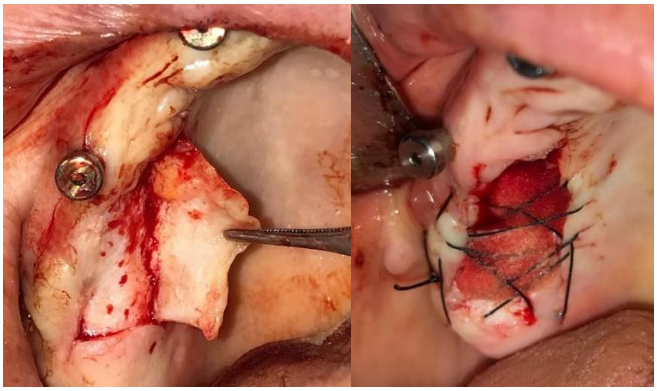

Şekil 7,8: Palatinal bölgeden bağ dokusu elde edilmesi

Şekil 9-10: Postoperatif 10.gün

Şekil 11: Postoperatif 14.gün

Tartışma

Diş çekimini takiben oluşan rezorpsiyonun süreci, kalan alveolar kretin horizontal ve vertikal boyutunda değişiklikler meydana getirmektedir. Split kret osteotomi tekniği ile bukkolingual (horizontal) yönde dar ve keskin kretlerde genişleme elde edilebilmektedir.(4) Aynı seansta implant uygulanabilme avantajından dolayı ise bekleme süreci kısalmaktadır. Bu sebeple tercih edilen alternatif tedavi metodlarından biridir.(5)

Yapılan çeşitli çalışmalar sonucunda implant çevresi keratinize doku genişliğinin, implant çevresi yumuşak doku sağlığı üzerine büyük etkisi olduğu kanıtlanmıştır. Yetersiz keratinize doku bandı

genişliği, implant alanlarının doğru bir şekilde temizlenmesine engel olarak peri-implantitis oluşmasına sebep olabilmektedir. Bu durum erken dönem implant ve kemik kaybı ile sonuçlanabilmektedir.(6,7)

Mukozitis ve peri-implantitis gelişme riskini minimum seviyeye indirmek amacıyla tedaviye ideal keratinize doku bandı genişliği elde edilmesi, mutlaka dahil edilmelidir. İmplant ve dişeti sağlığını bir bütün olarak görerek, hem implant sağ kalım oranı arttırılabilmekte, hem yeterli yatay kemik kazanım oranı korunabilmektedir.(7)

Sonuç

İleri cerrahi uygulamalardan kaçınan, ikinci bir cerrahi alan travması istemeyen veya sosyoekonomik olarak nispeten daha pahalı uygulamaları karşılayacak gücü olmayan uygun vakalarda ridge spit osteotomisi sadece lokal bölgeler ve kısa arklar için değil bütün çeneyi içine alacak şekilde yapılabilecek alternatif bir tedavi yöntemdir. Hastaların tedavinin gereksinimleri ve olası komplikasyonları hakkında bilgilendirilmesi, tedavi aşamasında flep kaydırmaya bağlı olarak sonraki dönemde gerekli olabilecek diş eti uygulamalarının hastaya anlatılmasının tedavinin başarısını etkileyeceği unutulmamalıdır.

Kaynaklar

1) Yaman Z. Cebe P. Süer B., Atrofik Maksilla Tedavisinde Kret Ayırma ve Ogmentasyon Yöntemi: Olgu Sunumu.48(2)43-50,(2014)
2) B. Elnayef, A. Monje, G.-H. Lin, J. Gargallo-Albiol, H.-L. Chan, H. L. Wang, F. Hernández-Alfaro Alveolar ridge split on horizontal bone augmentation: a systematic review Int. J. Oral Maxillofac. Implant., 30 (2015)
3) N. Jha, E.H. Choi, N.K. Kaushik, J.J. RyuTypes of devices used in ridge split procedure for alveolar bone expansion: a systematic review
   PLoS One, 12 (2017), Article e0180342
4) K. Eratalay, Tolga F. Tözüm , G. N. Güncü, İ. Tulunoğlu. Posterior Mandibular Bölgede Split Kret Tekniği Kullanılarak İmplant Yerleştirilmesi:Olgu Bildirimi. G.Ü Diş Hek. Fak. Derg.23(3):183-187,(2006)
5) Guirado, J. L.; Yuguero, M. R.; Carrión del Valle, M. J. & Zamora, G. P. A maxillary ridge-splitting technique followed by immediate placement of implants: a case report. Implant Dent., 14(1):14- 20, (2005).

6) Cranin AN. Implant surgery: the management of soft tissues. J Oral Implantol (2002);28:230-237.
7) Bouri A, Bissada N, Al-Zahrani M, Faddoul F, Nouneh I. Width of keratinized gingiva and the health status of the supporting tissues around dental implants. Int J Oral Maxillofac Implants.(2008);23:323-6.
8) Bouri A, Bissada N, Al-Zahrani M, Faddoul F,
9) Nouneh I. Width of keratinized gingiva and the
10) health status of the supporting tissues around
11) dental implants. Int J Oral Maxillofac Implants.
12) 2008;23:323-6.
13) Bouri A, Bissada N, Al-Zahrani M, Faddoul F,
14) Nouneh I. Width of keratinized gingiva and the
15) health status of the supporting tissues around
16) dental implants. Int J Oral Maxillofac Implants.
17) 2008;23:323-6.
18) Bouri A, Bissada N, Al-Zahrani M, Faddoul F,
19) Nouneh I. Width of keratinized gingiva and the
20) health status of the supporting tissues around
21) dental implants. Int J Oral Maxillofac Implants.
22) 2008;23:323-6.
23) Bouri A, Bissada N, Al-Zahrani M, Faddoul F,
24) Nouneh I. Width of keratinized gingiva and the
25) health status of the supporting tissues around
26) dental implants. Int J Oral Maxillofac Implants.
27) 2008;23:323-6.

Bouri A, Bissada N, Al-Zahrani M, Faddoul F,
Nouneh I. Width of keratinized gingiva and the
health status of the supporting tissues around
dental implants. Int J Oral Maxillofac Implants.
2008;23:323-6.

OP-22

INVESTIGATION OF THE STRESS AROUND THE ZYGOMATIC AND DENTAL IMPLANTS WHICH APPLIED IN THE EDENTULOUS MAXILLA

Aykut Çetindağ*, Belgin Gülsün*

***Dicle University, Faculty of Dentistry, Department of Oral and Maxillofacial Surgery, Turkey, Diyarbakır**

OBJECTIVE: In advanced atrophies in the posterior maxilla, implant supported prostheses using zygomatic bone for prosthetic rehabilitation are one of the treatment options. In our study, a model showing posterior atrophy was obtained by using computerized tomographic records. The aim of our study is to choose the most accurate surgical planning according to the stress values that occur as a result of the applied forces by applying dental implants in different localization together with the zygoma implant to this model.

MATERIALS AND METHODS: In our study, one zygoma implant on the right and left sides in group 1, in group 2, a zygoma implant to the right and left maxilla and a dental implant to the right and left 1st premolar teeth, in group 3, a zygoma implant to the right and left maxilla and a dental implant to the right and left lateral teeth were applied. 150 N were applied vertically in the prosthetic superstructure from 2-4-6-7 teeth and 50 N force was oblique at 30°. As a result of the forces applied in the study, von Mises stress values occurring in the zygoma implant and metal substructure were examined by finite element stress analysis.

RESULTS: In our study, it was observed that the first group, in which one zygomatic implant was applied, was the group with the highest stress value. The lowest stress value was observed in the third group in which implants were applied to each right and left lateral tooth area in addition to the right and left zygomatic implants.

CONCLUSION: As a result of our study, it has been observed that dental implants applied in addition to the zygoma implant reduced stress, and it is believed that the localization of dental implants is also important in terms of stress values.

KEYWORDS: Atrophic maxilla, finite element stress analysis, zygomatic implant

INTRODUCTION: Extra surgical procedures applied to increase the amount of bone and consequently increase in treatment costs, prolongation of the recovery period,
It also brings disadvantages such as decreased patient comfort and high risk of complications along with operative pain. In order to prevent these disadvantages, short or angled implants, pterygoid implants and zygomatic implants have been used in recent years (1-5).

The fact that complex surgical procedures have some disadvantages in the reconstruction of atrophic edentulous maxilla caused researchers to turn to different techniques. In the 1990s, the zygomatic bone was

considered as an anchorage source for implant application in prosthetic rehabilitation of cases with severe maxilla atrophy (6).

Aparicio et al. first studied the possibility of placing dental implants in the zygomatic bone in 1993 (7). On the other hand, Weischer et al. Conducted ongoing studies on the use of the zygomatic bone as an anchorage source in the prosthetic treatment of patients who underwent maxillectomy (6). Weischer et al. Conducted studies on the use of the zygomatic bone as an anchorage source in the prosthetic treatment of patients who underwent maxillectomy in 1997 (6). It was decided in 1993 that the zygomatic bone could be used as a support in implant stabilization (7).

Zygoma implants are made of self tapping titanium alloy. Zygomatic implants consisting of hardened oxidized surface area have been defined in different lengths and these lengths vary between 30-52.5 mm. The implants with a 45 degree angle head can compensate the angle between the maxilla and the zygoma. The apical 2/3 part that joins the zygoma is 4 mm in diameter and the 1/3 part located in the residual maxillary alveolar process is 4.5 or 5 mm in diameter. These implants are placed in the first or second premolar level, from the palatinal bone towards the zygoma bone body (8).

Due to the increase of researchers interested in biomechanics in recent years, finite element analysis method has been used frequently in the field of dentistry. The advantages of finite element analysis include obtaining realistic models in digital environment, analyzing the stresses in material and bone tissue in detail, repeating the analysis as many times as desired, and being a fast and effective method. On the other hand, the physical properties of the material used, the strength values, the size and shape of the elements are completely under the control of the human factor, and a mistake in entering these values into the program can affect all analysis results. In addition, a serious technology is needed to use the programs. Despite some negative features, finite element analysis is a very effective method in examining the unknown behaviors of many materials that are considered difficult in experimental studies. (9,10).

The aim of our study is to choose the most accurate surgical planning by applying a dental implant in different localization with a zygoma implant to the bilateral atrophic edentulous maxilla, examining the stress values resulting from vertical and oblique forces applied by finite element analysis.

MATERIALS and METHODS: In our study, zygomatic and dental implants in 3 different planning were applied to the maxilla with posterior atrophy. In the first group, one zygomatic implant on the right and left sides,in the second group one zygomatic implant on the right and left sides and one dental implant in the first premolar region, in the third group one zygomatic implant on the right and left sides and one dental implant in the lateral region implant has been applied. The zygoma implants (Nobel Biocare® AB, Goteborg, Sweden) used in the study are 4 mm in diameter and 35 mm in length, and dental implants (Nobel Biocare® AB, Goteborg, Sweden) are 3.5 mm in diameter and 10 mm in length. Zygomatic implants were placed in the models by the extrasinus method, and 150 N force was applied vertically from the area of the teeth numbered 2-4-6-7 in the prosthetic superstructure and 50 N force was applied obliquely at an angle of 30 degrees. As a result of the forces applied in the study, the von Mises stress values occurring in the zygoma implant and metal substructure were analyzed by finite element

stress analysis. In stress analysis, the unit is expressed in MPa (N / mm2). In the analysis, the regions with intense stress are observed in red, while the regions with low stress are shown in blue.

RESULTS: The stress values occurring in the zygoma implant as a result of vertical forces were measured as 1075.83 MPa in the first group, 177.313 MPa in the second group, and 109.746 MPa in the third group.

The stress values occurring in the metal substructure as a result of vertical forces were 637.385 MPa in the first group, 183.035 MPa in the second group, and 113.701 MPa in the third group.

As a result of vertical forces, stress values in both the zygoma implant and the metal substructure were seen as Group 1, Group 2 and Group 3 from high to low, respectively.

The stress values occurring in the zygoma implant as a result of oblique forces were measured as 331.527 MPa in the first group, 55.0533 MPa in the second group, and 25.5098 MPa in the third group.

The stress values on the metal substructure as a result of oblique forces were measured as 191.386 MPa in the first group, 51.2175 in the second group and 27.5472 MPa in the third group.

As a result of oblique forces, stress values in both the zygoma implant and the metal substructure were seen as group 1, group 2 and group 3 from high to low, respectively.

According to the stress values resulting from the application of both vertical and oblique forces, it was thought that the 3rd group could be used as ideal planning in the atrophic edentulous maxilla, and then the 2nd group. We can evaluate the 1st group with the highest stress values as planning with the highest probability of failure.

DISCUSSION: Ujigawa et al., In their finite element stress analysis studies (2007), examined the stress distribution of zygomatic implants in craniofacial structures. In their study, they obtained 2 different models and applied only the zygoma implant with the intrasinus technique to the first model, and two conventional implants to the premaxillary region with the zygoma implant with the same technique in the second model. They reported that conventional implants used in addition to the zygomatic implant reduce the stresses in the zygomatic bone and around the zygomatic implant (11).

Ishak and Aisyah compared the effects of different numbers of conventional implants on the stability of the zygoma implant in their finite element stress analysis study (2014). They created 3 models; in first model only one zygoma implant on one side, one zygoma and one conventional implant on the second, one zygoma and 2 conventional implants on the third model. According to the results of the study; They found that conventional implants used in addition to the zygoma implant had a positive effect on stability (12).

In their finite element stress analysis studies conducted by Ishak et al. (2012), they applied 150 N force vertically to the metal substructure at the level of 1-4-6-7 teeth and examined the stress distribution in occlusal loads of zygoma implants applied with different surgical methods in the treatment of atrophic maxilla. As a result, they saw that there was no big difference and reported that there was more stress distribution in the extramaxillary approach than in the intrasinus approach (13).

Wen et al. Reported in their finite element stress analysis studies conducted in 2014 that occlusal forces are carried by the zygoma and transmitted to the zygomatic arch. According to their results, they stated that they saw the highest Von Mises stress values in the neck and coronal parts of the implant (14).

In our study, based on the literature support, we applied zygomatic implants and dental implants of different localization to the three-dimensional model of a patient with bilateral posterior maxilla atrophy, and we used finite element stress analysis to examine the stress amounts and stress areas in the surrounding tissues caused by the masticator forces. A force of 150 N vertically and 50 N obliquely at an angle of 30 degrees was applied to the 3 different models we planned, over the teeth numbered 2-4-6-7, and the answer to the most accurate surgical planning was tried to be found.

CONCLUSION: When we interpret the results in general, dental implants applied in addition to the zygoma implant reduced the stresses on the materials. The stresses caused by vertical forces were measured higher than the stresses caused by oblique forces. Dental implants applied to the lateral tooth area have reduced the stresses on the metal substructure and zygomatic implants by providing a more balanced distribution of forces compared to dental implants applied to the 1st premolar tooth area. In addition, as a result of the data we obtained, it was seen that the Von Mises stress value was higher in the neck region of the zygomatic implant.

REFERENCES

1. Migliorança R, Sotto-Maior B, Senna P, Francischone C, Cury A. Immediate occlusal loading of extrasinus zygomatic implants: A prospective cohort study with a follow-up period of 8 years. Int J Oral Maxillofac Surg. 2012;41(9).

2. Davo R, Pons O, Rojas J, Carpio E. Immediate function of four zygomatic implants: a 1-year report of a prospective study. Eur J Oral Implant. 2010;3(4):323–34.

3. Hasan I, Heinemann F, Aitlahrach M, Bourauel C. Biomechanical finite element analysis of small diameter and short dental implant. Biomed Technol. 2010;55(6):341–50.

4. Sudhakar J, Ali S, Karthikeyan S. Zygomatic Implants- A Review. J Indian Acad Dent Spec Res. 2011;2:24–8.

5. O'Connell J, Cotter E, Kearns G. Maxillary reconstruction using zygomatic imolants: a report of two cases. J Irısh Dent Assoc. 2011;57:146–55.

6. Weischer T, Schettler D, Mohr C. Titanium implants in the zygoma as retaining elements after hemimaxillectomy. Int J Oral Maxillofac Implant. 1997;12:211–4.

7. Aparicio C, Branemark P, Keller E, Olive J. Reconstruction of the premaxilla with autogenous iliac bone in combination with autogenous iliac bone in combination with osseointegrated implants. Int J Oral Maxillofac Implant. 1993;8:61–7.

8. Malevez C, Daelemans P, Adriaenssens P, Durdu F. Use of zygomatic implants to deal with resorbed posterior maxillae. Periodontol 2000. 2003;33:82–9.

9. Daegling D, Hylander W. Experimental observation, theoretical models, and biomechanical inference in the study of mandibular form. Am J Phys Anthropol. 2000;112(4):541–51.

10. Farah J, Craig R, Meroueh K. Finite element analysis of a mandibular model. J Oral Rehabil. 1988;15(6):61524.

11. Ujigawa K, Kato Y, Kizu Y, Tonogi M, GY Y. Three- dimensional finite elemental analysis of zygomatic implants in craniofacial structures. Int J Oral Maxillofac Surg. 2007;36(7):620–5.

12. Ishak M, Aisyah A. Comparative Study of Different Conventional Dental Implant Numbers on Zygomatic Implant Stability – A Finite Element Analysis. Aust J Basic Appl Sci. 2014;8(7):52–7.

13. Ishak M, Kadir M, Sulaiman E, Kasim N. Finite element analysis of different surgical approaches in various occlusal loading locations for zygomatic implant placement for the treatment of atrophic maxillae. Int J Oral Maxillofac Surg. 2012;41(9):1077–89.

14. Wen H, Guo W, Liang R et al. Finite element analysis of three zygomatic implant techniques for the severely atrophic edentulous maxilla. J Prosthet Dent. 2014;111(3):203–15.

FIGURES:

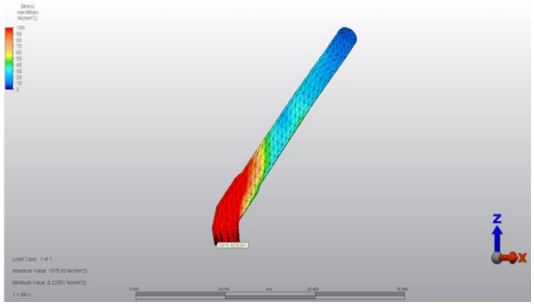

Fig 1. von mises stress value of zygoma implant against vertical force in the 1st group

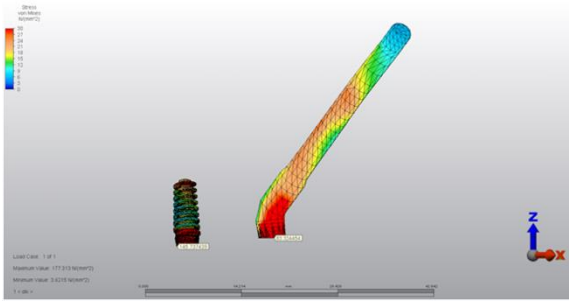

Fig 2. von mises stress value of zygoma implant against vertical force in the 2nd group

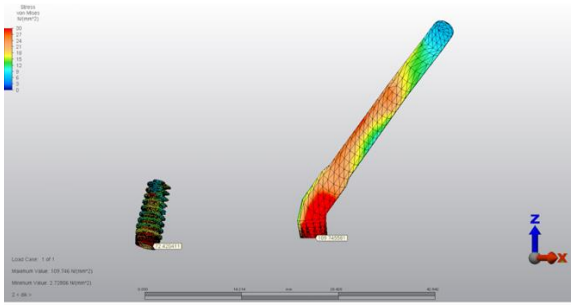

Fig 3. von mises stress value of zygoma implant against vertical force in the 3rd group

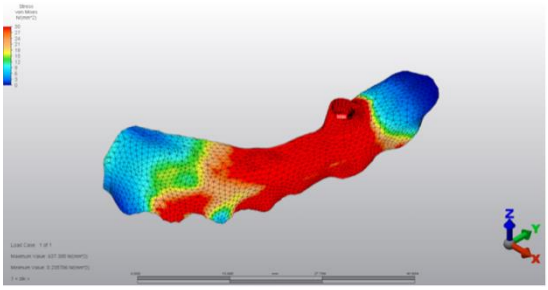

Fig. 4. von mises stress value of the metal substructure against vertical force in the 1st group

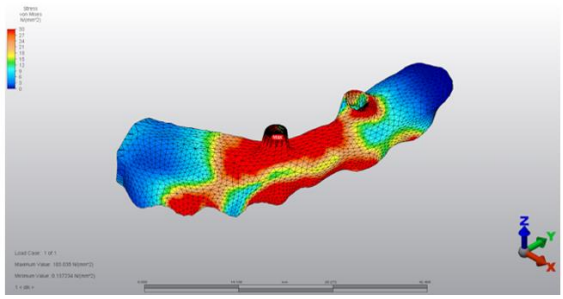

Fig 5. von mises stress value of the metal substructure against vertical force in the 2nd group

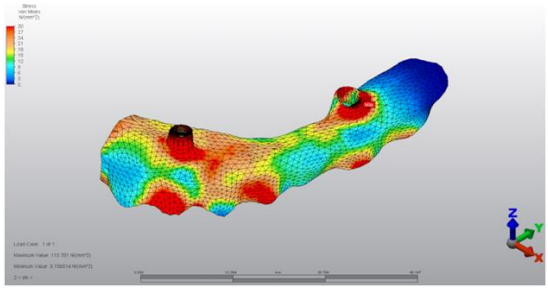

Fig 6. von mises stress value of the metal substructure against vertical force in the 3rd group

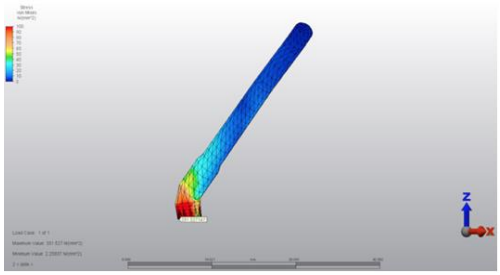

Fig 7. von mises stress value of zygoma implant against oblique force in the 1st group

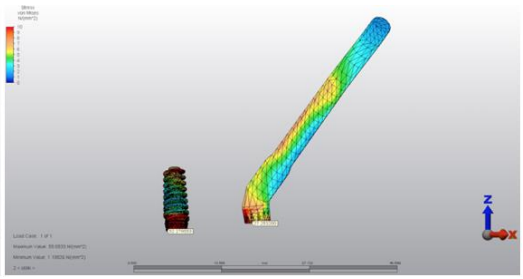

Fig 8. von mises stress value of zygoma implant against oblique force in the 2nd group

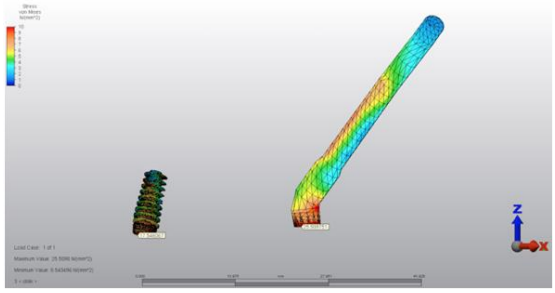

Fig 9. von mises stress value of zygoma implant against oblique force in the 3rd group

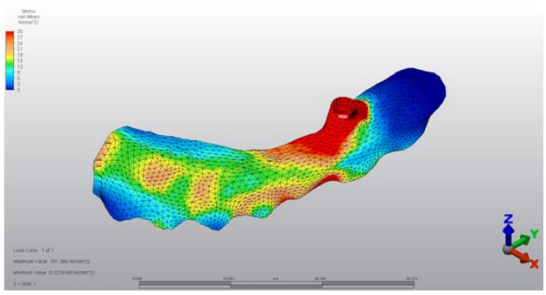

Fig. 10. von mises stress value of the metal substructure against oblique force in the 1st group

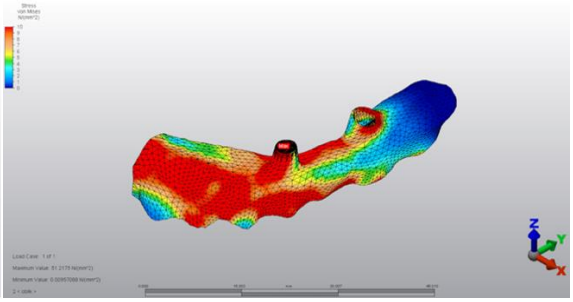

Fig 11. von mises stress value of the metal substructure against oblique force in the 2nd group

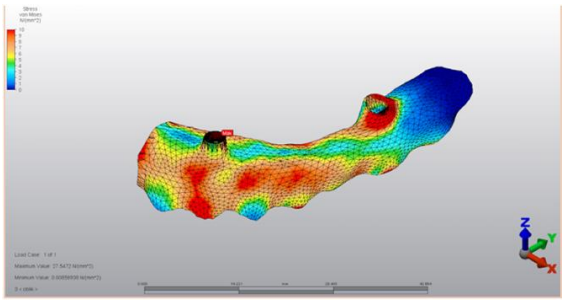

Fig 12. von mises stress value of the metal substructure against oblique force in the 3rd group

TABLES:

Vertical Force	Von Mises Stress Values of Zygomatic Implants
1st Group (One zygomatic implant)	1075.83
2nd Group (One zygomatic implant and one dental implant to the first premolar tooth area)	177.313

3rd Group (One zygomatic implant and one dental implant to lateral tooth area)	109.746

Table 1. Results of von mises stress values of zygomatic implant against vertical force

Vertical Force	Von Mises Stress Values of Metal Substructure
1st Group	637.385
2nd Group	183.035
3rd Group	113.701

Table 2. Results of von mises stress values of the metal substructure against vertical force

Oblique Force	Von Mises Stress Values of Zygomatic Implants
1st Group	331.527
2nd Group	55.0533
3rd Group	25.5098

Table 3. Results of von mises stress values of zygomatic implant against oblique force

Oblique Force	Von Mises Stress Values of Metal Substructure
1st Group	191.386
2nd Group	51.2175
3rd Group	27.5472

Table 4. Results of von mises stress values of the metal substructure against oblique force

This study was supported by the Dicle University Scientific Research Projects Coordinator with the project number DİŞ.18.006. We offer our thanks.

OP-23

EFFECT OF DIFFERENT IMPLANT SURFACES ON GINGIVAL TISSUES

Muhammet Bahattin Bingül(1), Belgin Gülsün(2)

1Harran University, Faculty of Dentistry, Department of Oral and Maxillofacial Surgery, Şanlıurfa

2Dicle University, Faculty of Dentistry, Department of Oral and Maxillofacial Surgery, Diyarbakır

SUMMARY

OBJECTIVE: In our study, to reveal the effect of different implant surfaces on gingival tissues with PES and BES.

MATERIAL AND METHOD: A total of 117 dental implants were followed clinically. Gingival index (loe-silness), PES (Pink Aesthetic Score) and WES (White Aesthetic Score) values were evaluated, recorded 1 week after the healing head was placed, 3, 6 and 12 months after the end of the prosthesis. The data were analyzed with IBM SPSS Statistics Version 22 package program.

RESULTS: There is no statistically significant difference between the groups in terms of gingival index values ($p > 0.05$). While there was no statistically significant difference between the times in terms of gingival index values in the micro-roughened surface group ($p > 0.05$), there was a statistically significant difference between the times in terms of gingival index values in the nano laser excimer technology group ($p < 0.05$). There was no statistically significant difference between the groups in terms of total PES values at all times ($p > 0.05$), but there was an increase in PES values in both groups over time. In the nano laser excimer technology group, although no statistically significant difference was found between times in terms of total WES values, a statistically significant difference was found between the times in terms of total WES values in the micro-roughened surface group ($p < 0.05$).

CONCLUSION: In our study, it was concluded that the surface properties of dental implants used missing dental rehabilitation have effect on marginal tissues.

Keywords: Dental implant, PES, WES.

INTRODUCTION

Since dental implants are biocompatible materials, their use in dentistry has become widespread in order to regain function and aesthetics in missing teeth rehabilitation (1). The healing processes begin with the placement of dental implants produced from the titanium element by modifying the shape and surface properties of the alveolar bone. Following the initial resorption in the surrounding bone, new bone tissue formation and mineralization occurs around the implant in about 3/6 months. This period is the "osseointegration" process of the implant. If this period is completed without any problems, prosthetic treatments of dental implants are performed (2).

To be able to evaluate an implant as successful, it must be clinically non-mobile and osseointegrated. The concept of osseointegration is a histological term and has been defined by Branemark and his colleagues as "direct structural and functional connection between the living bone tissue and the implant surface under loading" (3, 4).

Since implants compensate for tooth loss, dental implants made of various materials, with many different designs and surface properties have been put on the market (5). This is important in order to be able to compare the results of clinical studies on different implants and to evaluate the success of the treatment. Undoubtedly, in order to show the accuracy and success of the data obtained as a result of these scientific researches, objective and evidence-based information is required (6).

The density or quality of the existing bone in the areas of tooth loss, implant design and surface features, treatment protocol, surgical

approach options, are among the factors that determine the healing time and loading during the prosthetic phase (7).

Another issue that is closely related to patient satisfaction in dental implant applications in recent years is aesthetics. As a result of the treatment, patients should be aesthetically satisfied. Therefore, Pink Aesthetic Score / White Aesthetic Score (PES / BES, Pink Esthetic Score / White Esthetic Score, PES / WES) data have been used more frequently in recent years (8). Fürhauser et al. Stated that when evaluating the aesthetics of single-tooth implants, it is not sufficient to evaluate only the gingival papillae, but also the soft tissue color, contour, surface feature and marginal gingival level (9). In this study, we aim to reveal the effect of different implant surfaces on gingival tissues with PES and BES values.

MATERIAL AND METHOD

Our research was supported by Dicle University Scientific Research Projects Coordinator with the project number DİŞ.17.025. Before starting this study, ethics committee approval was obtained from Dicle University Faculty of Dentistry Local Ethics Committee with the protocol number 2017/11 dated 31.05.2017.

The study groups consisted of individuals in Dicle University Faculty of Dentistry, Department of Oral and Maxillofacial Surgery, where 2 different dental implant models with micro-roughened surface feature with nano laser excimer technology were applied. A total of 117 dental implants were placed in these individuals.

The parameters we use in our research; The data were gingival index (loe-silness), Pink Aesthetic Score / White Aesthetic Score (PES / BES, Pink Esthetic Score / White Esthetic Score, PES / WES) data. These parameters were evaluated 1 week after the healing cap was put on, 3 months, 6 months and 12 months after the end of the prosthesis.

Material Used

In this study, 2 different implant models with nano laser excimer technology (Biohorizons®, Bone Level, USA) and micro-roughened surface properties (Zimmer®, Bone Level, Germany) were used.

Treatment Procedure

Panoramic and periapical x-rays were taken from the patients before the procedure in order to make appropriate treatment. In addition, patients were informed extensively possible complications before implant application.

Clinical Follow-up

Gingival Index (Silness and Löe)

This index system was developed in 1963 by Silness and Löe. The main sign of inflammation in the system is bleeding. It is determined by giving values to the gums in the mesial, distal, vestibule and lingual of the teeth according to the edema and bleeding status. These values are then summed and divided by four. These measurements were made with the aid of a periodontal probe (Hu-Friedy®). In this way, gingival index is calculated.

0: Healthy gums, no inflammation.

1: There is mild inflammation, discoloration and mild edema in the gums, there is no bleeding in the peeling.

2: There is moderate inflammation, edema and redness in the gums, there is bleeding at the end.

3: There is severe inflammation, edema and redness in the gums, there is spontaneous bleeding.

Criteria Recorded When Evaluating Peri-Implant Aesthetics

While determining the score according to PES, 7 criteria out of the photographs are evaluated as 0-1-2:

•Mesial and distal papillae: 0 = no papillae, 1 = no papillary filling, 2 = complete papillary filling

• Soft tissue level: 0 = There is> 2mm difference with natural teeth, 1 = There is 1-2 mm difference with natural teeth, 2 = <1mm difference with natural teeth.

•Soft tissue contour: 0 = Unnatural contour, 1 = Quite natural contour, 2 = Natural contour

• Alveolar process: 0 = Significant insufficiency compared to natural tooth, 1 = Mild insufficiency, 2 = No difference

•Soft tissue color: 0 = Significant difference compared to natural teeth, 1 = Slight difference, 2 = No difference

•Soft tissue surface structure: 0 = Significant difference compared to natural teeth, 1 = Slight difference, 2 = No difference

BES, on the other hand, examines 5 basic criteria that should be considered when evaluating the aesthetics of conventional fixed restorations, which are based on implant restorations. The criteria are calculated over 10 points, and having 6 points or more indicates an acceptable aesthetic.

•Crown form: 0 = Significant difference with natural teeth, 1 = Slight difference, 2 = No difference

•Crown contour / volume: 0 = Significant difference with natural tooth, 1 = Slight difference, 2 = No difference

• Crown color: 0 = Significant difference with natural teeth, 1 = Slight difference, 2 = No difference

•Crown surface structure: 0 = Significant difference with natural teeth, 1 = Slight difference, 2 = No difference

•Crown translucency and characterization: 0 = Significant difference with natural tooth, 1 = Slight difference, 2 = No difference

Statistical Analysis

The data obtained in this study were analyzed with IBM SPSS Statistics Version 22 package program. Shapiro Wilk's was used while investigating the status of variables coming from normal distribution.

Mann Whitney U Test was used to examine the differences between groups. While examining the relationships between groups of nominal variables, Chi-Square analysis was applied. Kappa Fit analysis was applied to measure the fit between dependent nominal variables. 0.05 was used as the significance level while interpreting the results; It was stated that there is a significant relationship when $p < 0.05$, and there is no significant relationship when $p > 0.05$.

RESULTS

There was no loss in the implants included in the study, but complications occurred in 4 out of 59 implants in the nano laser excimer technology group. All of the complications that occurred were periimplantitis. Complications developed in 6 out of 58 implants in the micro-roughened surface group. Soft tissue loss developed in 4 of these 6 implants and free gingiva graft operation was applied to these patients. There was an abutment fracture in one of the other implants, and a prosthesis fracture in the other.

There is no statistically significant difference between the groups (micro-roughened surface and nano laser excimer technology) in terms of gingival index values ($p > 0.05$) (Figure-1).

There is no statistically significant difference between the times in terms of gingival index values in the micro-roughened surface group ($p > 0.05$) (Figure-2).

There is a statistically significant difference between times in terms of gingival index values in the nano laser excimer technology group ($p < 0.05$). In the nano laser excimer technology group, gingival index 12 month value is significantly lower than gingival index 0 month and gingival index 3 month value (Figure-2).

There is no statistically significant difference between the micro-roughened surface and the nano laser excimer technology surface in terms of the total pink aesthetic score values at all times ($p > 0.05$) (Figure-3).

There is a statistically significant difference between the times in terms of total pink aesthetic score values in the micro-roughened surface and nano laser excimer technology group ($p < 0.05$). In the micro-roughened surface group, the total pink aesthetic score at 3 months and 6 months was significantly lower than the 12 month value. In the nano laser excimer technology group, the total pink aesthetic score was significantly lower than the 0th month value compared to the 6th and 12th month values (Figure-4). It is seen that PES scores increase over time in both groups.

A statistically significant difference was found between micro-roughened surface and nano laser excimer technology in terms of total white aesthetic score values at all times (0, 3, 6, and 12 months) ($p < 0.05$). The BES scores of dental implants with nano laser excimer technology are higher at all times than the micro-roughened surface group (Figure-5).

Although there is no statistically significant difference between times in terms of total white aesthetic score values in the nano laser excimer technology group ($p > 0.05$), there is a statistically significant difference between times in terms of total white aesthetic score values in the micro-roughened surface group ($p < 0, 05$). In the micro-roughened surface group, the total white aesthetic score was significantly lower than the 0th month value compared to the 6th and 12th month values (Figure-6).

DISCUSSION

Due to the high success rate, the use of dental implants in dentistry has increased and therefore many implant systems have been developed. In order to receive long years of service from dental implants, it is necessary to perform routine controls. In order to be able to treat any

adverse events in the early period, the patient should be kept under control by using all kinds of clinical and radiological diagnostic methods (10). In our study, we also followed up patients at regular intervals.

In our study, we did not experience implant loss in both nano laser excimer technology and dental implants with micro-roughened surfaces. Among the implant surface preparation methods, there are studies reporting that morphological methods are more successful than physico-chemical methods (11).

In their retrospective study by Halperin-Sternfeld et al, in which they examined the effect of vestibular depth on peri-implanter parameters, they used Loe & Silness and periodontal probe (Hu-Friedy®) for gingival index (12). In our study, we used Loe & Silness scoring for gingival index and Hu-Friedy® as periodontal probe in accordance with the literature. Gültekin et al. Compared 56 dental implants with neck design features and 47 dental implants with nano laser excimer technology neck design, and recorded the gingival index values in the 12th, 24th and 36th month periods. After three years of study, they could not find a significant difference between the groups in terms of gingival index values. They explained this situation with oral hygiene control (13). Similar results have emerged in our study. We believe that oral hygiene motivation and routine periodic controls set the ground for this situation.

In a study followed for 5 years, they found that gingival index values decreased until the 2nd year, while these values increased in the following years. Researchers have suggested that oral care motivation and diet may cause this condition (14). In our study; No statistically significant difference was found between the groups in terms of gingival index values ($p > 0.05$). In obtaining similar results in both groups; We attribute the effectiveness of routine control appointments to short intervals and increasing patient motivation at each check-up.

Although there was no statistically significant difference between times in terms of gingival index values in the MTX surface group ($p > 0.05$), a statistically significant difference was found between times in terms of gingival index values in the nano laser excimer technology group ($p < 0.05$). In the nano laser excimer technology group, the gingival index is significantly lower than the 12th month (0.28 ± 0.28), 0th month (0.47 ± 0.44) and 3rd month (0.44 ± 0.38) values. While the MTX surface in dental implants in the micro-roughened surface group only increases bone apposition, we believe that such a result is obtained because the micro cavities in the implants with nano laser excimer technology restrict the migration of the gingival tissues to the apical. Because dental implants with nano laser excimer technology have a design that is roughened with 0.7 mm long 8 microns in the middle of the neck area and aims to create a gingival attachment. Thus, we think that the collagen fibers found in natural teeth will act as an epithelial barrier in dental implants with nano laser excimer technology, and plaque accumulation will be prevented from going deeper.

As a result of the treatment, patients should be aesthetically satisfied. Therefore, Pink Aesthetic Score / White Aesthetic Score (PES / BES, Pink Esthetic Score / White Esthetic Score, PES / WES) data have been used more frequently in recent years (15).

In accordance with the reviewed literature, dental implants; Crown surface structure, color, soft tissue contour, exit profile, papilla filling, compatibility of the restoration with neighboring and contralateral teeth are among the important factors in terms of aesthetics. In 2005, a newly defined PES test was found for soft tissue evaluations in the periimplanter area. In this study, the authors argued that PES is an appropriate method for evaluating the soft tissues of implant restorations (9).

In our study, no statistically significant difference was found between micro-roughened surface and nano laser excimer technology in terms of total PES at all times ($p > 0.05$). In the micro-roughened surface group, the PES value in the 0th month was 8.71 ± 1.08, the PES value

in the 3rd month was 8.61 ± 1.1, the 6th month PES value was 8.89 ± 1.23, the 12th month PES value was 9.11 ± 1.29; In the group of nano laser excimer technology, we found these values as 8.63 ± 1.45, 8.89 ± 1.40, 9.04 ± 1.43, 9.04 ± 1.43, respectively. However, a statistically significant difference was found in terms of total pink aesthetic score values between dental implants with micro-roughened surface and nano laser excimer technology ($p < 0.05$). In addition, an increase in PES scores was observed in both groups over time. In a study by Belser; The PES and BES scores were evaluated at an acceptable level, and the reason for this was explained by the choice of implant with ideal design to protect bone tissues during surgical application (15). In parallel with the work of the researcher named Belser, we can achieve acceptable PES values; We can interpret it as applying gingival-sparing surgical techniques, determining the correct implant loading time and choosing the correct implant surface.

The researcher named Cosyn suggested that the amount of buccal bone may cause changes in PES values (16). The increase in PES scores over time in both groups can be explained by the fact that crestal bone resorption remains at the physiological limit, and thus soft tissue migration does not shift to the apical. In other words, more aesthetic results have been found in soft tissue with bone support. In addition, we can interpret this situation as the feature of the dental implants we prefer to create periodontal attachments or systems that can protect this attachment. On the other hand, we think that the geometric structure of dental implants may also affect the amount of bone remaining in the buccal region, because we believe that the amount of buccal bone may cause changes in the PES values, in line with the study of the researcher named Cosyn.

Guarnieri et al., In a study in which they evaluated 46 laser-lok (Biohorizons®, Bone Level, USA) implants, found the total PES and BES values as 12.25 and 8.81, respectively. In addition, they argued that the acceptable PES values were 8-11 and the BES values were 6-8, as a result of the studies they examined (17).

In our study, there was a statistically significant difference between the groups in terms of BES values at all times ($p < 0.05$). ± 1.27, and the BES value at the 12th month was 5.75 ± 1.27; In the group of nano laser excimer technology, we found these values as 6.70 ± 1.32, 6.70 ± 1.32, 6.67 ± 1.30, 6.67 ± 1.30, respectively. In line with the literature, we can interpret our results as an acceptable value since the BES scores of dental implants with nano laser excimer technology are in the range of 6-8, but the BES scores in the micro-roughened surface group are below 6. BES scores of dental implants with nano laser excimer technology are higher than MTX surface group at all times. We think that laser microwaves in dental implants with nano laser excimer technology affect the alignment of fibroblasts and consequently position the connective tissue at the ideal point for restorations. Due to this positive development in soft tissue, we can say that better restorations are made. Although there was no statistically significant difference between times in terms of BES values in the nano laser excimer technology group, there was a statistically significant difference between times in terms of total BES values in the MTX surface group ($p < 0.05$). In the dental implant group with MTX surface, the increasing BES score value over time may be more compatible with natural teeth depending on the color selection of the restorations, and the periodontal or endodontic origin of the tooth extracted from the dental implant application area may also be affected.

CONCLUSION

Patients who have undergone dental implant treatment do not want to worry about long-term function and aesthetics. We found that the surface properties of the dental implant materials used in the rehabilitation of tooth deficiencies can affect the marginal tissues as well as the aesthetics of dental implant rehabilitation.

REFERENCES

1. Yerit KC, Posch M, Seemann M, Hainich S, Dörtbudak O, Turhani D, et al. Implant survival in mandibles of irradiated oral cancer patients. Clinical oral implants research. 2006;17(3):337-44.

2. Çinkılıç ÖSG, Celal B. İyileşme döneminde uygulanan LED fotobiyomodulasyon tedavisinin farklı yüzey özelliklerine sahip dental implantlarda, implant stabilite oranlarına etkisinin rezonans frekans analizi ile karşılaştırmalı olarak incelenmesi. 2011.

3. Albrektsson T, Wennerberg A. The impact of oral implants-past and future, 19662042. J Can Dent Assoc. 2005;71(5):327.

4. Fiorellini JP, Nevins ML. Dental implant considerations in the diabetic patient. Periodontology 2000. 2000;23(1):73-7.

5. Aljateeli M, Wang H-L. Implant microdesigns and their impact on osseointegration. Implant dentistry. 2013;22(2):127-32.

6. Weng D, Jacobson Z, Tarnow D, Hürzeler MB, Faehn O, Sanavi F, et al. A prospective multicenter clinical trial of 3i machined-surface implants: results after 6 years of follow-up. International Journal of Oral & Maxillofacial Implants. 2003;18(3).

7. Albrektsson T ZG, Worthington P, Eriksson AR. . The long-term efficacy of currently used dental implants: a review and proposed criteria of success. . International Journal of Oral and Maxillofacial Implants 1986;1:11-25.

8. Al-Omiri M, Hantash, R.A.,Al-Wahadni, A. Satisfaction with dental implants: a literature review. Implant dentistry. 2005;14(4):399-406.

9. Fürhauser R FD, Benesch T. Evaluation of soft tissue around singletooth implant crowns: the pink esthetic score. Clin Oral Implants Res. 2005;16:639-44.

10. Şener H KA. Dental implantların uzun dönem takibinde başarıyı etkileyen klinik ve radyolojik parametrelerin değerlendirilmesi İstanbul: İstanbul Üniversitesi; 2008.

11. Uzun G KF. İmplantların yüzey özellikleri ve osseointegrasyon. Atatürk üni diş hek fak derg 2007;2:43-50.

12. Halperin M GH, Machtei EE. The association between shallow vestibular depth and peri-implant parameters: a retrospective 6 years longitudinal study. J Clin Periodontol. 2016;43(3):305-10.

13. Gültekin BA SA, Gültekin P, Yalcin S, Mijiritsky E. Does the Laser-Microtextured Short Implant Collar Design Reduce Marginal Bone Loss in Comparison with a Machined Collar? BioMed Research International 2016.

14. Thierer T DJ, Keith JD, Sanders JJ,Tarnow DP, Rivers JA. Five Year Prospective Clinical Evaluation of Highly Crystalline HA MP-1−Coated Dental Implants. Journal of Oral Implantology. 2008;34(1).

15. Belser UC, Grutter, L., Vailati, F., Bornstein, M.M., Weber, H.P.,Buser, D. Outcome evaluation of early placed maxillary anterior

single-tooth implants using objective esthetic criteria: a cross-sectional, retrospective study in 45 patients with a 2- to 4-year follow-up using pink and white esthetic scores. Journal of periodontology. 2009;80(1):140-51.

16. Cosyn J EA, Hermans A, Vervaeke S, De Bruyn H, Cleymaet R. A 5-year prospective study on single immediate implants in the aesthetic zone. J Clin Periodontol. 2016;43:702-9.

17. Guarnieri R PR, Testarelli L, Siciliano V, Grande M. Clinical, Radiographic, and Esthetic Evaluation of Immediately Loaded Laser MicrotexturedImplantsPlacedintoFresh ExtractionSocketsintheAnteriorMaxilla: A 2-Year Retrospective Multicentric Study. Implant Dentistry 2014;23(2):144-54.

FİGURES

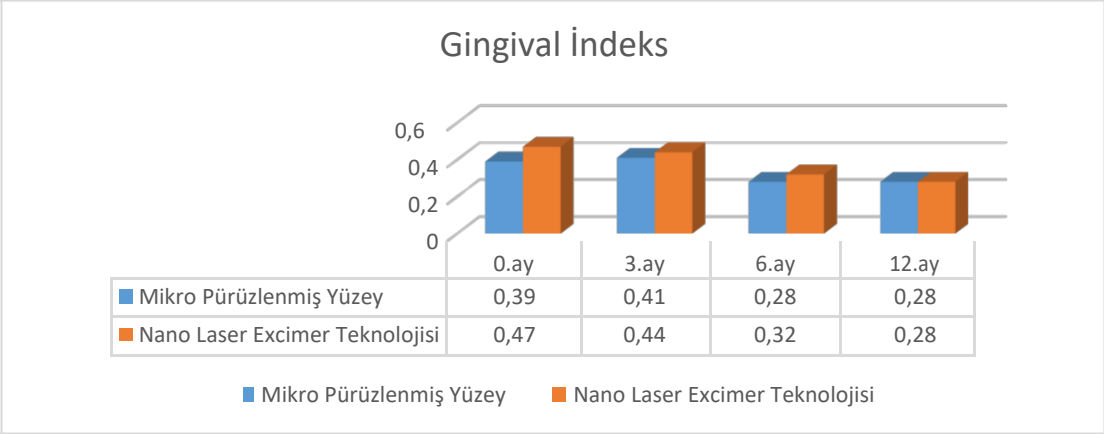

Figure-1: Histogram Plot of Distribution of Gingival Index Values by Groups and Time

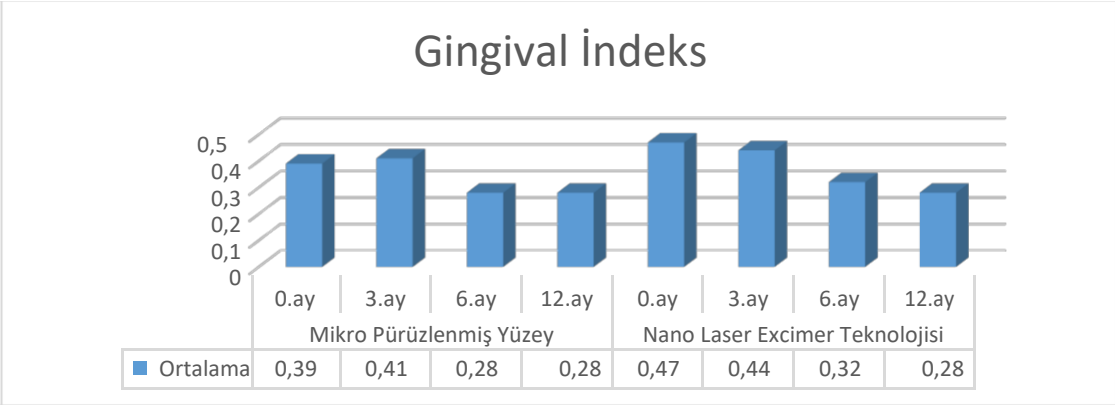

Figure-2: Distribution Graph of Gingival Index Values by Time in Groups

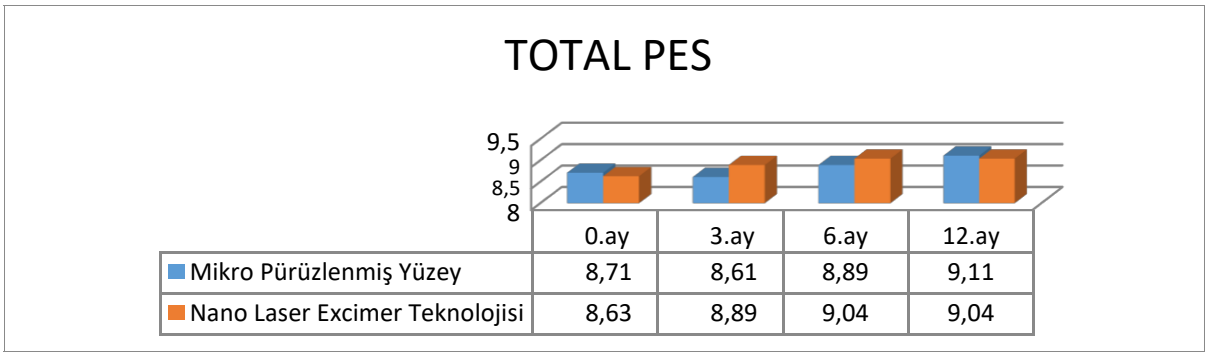

Figure-3: Distribution Graph of Total Pink Aesthetic Score Values by Groups and Time



Figure-4: Distribution Graph of Total Pink Aesthetics Score Values by Groups and Time

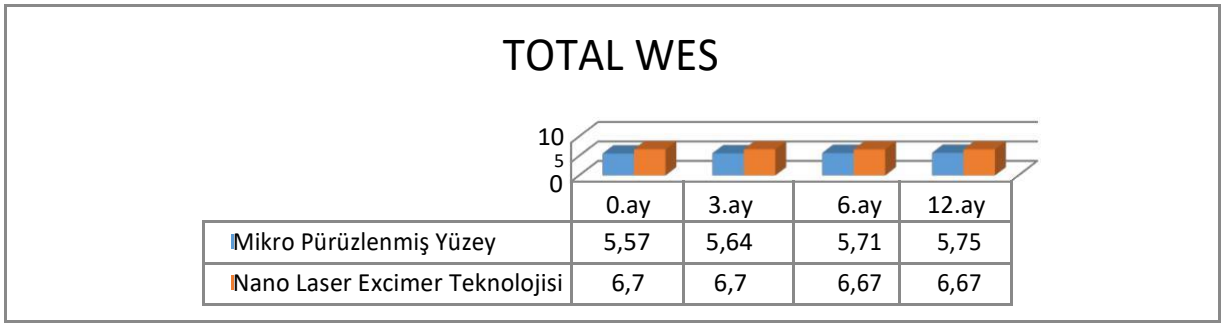

Figure-5: Distribution Graph of Total White Aesthetic Score Values by Groups and Time

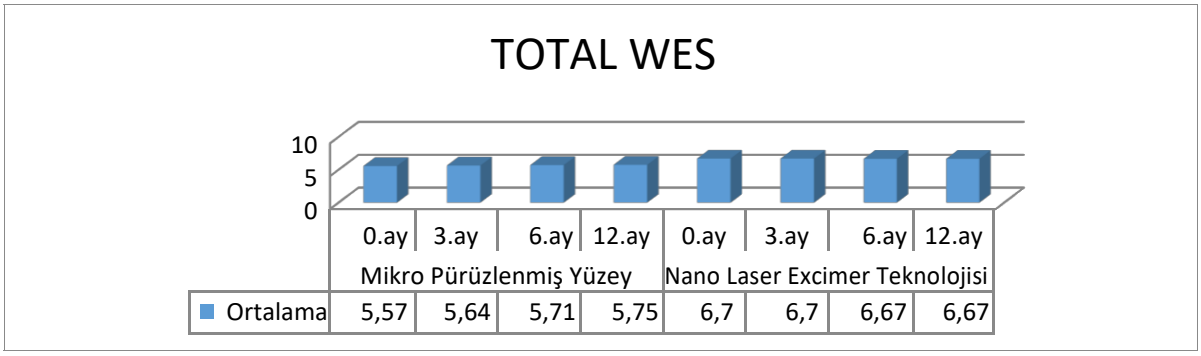

Figure-6: Distribution Graph of Total White Aesthetics Score Values by Groups and Time

This study was supported by the Dicle University Scientific Research Projects Coordinator with the project number DİŞ.17.025. We offer our thanks.

OP-28

The Effect Of The Number Of Missing Teeth On Mandibular Bone Density In Postmenopausal Osteoporosis Patients

Sinan Ateş[1], Belgin Gülsün[2]

ABSTRACT

Aim: The aim of this study was to investigate the effect of the number of missing teeth on mandibular bone density in postmenopausal osteoporosis patients.

Methods: Sixty female patients were enrolled in the study between the ages of 45-70 who had previously been diagnosed with postmenopausal osteoporosis. There are no diseases affecting bone metabolism in the patients. Two groups were formed from the patients. In the first group, 30 patients using bisphosphonates and in the second group, 30 patients who did not use bisphosphonates (control group) were included. The total number of teeth in the left mandibular quadrant was considered to be 8, and the number of missing teeth in patients was determined by subtracting the number of teeth from the corresponding quadrant from 8. All body Dual Energy X-ray Absorptiometry (DEXA) records were taken to calculate the bone mineral density of the mandible of the patients.

Results: While there was no correlation between the number of missing teeth and the mandible T score in the control group, there was a negative correlation between the number of missing teeth and the mandible T score in the bisphosphonate group ($p = 0.046$).

Conclusion: In patients using bisphosphonates, bone mineral density has increased as the number of teeth in the mouth increases. This situation was interpreted as the functioning of the teeth and the intake of bisphosphonate, increasing the bone mineral density by creating a synergistic effect on the bone.

Keywords: postmenopausal osteoporosis, tooth loss, bone mineral density,

INTRODUCTION

Tooth loss and osteoporosis are important public health problems in the elderly (1). Missing teeth may adversely affect dietary nutrient intake and cause systemic health to deteriorate. (2)

According to the data of the world health organization, osteoporosis is the second most common disease after cardiovascular diseases (3). Osteoporosis is a disease that can lead to weakening of the skeleton, breaking the bones during a mild strain or normal movement, and has become a subject of interest to physicians, patients and society in our world where the life span is gradually prolonged. This disease, which is usually not noticed until a fracture occurs, has high morbidity and even mortality, has many negative effects on quality of life, and is costly to treat. (4).

Bone density is one of the important factors affecting bone quality. Therefore, small changes in bone density can result in changes in bone strength. (5). Factors such as bone metabolism, mineral status of the skeleton, surgical procedures, occlusal forces transmitted by prostheses, muscle activities, the presence of teeth, bone thickness in the mandible, body mass index and the use of some drugs affect bone density. (6).

The preferred system for measuring bone density is the Dual Energy X-ray Absorptiometry (DEXA) system. This method, which directly measures bone density, is considered the gold standard.

The T score is generally used when evaluating bone mineral density. The T score is calculated by comparing the bone mineral density of the person with the bone mineral density of healthy young adults of the same sex. (7). If the T score is less than -2.5, osteoporosis is accepted, if it is between -1 and -2.5, osteopenia is considered normal if it is greater than -1 (8).

.

MATERIAL AND METHOD:

Selection of patients and creating groups

Our study was planned as a clinical study in which 60 postmenopausal osteoporosis patients between the ages of 45-75 will be included. 2 groups were created from 60 patients:

1. Group (patients using bisphosphonates): This group includes 30 patients.

2. Group (patients not using bisphosphonates): This group also includes 30 patients.

Our study was approved by Dicle University, Faculty of Dentistry Local Ethics Committee on 15.03.2017 with protocol number 2017/3.

Patients between the ages of 45-75 who had naturally entered menopause, had not had menstruation for at least one year, and were diagnosed with postmenopausal osteoporosis were included in the study. Patients with a history of trauma and reconstruction in the maxillofacial region, patients with cystic or tumoral lesions in the mandible, patients with a history of surgery in the mandible, patients with systemic disease affecting skeletal metabolism, and patients using drugs that affect skeletal metabolism were not included in the study. .

The total number of teeth in the left mandibular quadrant of the patients was accepted as 8 and the number of teeth in the relevant quadrant was removed from 8 and the number of missing teeth in the patients was determined.

Measuring bone mineral density in patients

Mandibular bone density of the patients was measured with DEXA (Hologic, Discovery QDR 4500 A model DEXA [Dual Energy X-ray Absorbtiometry]).

The patient was placed on her back during the shootings and the total body shooting protocol was applied. After the shooting, the region we wanted to analyze was selected from the left mandible symphysis to the angulus and the values to be analyzed were obtained.

Statistical analysis

In our study, mean, standard deviation, standard error, minimum and maximum values were given as descriptive statistics, and "Independent t-test", one of the statistical analysis methods, was used to compare the differences between the means of independent groups, and the "Chi-square test" for descriptive statistics (frequency, percentage calculation). "Correlation analysis" tests were used to evaluate the relationships between variables.

Descriptive statistics and analyzes were performed using R version 3.2.3 (2015-12-10), Copyright (C) 2015 The R Foundation for Statistical Computing free software computer package (the results for $p < 0.05$ were considered statistically significant).

RESULTS

It was observed that the age range of 30 patients in the first group, the control group, was between 50-70 and the average age was found to be 61.90 (SD = 6.266). In this group, it was observed that the age of entering menopause was between the ages of 30-54 (mean: 46.23) and the period after menopause ranged between 4-25 years (mean: 15.67) (Table-1).

It was determined that the age range of 30 patients in the bisphosphonate group in the second group was between 53-70 and their mean age was 64.57 (SD = 6.061). It was observed that the age of menopause in this group was between the ages of 29-57 (mean: 46.80) and the time elapsed after menopause was between 5-27 years (mean: 17.77) (Table-1).

When these results were interpreted, it was seen that both the age ranges of the patients in both groups, the ages of menopause and the period after menopause were almost similar and there was no significant difference between them.

While there was no correlation between the number of missing teeth and mandible T score in the control group, there was a negative correlation between the number of missing teeth and the mandible T score in the bisphosphonate group ($p = 0.046$). (Table-2).

DISCUSSION

Osteoporosis is the most common chronic disease of the bone, characterized by an increased fragility of the bone, associated with various factors such as menopause and aging. Although osteoporosis is seen in all age groups and both genders, it is more common in the elderly and women. The aging of the population due to the increase in life expectancy turns osteoporosis into a global problem. Today, it is estimated that more than 200 million people suffer from osteoporosis. According to the statistics of the International Osteoporosis Foundation, one out of every three women over the age of 50 and one in five men worldwide are expected to experience osteoporosis-related fractures during their lifetime. (9).

In the postmenopausal period, an increase in the incidence of fractures due to type I osteoporosis (postmenopausal osteoporosis) is observed due to estrogen deficiency. (10). In women, more bone loss due to menopause increases the risk of developing osteoporosis. Therefore, it has been reported that osteoporosis is mostly known as a female disease in the society and white Asian women are at higher risk of developing osteoporosis in the postmenopausal period. (11). Osteoporosis has a significant impact on dental practice. Osteoporosis plays a role in the prognosis of treatment in many processes, from prosthesis planning to periodontal health and oral surgical procedures. Therefore, all patients participating in our study are women with postmenopausal osteoporosis.

The increase in the elderly population both in our country and in the world has increased the number of elderly patients who come to dentists for various reasons. Especially with the advancing age, elderly patients frequently apply to dentists for the loss of teeth and correction of tooth loss with dental prostheses.

Loss of teeth is known to cause irreversible resorption in alveolar bone. (12). Although there are many studies examining bone density in the femoral head and lumbar bone in the loss of teeth, the number of studies examining the changes in bone density in the mandibular bone is limited. In our study, we examined how tooth loss affects mandibular bone density.

Krall et al. (1996) reported that systemic bone loss in postmenopausal women predisposes to tooth loss. (13).

Taguchi et al. (2004) stated that there is a relationship between tooth loss and low femoral head bone density in both men and women (14).

Slaidiana et al. (2011) reported that there was no correlation between the number of teeth and general bone density in their study on 79 women between the ages of 49-81 (15).

Henriques et al. (2011) found that more tooth loss was observed in postmenopausal women with low bone density. (16).

Grocholewich et al. (2011) reported that there was a negative relationship between femoral neck bone density and periodontal disease index in their study on 37 postmenopausal women aged 50-70 years (17).

Jang et al. (2015) examined the relationship between the number of teeth in the mouth and bone mineral density in a total of 7315 patients over the age of 50, 3364 males and 3951 postmenopausal females. As the number of teeth increased in postmenopausal women, a decrease was observed in the prevalence of osteoporosis. (18).

Rezazadeh et al. (2019) observed a negative correlation between the number of missing teeth and femoral bone density of patients in their study on 59 women older than 30 years. (19).

In our study, as the number of teeth increases in the bisphosphonate group, bone density increases. In this respect, our work supports the work of Jang, Krall, Taguchi, Rezazadeh and Grocholewich. On the other hand, the lack of correlation between the number of teeth and mandibular bone density in our control group supports the study of Slaidina et al.

CONCLUSION

In patients using bisphosphonates, as the number of teeth in the mouth increases, bone mineral density also increases. This situation was interpreted as functioning of the teeth and bisphosphonate intake increased bone mineral density by creating a synergistic effect on the bone.

REFERENCES

1) Gur A, Nas K, Kayhan O, Atay MB, Akyuz G, Sindal D, Gunduz OH. The relation between tooth loss and bone mass in postmenopausal osteoporotic women in Turkey: a multicenter study. Journal of bone and mineral metabolism. 2003; *21*(1): 43-47.
2) Shimazaki Y, Soh I, Saito T, Yamashita Y, Koga T, Miyazaki H, Takehara T. Influence of dentition status on physical disability, mental impairment, and mortality in institutionalized elderly people. *Journal of dental research*. 2001; *80*(1), 340-345.
3) Assessment of fracture risk and its application to screening for postmenopausal osteoporosis : report of a WHO study group [meeting held in Rome from 22 to 25 June 1992]. World Health Organization. 1994.
4) ArasılT.OsteroporozKonseyi.2002:5-6.
5) Seeman E, Martin TJ. Non-invasive techniques for the measurement of bone mineral. Baillieres Clin Endocrinol Metab. 1989 May;3(1):1-33.
6) Cakur B, Dagistan S, Sahin A, Harorli A, Yilmaz A. Reliability of mandibular cortical index and mandibular bone mineral density in the detection of osteoporotic women. Dentomaxillofac Radiol. 2009;38: 255–61.
7) Blake GM, Fogelman I. The role of DXA bone density scans in the diagnosis and treatment of osteoporosis. Postgraduate medical journal. 2007; 83(982):509-517.
8) Nakamoto T, Taguchi A, Ohtsuka M, Suei Y, Fujita M. Dental panoramic radiograph as a tool to detect postmenopausal women with low bone mineral density: untrained general dental practitioners diagnostic performance. Osteoporosis international. 2003; 14(8):659-64.
9) Sözen T, Özışık L, Başaran NÇ. An overview and management of osteoporosis. European journal of rheumatology. 2017; *4*(1):46

10) Riggs BL, Melton LJ III. Evidence for two distinct syndromes of involutional osteoporosis. Am J Med. *1983;76:899-901*.

11) Türkiye Endokrinoloji ve Metabolizma Derneği. Osteoporoz ve Metabolik KemikHastalıklarıTanıveTedavi Kılavuzu.11.Baskı.Ankara,2016; 11-14.

12) Bodic F, Hamel L, Lerouxel E, Baslé MF, Chappard D. Bone loss and teeth. *Joint Bone Spine*. 2005; *72*(3): 215-221.

13) Krall EA, Garcia RI, Dawson-Hughes B. Increased risk of tooth loss is related to bone loss at the whole body, hip, and spine. Calcified tissue international. 1996; *59*(6): 433-437.

14) Taguchi A, Fujiwara S, Masunari N, Suzuki G. Self-reported number of remaining teeth is associated with bone mineral density of the femoral neck, but not of the spine, in Japanese men and women. *Osteoporosis international*. 2004; *15*(10): 842-846.

15) Slaidina A, Soboleva U, Daukste I, Zvaigzne A, Lejnieks A. Postmenopausal osteoporosis and tooth loss. Stomatologija. 2011; *13*(3): 92-5.

16) Henriques PSG, Neto AMP. Association between tooth loss and bone mineral density in Brazilian postmenopausal women. Journal of clinical medicine research. 2011; *3*(3): 118.

17) Grocholewicz K, Bohatyrewicz A. Oral health and bone mineral density in postmenopausal women. Archives of Oral Biology. 2012; *57*(3): 245-251.

18) Jang KM, Cho KH, Lee SH, Han SB, Han KD, Kim YH. Tooth loss and bone mineral density in postmenopausal south korean women: The 2008–2010 korea national health and nutrition examination survey. Maturitas. 2015; *82*(4): 360-364.

19) Rezazadeh F, Emad S, Emad M. Relationship between bone mineral density and oral health status among iranian women. International journal of preventive medicine. 2019; *10*.

TABLES

Groups		n	Minimum	Maximum	Mean	Std. deviation
Control group (1st group)	**Age**	30	50	70	61,90	6,266
	Age of menopause	30	30	54	46,23	4,725
	Time after menopause	30	4	25	15,67	6,172
Bisphosphonate group (2nd group)	**Age**	30	53	70	64,57	6,061
	Age of menopause	30	29	57	46,80	4,802
	Time after menopause	30	5	27	17,77	5,793

Table 1: Age, age of menopause, time after menopause of the individuals included in the study (n: number of cases)

Groups			Mandible T score
Control	**Number of missing teeth**	Pearson Correlation	-0,145
		p	0,443
		n	30
Bisphosphonate	**Number of missing teeth**	Pearson Correlation	-0,367(*)
		p	**0,046**
		n	30

Table 2: Correlation of the number of missing teeth with the mandible T score (p <0.05 statistically significant, n: number of cases)

THANKS

The financial support of this study was provided by the Dicle University Scientific Research ProjectsCoordinator'sProjectNo.Diş17.002. Thank you for their support.

OP-35

HISTOPATHOLOGICAL INVESTIGATION OF THE EFFECTS OF DIFFERENT PIEZOSURGERY TOOLS ON TISSUES

Özgün Yıldırım[a], Mustafa Öztürk[b], Sibel Elif Gültekin[c]

A- Balgat Oral and Dental Health Center, Departmant of Oral and Maxillofacial Surgery, Turkey, ozgunyldrm89@gmail.com

B- Gazi University, Faculty Of Dentistry, Departmant of Oral and Maxillofacial Surgery, Turkey, msozturk@gazi.edu.tr

C- Gazi University, Faculty Of Dentistry, Departmant of Oral Pathology, Turkey, sibelg@gazi.edu.tr

Abstract

Objective: In this study, it is aimed to evaluate the effects of new and old generation piezosurgery instruments and conventional rotary hand tools on bone after osteotomy.

Material: In the study, 12 adult, New Zealand type white male rabbits weighing an average of 2.5 kg were used. In the parietal bones of the rabbits, bone defects with a diameter of 8 mm were created with the old generation piezosurgery tool (EMS Piezon Master Surgery, Switzerland) on the right front, the new generation piezosurgery tool (Acteon Piezotome Cube, France) on the left front and the conventional rotary hand tool (MIS W&H Physiodispanser, Austria) on the middle line behind these two defects. No material was placed in the defects, the defect area was washed only with sterile saline and left to the normal healing process with the blood clot formed. Experimental animals were sacrificed on the 7th and 21st days after the surgical procedure and evaluated histopathologically, histochemically and histomorphometrically.

Results: As a result of histopathological evaluation, it was determined that filling (bone and connective tissue) in the defect areas opened with new generation piezosurgery tools was higher in the short term follow up compared to other groups, but there was no significant difference between the groups in the mid term follow up.

Conclusions: Considering our results, it can be said histopathologically, histochemically,

histomorphometrically and statistically that new generation piezosurgery instruments give more positive results on bone healing.

Key Words: Piezoelectric surgery, bone healing, rabbit.

1.Introduction

Piezoelectric surgery technique; It is a technique designed to complete traditional methods for oral and maxillofacial surgery and to replace traditional methods in some cases, and provides safe and effective osteotomies by using piezoelectric ultrasonic vibrations that occur when electric current is passed over ceramics and crystals (1-3).

Piezoelectric surgery device; Due to its micrometric and selective cutting, it provides safe and sensitive osteotomies without creating any osteonecrotic damage. Since the device works only on mineralized tissues, it does not damage soft tissues such as mucous membranes and nerves and vessels that provide blood flow. The cutting action ends when the insert contacts the non-mineralized tissues. Since there is a close relationship between bones, nerves and blood vessels in oral and maxillofacial surgery, the use of piezosurgery can be a very effective method to minimize surgical trauma to neighboring tissues. This technique also minimizes the risk of temperature increase and marginal osteonecrosis associated with osteotomies, resulting in faster recovery (1-3).

In this study, it is aimed to evaluate the effects of new (Acteon Piezotome Cube, France) and old (EMS Piezon Master Surgery, Switzerland) generation piezosurgery instruments and conventional rotary hand tools (MIS W&H Physiodispanser, Austria) on bone after osteotomy.

2.Materials and Methods

In the study, 12 adult, New Zealand type white male rabbits, 3-4 months old, weighing 2.5 kg, were used. General anesthesia was provided to 12 rabbits included in the study by giving 25-35 mg / kg Ketamine HCl (Alfamine 10%, Alfasan) and 5 mg / kg Xylazine HCL (Basilazine 2%, Bavet) intramuscularly. All applied surgical procedures were performed under sterile surgical conditions. The skull of each animal was shaved and the relevant area was wiped with povidone iodine. In order to prevent possible contamination, in accordance with the surgical discipline, it is isolated with perforated compresses with only the operation area exposed. Following a sufficient period of time by looking at

respiratory, muscular movements and painful stimulus response, the skin incision was prepared approximately 2.5 cm long along the calvarian midline.

When the periost was reached, the bone was contacted and the incision was continued and the parietal bones were reached. Following the skin retraction, the old generation piezosurgery tool in the right parietal bone of each animal (EMS Piezon Master Surgery, Switzerland), the new generation piezosurgery tool in the left parietal bone (Acteon Piezotome Cube, France), behind these two defects is 8 mm bone with a middle rotary tool defects were opened under saline irrigation. After the defects were completed, the relevant area was washed with saline and cleaned. After bleeding control was achieved, the periosteum and the skin were closed primarily with 4/0 catgut sutures that could be resorbed and the wound area was wiped with povidone iodine. Experimental animals were taken into their cages following their respiratory and muscle movements and their follow-up started. The rabbits in the first group were sacrificed on the 7th postoperative day and the rabbits in the 2nd group on the 21st postoperative day with intramuscular high dose ketamine injection.

3. Results

It was found that the filling (bone and connective tissue) in the defect areas opened with the new generation piezosurgery tools in the short-term follow-up was higher than the other groups, but there was no significant difference between the groups in the mid-term follow-up.

In both experimental groups, it was seen that the collagen from the 7th day to the 21st day became mature dens bands starting from the thin short fibrillar structure. On the 7th day, the extracellular matrix and thin fibrillar collagen were stained in light blue, and the myofibroblast and young fibroblasts were red. It was observed that the blue-dark blue, mature bone and bone sequesters of the new bone formed on the 21st day were stained in red. There was no difference between the experimental and control groups in terms of staining pattern.

According to the filling measurements made on the 7th and 21st days of the older generation piezosurgery tool group, a statistically significant difference was found between some parameters ($p < 0.05$). Accordingly, the average of the new bone measurements on the 7th day is less than the 21st day; The average of the sequence measurements of the 7th day is higher than the 21st day; The average of the fibrin measurements of the 7th day is higher than the 21st day; The average of the free space measurements of the 7th day is higher than the 21st day; The average of the full percent measurements

of the 7th day is less than the 21st day; It is seen that the average of the blank percent measurements of the 7th day is higher than the 21st day.

According to the filling measurements performed on the 7th and 21st days of the control group, there was a statistically significant difference between some parameters ($p < 0.05$). Accordingly, the average of the fibrin measurements of the 7th day is higher than the 21st day; The average of the free space measurements of the 7th day is higher than the 21st day; The average of the full percent measurements of the 7th day is less than the 21st day; It is seen that the average of the blank percent measurements of the 7th day is higher than the 21st day.

A statistically significant difference was found between some parameters according to the filling measurements performed on the 7th and 21st days of the new generation piezosurgery tool group ($p < 0.05$). Accordingly, the average of the fibrin measurements of the 7th day is higher than the 21st day; The average of the total area measurements of the 7th day is higher than the 21st day; It is seen that the average of the free area measurements of the 7th day is higher than the 21st day.

According to the results of the analyzes, it was found that there was a statistically significant difference between the mean of the new bone and total area measurements measured with EP, K and YP on the 7th day ($p < 0.05$). According to the results of the analysis, it was seen that the group that created the difference for the new bone originated from EP. Accordingly, it is seen that the average of new bone measurements of EP is lower than the average of new bone measurements of K and the average of new bone measurements of EP is lower than the average of new bone measurements of YP. According to the results of the analysis, it is seen that the difference in the total area is between the average of EP's total area measurements and the average of K's total area measurements and K's total area score average is higher than the EP.

According to the results of the analysis, it was determined that there was a statistically significant difference between the medians of the sequester measurements measured with EP, K and YP on the 7th day ($p < 0.05$). According to the results of the analysis, it was seen that the group that created the difference originated from EP. Accordingly, the median of sequester measurements of EP is higher than the median of sequester measurements of K, and the median of sequester measurement of EP is higher than the median of sequester measurements of YP.

4. Discussion

An experimental study by Alexandre Anesi et al. Investigated the effect of two different piezosurgery instruments (Piezosurgery® Medical-PM and Piezosurgery® Plus-PP) and a conventional rotary handpiece (RO) on bone tissue. Bone defects of 1 cm length opened in the skulls of 16 rabbits were evaluated histopathologically after sacrification of the animals after 15 days. It has been determined that the cut lines created using PP and PM have a higher recovery potential compared to the lines created using RO, but there is not much difference although PP is a more powerful device than PM (4).

In a study by Li Ma et al., they aimed to compare bone healing in experimental osteotomies in which piezosurgery and two different saw blades were applied in a rabbit model. In this study, 16 rabbits were randomly divided into four groups to accommodate one, two, three and five week observation periods. In all animals, four osteotomy lines were made on the left and right nasal bone using a conventional saw blade, a new saw blade, and piezosurgery. Bone healing started one week later in all three osteotomy techniques. The most prominent new bone formation occurred between two and third weeks, and it was found that piezoelectric surgery tended to have a faster bone formation and remodeling tendency. However, it was noted that there was no significant difference between the three modalities (5).

Hoigne et al. Stated that wound healing and bone consolidation occur smoothly after piezoelectric surgery, and the healing time was shorter than the traditional healing time. Because the technique is tissue selective, they thought it could have a positive effect on the healing process by allowing less removal of the periosteum and less pull of soft tissues for minimally invasive surgery (6).

In a study by Jônatas Caldeira Esteves and colleagues, they aimed to compare the bone healing dynamics of piezosurgery and traditional drills after osteotomies. 110 mice were divided into two subgroups, 55 mice in one group, and 2 different diameter defects were opened with two different instruments in their tibia. Animals were sacrificed on the 3rd, 7th, 14th, 30th and 60th days for histological, histomorphometric, immunohistochemical and molecular analysis. As a result, histologically and histomorphometrically; The newly formed bone observed at the end of the 30th day was found to be almost similar in both groups, except that it was slightly higher in the piezosurgery group (7).

In an in vivo experimental study by Vercelotti et al. on dog mandibula, the wound healing response after piezoelectric surgery device, osteotomies with diamond and carbide burs was evaluated. Bone loss was observed at the end of the 14th day in the areas where osteotomy was performed with diamond and carbide burs, while an increase in bone level was observed in the areas where osteotomy was performed with the piezoelectric surgery device. Osteotomies performed with all three methods showed an increase in bone level at the end of the 28th day, and bone loss was observed in the osteotomy sites made with diamond and carbide burs at the end of the 56th day, while an increase in the bone level was observed in the osteotomy sites made with piezoelectric surgical tool. The results of the study showed that bone healing response after osteotomies performed with piezoelectric surgery tool is better compared to diamond or carbide burs (8).

It seems that the work of Alexadre Anesi et al. (4), Li Ma et al. (5), Hoigne et al. (6), Esteves et al. (7), Vercelotti et al. in our study, bone healing was higher in piezoelectric surgery tools on the 7th day, especially in the new generation piezoelectric surgery group; however, there was no significant difference between the groups on the 21st day. Considering the results obtained from the studies, it is statistically understood that the effect of osteotomies performed with piezoelectric surgery tools on recovery in the early period is more successful than conventional methods, but different piezoelectric surgery tools do not show much superiority against each other. New generation piezosurgery tools were found to be more successful in the early period than the older generations; however, this was not statistically significant. With this finding, piezoelectric surgery tools were proved once again in terms of recovery time compared to traditional tools.

5. Conclusion

Our study is thought to be the first study to be tested by opening round-shaped defects in rabbit skull with new generation piezosurgery instruments. Considering our results, it can be said histopathologically, histochemically, histomorphometrically and statistically that new generation piezosurgery instruments give more positive results on bone healing. Although no statistically significant results were obtained when compared to the older generation piezosurgery instruments, statistically significant results were obtained compared to conventional rotary instruments. We think that our findings should be supported by experimental and clinical new studies.

6. Additional Info

We would like to thank the Gazi University Scientific Research Project for supporting this project (the code number is 03/2019-05) financially.

7. References

1. Schaller BJ, Gruber R, Merten HA, Kruschat T, Schliephake H, Buchfelder M, Ludwig HC. (2005). Piezoelectric bone surgery: a revolutionary technique for minimally invasive surgery in cranial base and spinal surgery? Technical note. *Neurosurgery,* 57, 410-414.
2. Gruber RM, Kramer FJ, Merten HA, Schliephake H. (2005). Ultrasonic surgery-an alternative way in orthognathic surgery of the mandible. A pilot study. *International Journal of Oral and Maxillofacial Surgery,* 34, 590-593.
3. Vercellotti T, Nevins ML, Kim DM, Nevins M, Wada K, Schenk RK, Fiorellini JP. (2005). Osseous response following resective therapy with piezosurgery. *International Journal of Periodontics & Restorative Dentistry,* 25, 543-549.
4. Alexandre A, Marzia F, Francesco C, Roberta S, Michele B, Alessandro R, Luigi C, Carla P. (2018). Structural and ultrastructural analyses of bone regeneration in rabbit cranial osteotomy: Piezosurgery versus traditional osteotomes. *Journal of Cranio-Maxillo-Facial Surgery,* 46, 107-118.
5. Li M, Stefan S, Xi LL, Urs AS, Niklaus PL. (2013). Healing of osteotomy sites applying either piezosurgery or two conventional saw blades: a pilot study in rabbits. *International Orthopaedics (SICOT),* 37, 1597–1603.
6. Hoigne DJ, Stübinger S, Von Kaenel O, Shamdasani S, Hasenboehler P. (2006). Piezoelectric osteotomy in hand surgery: first experiences with a new technique. *BMC Musculoskeletal Disorders,* 7, 36.
7. Jônatas CE, Elcio MJ, Ana PSF, Fernanda RGR, Rosemary AM, Katarzyna W, Giuseppe I. (2013). Dynamics of bone healing after osteotomy with piezosurgery or conventional drilling – histomorphometrical, immunohistochemical, and molecular analysis. *Esteves et al. Journal of Translational Medicine,* 11, 221.
8. Vercellotti T, Nevins ML, Kim DM, Nevins M, Wada K, Schenk RK, Fiorellini JP. (2005). Osseous response following resective therapy with piezosurgery. *The International Journal of Periodontics and Restorative,* 25, 543-549.

OP-37

INVESTIGATION OF HPV 13 AND 32 IN PATIENTS WITH SUSPECTED ORAL FOCAL HYPERPLASIA (FEH)

Muammer Osman Köksal[a]

A- Department of Medical Microbiology, Istanbul Faculty of Medicine, Istanbul University, Istanbul, Turkey, muammerosmankoksal@istanbul.edu.tr

Abstract

Objectives

Focal epithelial hyperplasia (FEH) or Heck's disease is a rare disease caused by human papilloma virus (HPV) type 13 or 32 and was first described in 1965 from multiple soft papular and nodular eruptions on the oral mucosa of Navajo Xavante Indian and Alaska Eskimo children. The lesions are predominantly found on the lower lip, buccal mucosa and tongue. It was aimed to investigate HPV 13 and 32, which are the agents of oral fecal hyperplasia (OFH) in patients with negative oral mucosal HPV genotyping results.

Materials and Methods

Biopsies of seven individuals sent from various departments of our hospital were included in our study. Genital HPV genotyping was performed by the manufacturer's instructions. Negative samples for genital HPV types were sequenced using A6 / A8 PCR primers for genotyping of HPV 13 and HPV 32.

Results

Sequence reactions were performed in seven patients with negative results in genital HPV test. 5 of them showed positive results for HPV 13 and HPV 32. Two (40%) of these patients had HPV 32 positive results, where as 3 (60%) had HPV 13 positive results.

Conclusion

Data on the general prevalence of HPV 13 and 32 are limited due to the fact that the disease is usually self-regressing and benign. However, disease prognosis and viral pathogenesis still need to be investigated. HPV 13 and 32 should be considered in addition to genital HPV types in oral papillomatous lesions.

Keywords: Focal epithelial hyperplasia, Heck disease, HPV 13, HPV 32.

Introduction

Focal epithelial hyperplasia (FEH), also known as Heck's disease, is a rare benign lesion of the oral mucosa created by human papillomavirus (HPV) type 13 or 32 (1,2). The two HPV types have been observed from both keratinized and non-keratinized surfaces. While HPV 32 was more commonly observed among older patients, HPV 13 played an equal role in the development of lesions in both younger and older patients. FEH occurs in certain geographic regions (e.g. North, Central and some parts of South America and Africa) and several predisposing factors, such as genetic background, poor oral hygiene, and low socioeconomic status, play an important role in the development of the disease. Lesions are found mainly on the lower labial and buccal mucosa, and less frequently on the tongue.

Such a rare benign lesion in the oral mucosa can easily be confused with other oral cavity lesions such as Fordyce spots, oral mucosal involvement of Crohn's disease, mucosal neuromas in multiple endocrine neoplasia type 2B, fibroepithelial papules in multiple hamartoma syndrome (Cowden disease) and HPV-associated lesion which are condyloma accuminata or verruca vulvaris. These conditions should be considered in differential diagnosis. Treatment options for FEH include surgical removal of the lesion, laser excision, electrocautery, cryotherapy, and the use of topical agents such as imicuimod, retinoic acid, or trichloroacetic acid. However, treatment is not always necessary as majority of the infections are asymptomatic and often undergo spontaneous regression without any tendency for malignant transformation (3,4). In our study, we aimed to identify HPV type 13 and 32 from oral papillomatous lesions sent to our department for HPV genotyping.

Materials and Methods

Of the individuals whose samples were sent for Genito-oral HPV genotyping from various departments of our hospital. A total of 7 patients, 3 of whom were female and 4 of whom were male, were enrolled in the study. For HPV detection, viral DNA extraction from the biopsy material was performed using GeneAll Ribospin vRD Viral RNA/DNA Extraction Kit (GeneAll Biotechnology Co., Seoul, Korea) according to the manufacturer’s instruction. Extracted DNA sample was subjected to real-time polymerase chain reaction (PCR) with Anyplex II H28 kit (Seegene, Seoul, South Korea) according to manufacturer's instructions. 5 µl DNA was used in each of the two 20 µl reaction mixtures together with primer set A or B on the CFX96 real-time PCR instrument (Bio-Rad, Hercules, CA, USA).

H28 can semiquantitatively distinguish 28 HPV genotypes in two reactions (High-risk types HPV 16, 18, 26, 31, 33, 35, 39, 45, 51-53, 56, 58, 59, 66, 68, 69, 73, 82 and Low-risk types 6, 11, 40, 42-44, 54, 61, 70). The test results were found to be negative for 28 HPV types.

Patients whose test results were negative for 28 HPV types were included in the study to investigate HPV 13 and 32. Tissues were cut and DNA isolation was carried out using a QIAamp DNA mini kit

(Qiagen, Hilden, Germany) according to the manufacturer's instructions. Screening the DNA samples for HPV sequences was performed using the A6/A8 PCR primers as described previously (5). PCR products were purified using the Qiagen PCR purification kit and then used in the sequencing PCR reaction performed with the A6 primer. Products of the PCR reaction were then purified with the DyeEx spin kit and sequenced on an ABI Prism sequencer.

Results

Of the seven samples, five (71.5%) showed positive results for FEH-related HPV types. Two of the individuals whom positivity was detected were under the age of 18 and one of these individuals was male and the other one was female. Of the positive individuals, two (40%) had HPV 32 and three (60%) had HPV 13.

Discussion

FEH or Heck disease is a rare painless, benign mucosal disease of the oral mucosa that occurs mostly in certain ethnic groups and geographic regions. HPV type 13 and 32 are strongly associated in the aetiology of FEH. It predominantly affects the labial, lingual and buccal mucosa, but is also reported in the gums and palate. It was first described in a Native American population in 1965 (6) and has since been reported in certain ethnic groups, such as Native Americans and Eskimos.

Its true frequency is unknown due to its non-symptom and regressive character. FEH is mostly childhood and adolescent disease and is generally associated with poor socioeconomic status (7). Recent studies have found a significant association between FEH and human leukocyte antigen (HLA) - DR4 (DRB1 * 0404), an allele that is relatively common in Native American populations. These studies have reported that the HLA-DR4 major histocompatibility complex II molecule cannot bind to the proteins of HPV 13 or -32 proteins, and may increase the susceptibility to the infection created by these HPV subtypes and the risk of FEH (8).

In addition to genetic predisposition, overcrowding, poor hygiene, malnutrition, proximity of the region to the source of contamination and continuous exposure are other predisposing factors (9). In histological examination, superficial keratinocytes with mitozoid bodies, including epithelial hyperplasia, acanthosis and coilotic changes, are observed. Standard tests used to identify low and high risk HPV subtypes do not include HPV 13 or 32. FEH is a benign condition that typically regresses spontaneously in an average of 18 months, but some cases have shown persistent disease for many years (10). There is no known malignant potential for HPV 13 or -32. However, in recent studies,

it has been shown that they are found in the oral mucosa with other HPV types, and it has been reported that other HPV types may affect the occurrence and progression of the disease (9).

HPV genotypes have been associated and detected in FEH lesions. HPV DNA was found in 50-100% of FEH lesions. FEH is a benign disease that sometimes heals spontaneously. Treatment may be required for aesthetic reasons or intervention to occlusion, and lesions may need to be removed. Recurrence of FEH lesions may occur after spontaneous regression or the subsequent treatment. The disease has no malignant potential. There are reports about Heck's disease in Turkey (7, 11, 12). Studies are generally in the form of case reports. When deciding on the diagnosis of FEH, it is important to exclude the types of warts associated with perinatal HPV exposure and less commonly with sexual abuse. Clinicians may refer to the diagnosis of FEH in case there is a family history of similar lesions or when the patient is a member of a high-risk population. Papillomas have been reported to regress without treatment within 12 to 18 months (10). In oral papillomatous lesions, HPV 13 and 32 should also be considered together with genital HPV types. In addition, the study of these two types seems to be important in terms of distinguishing forensic cases, especially since lesions are observed in children.

References

1. Archard HO, Heck JW, Stanley HR (1965) Focal epithelial hyperplasia: an unusual mucosal lesion found in Indian children. *Oral Surg* 20: 201–212

2. Henke RP, Guerin-Revershon I, Milde-Langosch K et al. (1989) In situ detection of human papillomavirustypes 13 and 32 in focal epithelial hyperplasia of the oral mucosa. *J Oral Pathol Med;* 18: 419–421

3.Said AK, Leao JC, Fedele S et al (2013). Focal epithelial hyperplasia — an update. *J Oral Pathol Med*; 42: 435–42.

4.de Castro LA, de Castro JG, da Cruz AD, et al (2016). Focal epithelial hyperplasia (Heck's Disease) in a 57-year-old Brazilian patient: a case report and literature review. *J Clin Med Res* 8: 346–50.

5. Wieland U, Ritzkowsky A, Stoltidis M, et al (2000) Communication: papillomavirus DNA in basal cell carcinomas of immunocompetent patients: an accidental association? *J Invest Dermatol*. 115(1):124-128.

6. Archard HO, Heck JW, Stanley HR (1965). Focal epithelial hyperplasia: an unusual oral mucosal lesion found in Indian children. *Oral Surg Oral Med Oral Pathol*; 20: 201–212.

7. Akoğlu G, Metin A, Ceylan GG et al (2015). Focal epithelial hyperplasia associated with human papillomavirus 13 and common human leukocyte antigen alleles in a Turkish family. *Int J Dermatol*. 54(2):174-178.

8. Garcia-Corona C, Vega-Memije E, Mosqueda-Taylor A et al (2004). Association of HLA-DR4 (DRB1*0404) with human papillomavirus infection in patients with focal epithelial hyperplasia. *Arch Dermatol* 140:1227– 1231.

9- Jiménez Aguilar SM, Rodríguez DL, Muñoz Estrada VF et al (2019). Great diversity of oncogenic human papillomaviruses is revealed in an outbreak of multifocal epithelial hyperplasia. *J Am Acad Dermatol*. S0190-9622(19)33318-3.

10. Bennett LK, Hinshaw M (2009). Heck's disease: diagnosis and susceptibility. *Pediatr Dermatol* 26: 87–89.

11.Ozden B, Gunduz K, Gunhan O et al (2011). A Case Report of Focal Epithelial Hyperplasia (Heck's disease) with PCR Detection of Human Papillomavirus. *J Maxillofac Oral Surg*. 10(4): 357-360.

12. Gökahmetoğlu S, Ferahbaş A, Canöz Ö (2014). Focal epithelial hyperplasia in a Turkish family. *Infez Med*. 22(4): 322-325.

Figure 1: Solitary buccal nodule, sessile, measuring approximately 25 mm on its largest diameter, with smooth and lobulated surface, similar in colour to the surrounding mucosa.

OP- 39

THE EXAMINATION OF THE PREVALENCE OF PRIMARY OSTIUM MAXILLARIS, ACCESSORY OSTIUM MAXILLARIS AND SCHNEIDERIAN MEMBRANE BY CONE BEAM COMPUTED TOMOGRAPHY

Hacer Eberliköse[1], hcrulutuerk@gmail.com

Yeliz Kılınç[1],

Orhan Gülen[2],

Derviş Yılmaz[1]

[1]Gazi University, Faculty of Dentistry,Department of Maxillofacial Surgery, Ankara
[2]Gazi University,Faculty of Dentistry, Department of Oral Pathology

Objective: Due to its anatomical localization of the maxillary sinus occupies important place in maxilllofacial surgery and dentistry. Dentists and maxillofacial surgeons encounter complications, from time to time, arising from the anatomical proximity of the procedures such as posterior maxillary tooth extraction, Caldwell-Luc operations, Le-Fort surgeries and implant operations. Having knowledge about the anatomy and variations of the related region is important. This situation reduces the potential risk factors and be able to perform surgical procedures in a safer way.

Materials-Methods: In our study, cone- beam computed tomography images of 385 patients were selected from a database of a dental imaging center with the indication of dental implant treatment planning, pre-orthognatic analysis, embedded dental operations, and evaluation of cysts and neoplasms were retrospectively analyzed. Anatomical structures and pathological changes in maxillary sinus region bilaterally of 385 patients over 18 years of age were evaluated. Demographic data, status of dentition, Primary Ostium Maxillaris, Accessory Maxillary Ostium and Schneiderian Membrane thickness were evaluated.

Results: Based on the findings of our study conducted in a statistically highly reliable population(770 Maxillary Sinus), various factors have been found to affect maxillary sinus physiology.

Conclusion: The results of our study shows that radiographical signs indicating a potential maxillary sinusitis should be evaluated carefully, the results supports the opinion that many postoperative complications can be avoided.

Keywords: Primery Ostium Maxillaris, Schneiderian Membrane, Accessory Maxillary Ostium

Introduction

Due to its anatomical localization, the maxillary sinus has an important role in maxillofacial surgery. A piece of good knowledge about the maxillary sinus region is very important for the clinician to minimize the risk of complications during surgical operations such as

Le-Fort I osteotomy, Caldwell-Luc operation, maxillary sinus-related tooth extraction, and dental implant surgery[1, 2]. Inflammatory diseases or structural changes in the maxillary sinus region have a serious impact on the surgical success.The so-called osteomeatal complex (OMC) is the most

important region in the formation of sinus diseases. Osteomeatal complex is the name given to the whole anatomical structures in the middle meatus on the ethmoid bone[3]. Uncinate process, hiatus semilunaris, bulla ethmoidalis, ethmoid infindubulum, primary ostium maxillaris, middle turbinate and frontal recesses constitute the osteomeatal complex [3]. An obstruction in any of the passages, primary ostium maxillaris, ethmoid infundibulum, and hiatus semilunaris in the OMC could effect maxillary sinus physiology[4]. Mantoani et al. stated that a maxillary sinus is healthy when the mucous outflow is normal, mucociliary clearance is efficient and the ostium is patent[5].For the better assessment of this critical region, cone-beam computed tomography (CBCT) images should be evaluated carefully in the daily routine. It is thought that a detailed examination of the related area with CBCT before surgery would make it possible to avoid intraoperative and postoperative complications.

Material and Metod

In our study, CBCT images of 385 patients were selected from a database of a dental imaging center with the indication of dental implant treatment planning, pre-orthognatic analysis, embedded dental operations, and evaluation of cysts and neoplasms were retrospectively analyzed. Anatomical structures and pathological changes in maxillary sinus region bilaterally of 385 patients over 18 years of age were evaluated. Demographic data, status of dentition, Primary Ostium Maxillaris,Accessory Maxillary Ostium and Schneiderian Membrane thickness were evaluated. This study protocol was approved by the Ethical Review Board of Gazi University and followed the Declaration of Helsinki.

Primary ostium maxillaris and Accessory ostium maxillaris evaluations were made in coronal slices of the CBCT. The height of the primer ostium was measured as the distance

between the the uncinate process and the deepest sinus floor point (Figure 1). The accessory ostium height was measured from the center of the maxillary sinus ostium, and the deepest point of the maxillary sinus in millimetres. Also the ostia patency were measured in millimetres (Figure 2).

Schneiderian membrane thickness was evaluated from the sinus maxillaris floor to the thickest point of the membrane in the coronal slices of the CBCT. Its thickness has been studied and compared in axial, coronal, and panoramic sections. According to Soikonnen & Ainoma Schneiderian membranes thicker than 5mm has been accepted as pathological

Evaluation criteria are given in (Table 1).

Results

The images included in the study were 770 maxillary sinus CBCT images taken from individuals aged 18 to 79 years . 63% (n:242) of the images were taken from females and 37% (n:143) of the images were taken from males.

While POM was observed in approximately 90% of the 436 sinuses examined in female patients, it was not observed in 10%. POM was observed in approximately 83% of 236 sinuses examined in male patients (Table 2). The effect of age on the height and diameter of POM was found to be statistically significant.

The average Schneiderian membrane thickness in male patients is 8.597 ± 9.3266 mm, and in female patients 5.506 ± 6.6944 mm . In approximately 49% of the 286 sinuses examined in male patients, the Schneiderian membrane is thinner than 5 mm, 20% it is between 5-10 mm, in 12% it is between 10-15 mm, in 6% of patients it is 15-20 mm thick, and in 13% Schneiderian membrane is thicker than 20 mm. In approximately 68% of 484 maxillary sinuses examined in female patients, the Schneiderian membrane is thinner than 5 mm, in 13% it is between 5-10 mm, in 7% it is between 10-15 mm, in 6% of patients it is 15-20 mm thick, and in 5% Schneiderian membrane is thicker than 20 mm (Table 3). On the other hand, Schneiderian membrane thickness was higher in male patients compared to female patients. The thickest membrane height with 9.431 mm was determined at the age of 65 years.

Membrane thickness was found to be higher (7.315 mm) in edentulous patients. There was a statistically positive relationship between age and membrane thickness.

In addition to this Schneiderian membrane thickness is severe in the absence of POM. There was a significant relationship with the thickness of Schneiderian membrane and the presence of POM. The membrane thickness increases, when the presence of POM decreases. According to our findings, in the presence of AOM, the Schneiderian membrane is thicker. There was also a statistically significant relationship with the height of AOM and Schneiderian membrane thickness.

Unlike POM , no significant relationship was found between the presence of AOM and gender ($p = 0.702$). While the presence of AOM was observed in approximately 20% of male patients, it was observed at a rate of 19% in female patients (Table 4).In our study, elevation of AOM was higher in male patients compared to female patients. According to the z test, there is a statistically significant difference between gender and AOM height. There is a significant positive relationship between POM and AOM height. As the POM height increases, so does the AOM height. In terms of width there is no meaningful relationship

Discussion

Due to its proximity to the oral cavity the maxillary sinus is an important anatomical structure in terms of complications during minor and major surgical procedures. The position of the maxillary sinus is especially important in surgical applications of dental implants, which are common treatment options nowadays. Detailed examination of computed tomography images can provide surgical convenience. There are many studies in literature in which the relationship between POM and sinus function are evaluated[6-9] Due to the increase in surgical procedure involving the sinus area the presence of accessory ostium maxillaris has gained importance [10]. Therefore, the aim of our study is to determine POM patency and localization in the sinus maxillaris region, as well as to examine the prevelance of accessory ostia in Turkish population. At the same time the thickness of the Schneiderian membrane was measured.

Souza et al. reported that localization of POM together with maxillary sinus topography is important for maxillary inflammation[9]. Carmeli et al. stated that disruptions in sinus drainage increased the risk of failure of dental implant application in the posterior maxilla[6]. In the mentioned studies, anatomical variations in the maxillary sinus and AOM have been associated with POM.

In many studies in the literature, the position of the POM in vertical direction was determined relative to the meatus[6, 11, 12]. In our study, millimetric measurement were made up to the uncinate process based on the sinus floor.

The ostium opening was generally described as open or narrowed in previous studies[10, 12], in our study the ostium diameter was measured. The reason for measuring in millimeters is to discuss whether the diameter of POM affects SM thickening and other pathological conditions. Shanbag et al.[12], Carmeli et al. [6, 7]found the prevalence of open POM as 73.5% to 89.2% in their studies . In the study conducted by Yeung et al., only 3.5% of the patients did not have POM[7]. The presence of POM is one of the most important factors in maintaining the healthy function of the maxillary sinus. The prevalence of POM examined in our study was found to be 87% among all samples. The prevalence of POM patency found in our study was found to be compatible with the prevalence of Carmeli et al. in Israeli society.

Shangbang et al. also stated that in Iranian society POM contracts with a thickened SM[12]. In our study, the average SM thickness in the presence of POM is 5.149 mm, while the average thickness in its absence is 16.976 mm. This relationship confirms the thought that sinus drainage is impaired in the absence of POM and therefore SM thickening occurs. Impaired sinus function can increase the risk of postoperative maxillary sinus infection [12].

In our study, it was found that a higher rate of POM patency was observed in female patients compared to male patients. Accordingly, a statistically significant effect of gender on the presence of POM was found (90.1%, 82.5%, p = 0.003). The reason for this can be explained by the fact that female patients have healthier sinus maxillaries than male patients. The lower smoking frequency of female patients compared to male patients may be attributed to this [13]. Our study showed similar results to that of Yeung et al. in Chinese society (female patient 184; male patient 64).

In our study, the average width of POM measured in female patients was 1.447 mm, while this width in male patients was similarly 1.457 mm. The gender factor was found to be statistically significant on the presence of POM, but not affected by its diameter. Yeung et al. classified the POM by shape rather than measuring the diameter of the POM [10].

Previous studies have shown that the majority of POM is in the upper 1/3 of the medial sinus wall, less in the middle part, and no POM was detected in the lower part[9, 14]. May et al . reported in the American population that POM was found 40 mm above the sinus floor [14].

In a study by Hwang et al. in the South Korean population, they found that POM was localized at 29.9mm ± 5.1mm above the palatal bone without gender discrimination [15]. In our study, the mean height was determined as 31.415mm in female patients. In male patients the height was found 32,945 mm. It is thought that the difference between the outcomes may result from the difference in anatomical formations determined for measurement. According to the data obtained, in the Turkish population, POMs are found in the upper third of the medial wall of the maxillary sinus. These results are consistent with the study conducted by Akay et al. in the Turkish population [11]. In our study POM height was measured from the deepest point of the sinus floor, however, in further studies, the measurements can also be made from the alveolar crest for a easier orientation of the clinician. While the effect of gender on POM height was not determined in the study of Hwang et al [15]. It was observed that gender had a significant effect on POM height inour study . This suggests that the maxillary sinus volume may be higher in male patients. In a previous study, the average sinus maxillaris volume was found to be 24mm^3 in men and 16mm^3 in women[16, 17].

Yeung et al. reported that obstructive POM is more common when there is a pathological increase in the thickness of the Schneiderian membrane [10]. Carmelli et al. found obstructed POM in thickened Schneiderian membranes in their study [6]. Guo et al. reported that the POM diameter also narrowed with the increase of Schneiderian membrane thickness [18]. Shanbag et al. found that there is more frequent contraction in POM at Schneiderian membrane thicknesses greater than 10 mm[12]. In our

study, a significant and positive relationship was found between POM diameter and Schneiderian membrane thickness . In this case, the POM reached its maximum in the presence of a Schneiderian membrane thickness more than 20mm. According to the findings we obtained in our study, narrowing or widening of the POM diameter, unlike its physiological width, caused similar effects on SM. In addition to this when the thickness of the Schneiderian membrane increases, the presence of POM and AOM decreases statistically. This information suggests that sinus drainage disorder occurs together with SM thickening.

In our study, thickened mucosal membrane was detected in 39% of the maxillary sinuses. Similarly, in the study of Pothikun et al. SM thickening was found in 29% of the maxillary sinuses [19]. We think that the reason for the difference between the values may be related to the sample size, the population and the sensitivity of the dental volumetric computed tomography used in the study.

Conclusion

In the light of all these findings and information, we anticipate that a detailed and conscious examination of the surgical area with tomography will contribute to the prediction of possible complications and therefore, by taking these into consideration during the treatment planning phase, it may ensure that possible complications can be avoided.

Figure 1: POM height measurement, in coronal slices of the CBCT

Figure 2:Accessoy Ostium Maxillaris presence

Table 1: Evalution of the Schneiderian membrane thickness

1.	≤5mm
2.	5-10mm
3.	10-15mm
4.	15-20mm
5.	>20mm

Table 2: POM presence, height and diameter by gender

	Male	Female	
POM Presence	236 maxillary sinus (%82.5) 131 patients(%91.6)	436 maxillary sinus (%90.1) 234 patients (%96.7)	p=0.003*
POM height (mm)	32.945±6.1017	31.415±5.4924	p=0.001*
POM diameter (mm)	1.457±0.6061	1.447±0.6082	p=0.919*
	* p≤0.05		

Table 3: Schneiderian membrane thickness by gender

	≤=5mm	>5mm≤ 10mm	>10mm≤15mm	>15mm≤20mm	>20mm
Female	331 (%68.4)	64 (%13.2)	34 (%7.0)	30 (%6.2)	25 (%5.2)
Male	141 (%49.3)	58 (%20.3)	35 (%12.2)	16 (%5.6)	36 (%12.6)

Table 4: AOM presence, height and diameter by gender

	Male	**Female**	

AOM Presence	59 maxillary sinus (%20.6) 47 patients (%32.9)	93 maxillary sinus (%19.2) 68 patients (%28.1)	p=0.702*
AOM height (mm)	27.410± 6.9797	24.318±5.7212	p=0.004*
AOM diameter (mm)	2.703±1.3277	2.457±1.2033	p=0.251*
	* p≤0.05		

1. Ata-Ali, J., et al., *What is the frequency of anatomical variations and pathological findings in maxillary sinuses among patients subjected to maxillofacial cone beam computed tomography? A systematic review.* Medicina oral, patologia oral y cirugia bucal, 2017. **22**(4): p. e400.
2. Brüllmann, D.D., et al., *Correlation of cone beam computed tomography (CBCT) findings in the maxillary sinus with dental diagnoses: a retrospective cross-sectional study.* Clinical oral investigations, 2012. **16**(4): p. 1023-1029.
3. Temur, K.T., *Maksiller Sinüs Patolojilerinin ve Osteomeatal Kompleksin Radyolojik Olarak Değerlendirilmesi.* Arşiv Kaynak Tarama Dergisi. **27**(3): p. 328-345.
4. Prasanna, L. and H. Mamatha, *The location of maxillary sinus ostium and its clinical application.* Indian Journal of Otolaryngology and Head & Neck Surgery, 2010. **62**(4): p. 335-337.
5. Velli, L.T., et al., *Sinus presurgical evaluation: a literature review and a new classification proposal.* Minerva Stomatologica, 2017. **66**(3): p. 115-131.

6. Carmeli, G., et al., *Antral computerized tomography pre-operative evaluation: relationship between mucosal thickening and maxillary sinus function.* Clinical oral implants research, 2011. **22**(1): p. 78-82.

7. Yeung, A.W.K., et al., *Visibility, location, and morphology of the primary maxillary sinus ostium and presence of accessory ostia: a retrospective analysis using cone beam computed tomography (CBCT).* Clinical oral investigations, 2019: p. 1-10.

8. Akay, G., et al., *Evaluation on the Relationship of Dimensions of Maxillary Sinus Drainage System with the Anatomical Variations and Sinusopathies: Cone-Beam Computed Tomography Findings.* Medical Principles and Practice, 2019.

9. Souza, A.D., et al., *Anatomy of maxillary sinus and its ostium: A radiological study using computed tomography.* CHRISMED Journal of Health and Research, 2016. **3**(1): p. 37.

10. Yeung, A.W.K., et al., *Frequency, location, and association with dental pathology of mucous retention cysts in the maxillary sinus. A radiographic study using cone beam computed tomography (CBCT).* Clinical oral investigations, 2018. **22**(3): p. 1175-1183.

11. Akay, G., et al., *Evaluation on the Relationship of Dimensions of Maxillary Sinus Drainage System with the Anatomical Variations and Sinusopathies: Cone-Beam Computed Tomography Findings.* Medical Principles and Practice, 2019.

12. Shanbhag, S., et al., *Cone-beam computed tomographic analysis of sinus membrane thickness, ostium patency, and residual ridge heights in the posterior maxilla: implications for sinus floor elevation.* Clinical oral implants research, 2014. **25**(6): p. 755-760.

13. Ertas, N., *Factors associated with stages of cigarette smoking among Turkish youth.* The European Journal of Public Health, 2006. **17**(2): p. 155-161.

14. May, M., S.M. Sobol, and K. Korzec, *The location of the maxillary os and its importance to the endoscopic sinus surgeon.* The Laryngoscope, 1990. **100**(10): p. 1037-1042.

15. Hwang, K., et al., *Localization of the Maxillary Ostium in Relation to the Reduction of Depressed Nasomaxillary Fractures.* Journal of Craniofacial Surgery, 2018. **29**(5): p. 1358-1362.

16. Watzek, G., *The Percrestal Sinuslift: From Illusion to Reality*. 2012: Quintessence.

17. Şakul, B. and B.B. Baş, *boynun klinik bölgesel anatomisi.* Baskı. Anakara: Özkan Matbacılık, 2009: p. 171-234.

18. Guo, Z.Z., et al., *Longitudinal response of membrane thickness and ostium patency following sinus floor elevation: a prospective cohort study.* Clinical oral implants research, 2016. **27**(6): p. 724-729.

19. Phothikhun, S., et al., *Cone-beam computed tomographic evidence of the association between periodontal bone loss and mucosal thickening of the maxillary sinus.* Journal of periodontology, 2012. **83**(5): p. 557-564.

OP-38

EVALUATİON OF THE STRESS DİSTRİBUTİON OF THE IMPLANT SYSTEM WİTH SWİTCHİNG PLATFORM İN THE MANDİBLE BY FİNİTE ELEMENT ANALYSİS

Adalet Çelebi Bektaş [a], Belgin Gülsün [b], Emre Arı [c]

a, Bingöl University, Faculty Of Dentistry, Department Of Oral and Maxillofacial Surgery, Turkey, acbektas@bingol.edu.tr

b, Dicle University, Faculty Of Dentistry, Department Of Oral and Maxillofacial Surgery, Turkey, bgulsun@dicle.edu.tr

c, Dicle University, Faculty of Engineering, Machinery Department, Turkey, earı@dicle.edu.tr

Abstract

Aim: In this study, it was aimed to examine the maximum Von Misses stress distribution occurring in the bone and implant surfaces of the implants in the neck region of the implants as a result of the placement of 2 different diameters of the implant system with switching platform design in the mandible and application of forces at different angles.

Materials and Methods: İmplant prepared with specific techniques in mandibular bone model with switching platform design (3.75 mm and 4.2 mm in diameter) were scanned and transferred to the computer. Mandibular implants placed in the computer environment 300 N force applied to the bone models 30 ^{o} including vertical and angled. The maximum Von Misses stress distribution on the bone and implant surface in the neck region of the implant was evaluated.

Results: When oblique force was applied to the implant with a diameter of 3.75 mm, the maximum stress value occurring in the bone around it was 60.97 MPa, while this value was recorded as 54.15 MPa in the 4.2 mm diameter implant. When implants are placed vertically and force is applied vertically; While the implant surface of 3.75 mm diameter was 51.21 MPa, this value was found to be 46.72 MPa in the implant diameter of 4.2 mm.

Conclusion: The stress distribution obtained when implants and force were placed in the same parallelism was found to be the most ideal. As the implant diameter increases, we can say that the maximum Von Misses stress value around the implant decreases.

Keywords: Mandible, finite element analysis, switching platform

1. Introduction

Dental implants, in order to regain the function and aesthetics of teeth lost for any reason; They are alloplastic materials that are compatible with the body tissue and placed in the jawbone of the person to support prostheses to replace lost teeth (1,2).

When exposed to static and dynamic forces, dental implants osseointegrated into the maxilla and mandible give the same response to the incoming forces like natural teeth. However, in implant-supported prostheses, the forces transmitted to the maxilla and mandible are different from natural teeth. Unlike natural teeth, dental implants do not have periodontal ligaments that eliminate occlusal forces and control proprioception (pressure sense), so the forces applied to dental implants are directly transmitted to the bone tissue surrounding the implant (3).

In the radiological studies conducted by Lazzara and Porter (2006), “Platform Switching” design, which is one of the most popular terms in the world of implantology in recent years, they have noticed that there is minimal vertical loss in the surrounding bone in the surrounding bone (4). This design is to keep the abutment diameter narrow compared to the dental implant diameter in order to prevent peri-implanter bone resorption (5,6).

Finite element stress analysis is a method that evaluates the stress, tension and deterioration in structures. It is defined as "Finite Element Analysis Method" (FEM) or "Finite Element Analysis (FEA)" in the articles. The FEM method is performed by dividing the structures with complex geometry into a certain number of elements that show similar properties with the original model. The FEM method in oral implantology allows researchers to interpret stress distributions between dental implants and bone (7, 8).

In our study, we aimed to examine the stress distributions that occur when vertical and 30° (oblique) force is applied to implants with switching platform designs of different diameters placed in the mandible with FEM.

2. Materıals And Methods

The dimensions of the bone model were determined as 30x20x10 mm. 2 mm cortical bone was formed in the model we obtained. The cortical bone inner surface was defined as cancellous bone. Dual Fit Implant (DF; Alpha-BioTec®, Israel) to be applied to the mandible 1st molar region; 2 implants with 3.75mm, 4.2mm diameters and 10mm long switching platform designs were used. The bone model and implants created were scanned in 3D with the NextEngine 3D laser scanner (Next Engine, Inc. USA). Using the Rhinoceros 4.0 software program, endosteal implants were turned into a solid 3D model in computer environment. A vertical and oblique (30° angle) 300 Newton (N) force was applied at certain points on the prosthetic superstructure. Model 1, by placing the implant vertically to the mandibular bone model at 3.75 mm diameter and applying vertical force; The 3.75 mm diameter implant was placed vertically on the mandible and obtained by applying oblique force, it was named mode 2. The same situation was named model 3 and model 4 for the 4.2 mm diameter implant (Table 1). In total, 4 models were obtained. The obtained data were analyzed and interpreted with ANSYS 14.0 analysis program.

The implants and bone used in the models were considered isotropic, homogeneous and linear elastic. The modulus of elasticity and poisson ratios of the materials in the study are shown in Table 2.

3. Results

In our study, we interpreted the Von Misses stress values occurring in the bone in the neck region of the implants and on the implant surface according to the color scale. In the color scale we use, red is arranged to show the maximum Von Misses stress value and dark blue to show the minimum Von Misses stress value.

Von Misses stress values obtained by placing the implant vertically and applying the force vertically in model 1 and model 3 occurred at minimum level in the bone around the implant. While the maximum Von Misses stress value in the bone around the implant in Model 1 was 8.02 Mpa, this value was recorded as 7.74 Mpa in model 3 (Table 3).

In Model 2, the maximum Von Misses stress value occurring on the implant surface is 500.01 Mpa, while the value formed on the bone surface around the implant is 60.97 Mpa. In Model 4, the maximum Von Misses stress value formed on the implant surface is 454.38 Mpa, while the value formed on the bone surface around the implant is 54.15 Mpa (Table 2).

Maximum Von Misses stress values were obtained with vertical placement of implants and oblique application of force. With the application of oblique force, stress values on both the implant surface and the bone in the neck region of the implant have changed inversely with the increase in the implant diameter (Table 4).

4. Discussion

Functional and parafunctional forces generated in the intraoral area are transmitted to the implants and from there to the neighboring bone via the superstructure of the implants. These forces can also affect the remodeling of the bone around the implant by causing tension and deformation in the implant-bone contact area (9).

The mandible contains a smaller number of different bone densities than the maxilla. There is more D2 bone density in the mandible. Therefore, the entire mandible has been modeled in accordance with the characteristics of D2 type bone in studies (10). Cortical bone thickness was accepted as 2 mm (11).

It is thought that the reduction of stresses on the bone has a decreasing effect on crestal bone resorption. The increase in tension seen around the implant-abutment interface and the connection screw can be considered as a mechanical disadvantage. It is thought that increasing the implant-abutment contact surface in platform switching protocol applications will cause a decrease in high voltages (12). In our study, we noted that the stress intensity on the bone in the neck region of the implant increased.

Deshpande et al., In their study using the three-dimensional finite element analysis method (2009), stated that the stress value in the bone with traditional abutment placement was 785 Mpa, and this value was 466 Mpa in the bone

around the implants with platform switching design. According to this result, Von Misses reported that stress distribution is most concentrated in the neck of the implant (13).

In the study conducted by Chang et al. (2012), they reported that especially oblique forces cause more tension in the bone (14). In our study, we saw that the stress value on the implant surface and bone in the neck region of the implant increased under oblique force.

In different studies, it has been pointed out that increasing the implant diameter is an effective method to increase the contact between bone and implant. As the surface area in contact with the bone increases, the stability of the implant within the bone increases and the incoming forces are better tolerated. The use of large-diameter implants provides better distribution of incoming forces, as stress is mostly concentrated in the neck of the implant. Less stress on the cortical bone around the neck of the implant prevents bone resorption and increases the success rate of implants (15,16). The data we obtained in our study gave results that support the studies.

5. Conclusion

When the oblique and vertical loads applied to the bone models were compared, Von Misses stress values in the cortical bone around the crest module (neck part) of the implant showed a significant increase in the forces applied in the oblique direction. For an ideal stress distribution, the implant and the force must be in the same direction.

6. Acknowledgment

This study was produced from project (number: DİŞ.15.015) supported by The Scientific Research Projects Coordination Unit of Dicle University.

7. References

1. Neldam CA, Pinholt EM. State of the Art of Short Dental Implants: A Systematic Review of the Literature. Clinical Implant Dentistry and Related Research. 2012;14(4):622-32.
2. Bidez MW, Misch CE. Clinical biomechanics in implant dentistry. Dental Implant Prosthetics. S Louis: Elsevier Mosby. Dokuzuncu Baskı, USA, 2005.
3. Albrektsson T, Zarb G, Worthington P, Eriksson AR. The long-term efficacy of currently used dental implants: a review and proposed criteria of success. International Journal of Oral and Maxillofacial Implants.1986;1(1):11-25.
4. Lazzara RJ, Porter SS. Platform switching: a new concept in implant dentistry for controlling postrestorative crestal bone levels. International Journal of Periodontics and Restorative Dentistry. 2006;26(1):9-17.
5. Ericsson I, Persson LG, Berglundh T, Marinello CP, Lindhe J, Klinge B. Different types of inflammatory reactions in periimplant soft tissues. Journal of Clinical Periodontology. 1995;22(3):255–61.
6. Freitas-Júnior AC, Rocha EP, Bonfante EA, Almeida EO, Anchieta RB, Martini AP, Assunção WG, Silva NR, Coelho PG. Biomechanical evaluation of internal and external hexagon platform switched implant-abutment connections: An in vitro laboratory and three-dimensional finite element analysis. Dent Mater. 2012:28(1):218:8.
7. Farah JW, Craig RG, Meroueh KA. Finite element analysis of a mandibuler model. J Oral Rehabil. 1988;15(6):615-624.
8. Torcato LB, Pellizzer EP, Verri FR, Falcón-Antenucci RM, Santiago Júnior JF, de Faria Almeida DA. Influence of parafunctional loading and prosthetic connection on stress distribution: A 3D finite element analysis. J Prosthet Dent. 2015:114(5):644-51.
9. Isidor F. Loss of osseointegration caused by occlusal load of oral implants. A clinical and radiographic study in monkeys. Clin Oral Implants Res. 1996;7(2):143–152.

10. Misch CE. Density of bone: effect on treatment plans, surgical approach, healing and progressive loading. Int J Oral Implantol. 1990;6(2):23-31.
11. Sevimay M, Turhan F, Kılıçaslan MA, Eskitasçıoglu G. Three-dimensional finite element analysis of the different bone quality on stress distribution in an implant-supported crown. J Prosthet Dent. 2005; 93(3):227-234.
12. Tabata LF, Rocha EP, Barão VA, Assunção WG. Platform switching: biomechanical evaluation using three-dimensional finite element analysis. Int J Oral Maxillofac Implants. 2011:26(3):482-91.
13. Deshpande SS, Sarin SP, Parkhedkar RD. Platform Switching of Dental Implants: Panacea For Crestal Bone Loss. 2009;3(1):1348-52.
14. Chang SH, Lin CL, Hsue SS, Lin YS, Huang SR. Biomechanical analysis of the effects of implant diameter and bone quality in short implants placed in the atrophic posterior maxilla. Med Eng Phys. 2012;34(2):153-60.
15. Himmlová L, Dostálová T, Kácovský A, Konvicková S. Influence of implant length and diameter on stress distribution: a finite element analysis. J Prosthet Dent. 2004;91(1):20-5.
16. Holmgren EP, Seckinger RJ, Kilgren LM, Mante F. Evaluating parameters of osseointegrated dental implants using finite element analysisa two-dimensional comparative study examining the effects of implant diameter, implant shape and load direction. J Oral Implantol. 1998;24(2):80-84.

7. Tables

Implant diameter (mm)	*Implant placement*	*Direction of force application*	*Model*
3,75	Vertical	Vertical	Model 1
3,75	Vertical	30° (oblique)	Model 2
4,2	Vertical	Vertical	Model 3
4,2	Vertical	30° (oblique)	Model 4

Table 1: Experimental groups and conditions.

Material	**Elasticity modulus (Gpa)**	**Poisson's ratio**
Cortical bone	**13.7**	**0.3**
Trabecular bone	**1.37**	**0.3**
Titanium	**113.8**	**0.342**

Table 2: Material properties.

Model / Maximum Von Mises stress values (Mpa)	*Bone in the implant neck area*	*Implant surface*
Model 1	**8.02**	**51.21**
Model 2	**60.97**	**500.01**
Model 3	**7.74**	**46.72**
Model 4	**54.15**	**454.38**

Table 3: Maximum Von Misses stress values around the implant and on the implant surfaces of the models.

	Bone in the implant neck area	Implant surface
Model 2	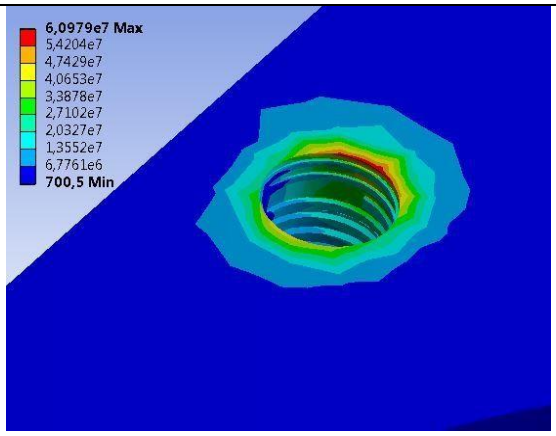	
Model 4	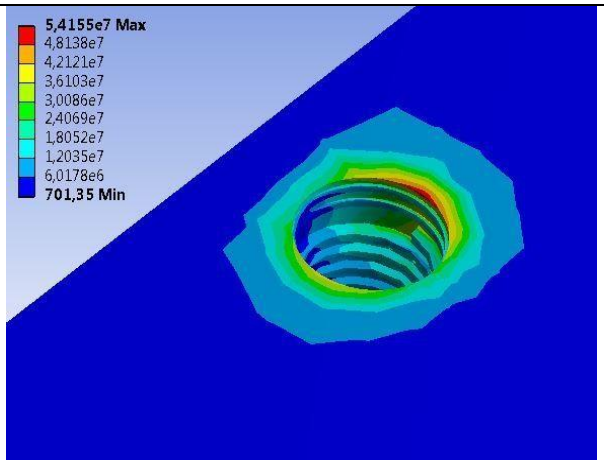	

Table 4: Maximum Von Misses stress distribution in the bone in the neck region of the implant and on the implant surface in model 2 and model 4.

OP-42

The comparative evaluation of oral health-related quality of life and patient satisfaction in patients both treated with mandibular conventional complete dentures and mandibular 2 implant-supported locator-retained overdentures

Ömür Dereci [a], Emre Mumcu [b], Görkem Tekin [c]

A-Eskişehir Osmangazi University, Faculty of Dentistry, Department of Oral and Maxillofacial Surgery, Eskişehir, Turkey, omurdereci@hotmail.com

B-Eskişehir Osmangazi University, Faculty of Dentistry, Department of Prosthodontics, Eskişehir, Turkey, emremum@yahoo.com

C-Eskişehir Osmangazi University, Faculty of Dentistry, Department of Oral and Maxillofacial Surgery, Eskişehir, Turkey, dt.gorkemtekin@gmail.com

Abstract

Objective: Locator-retained implant-supported overdentures are safely used in the treatment of edentulous jaws. The aim of this study is to evaluate the impact on oral health-related quality of life

and patient satisfaction in patients treated with both conventional complete dentures and implant-supported locator-retained overdentures in mandibular edentulism.

Materials and Methods: The clinical data of all patients treated with both conventional complete dentures and 2 implant-supported locator-retained overdentures between 01/01/2015 and 01/04/2018 were evaluated. The oral health Impact profile-14 (OHIP-14) questionnaire which is constituted by seven domains and oral satisfaction scale (OSS) which comprises 7 levels of impact of general comfort, esthetics, retention, speech, ease of hygiene maintenance, pain and chewing were taken from the patients by self-assessment after 3-6 months use of conventional complete prosthesis and locator-retained 2 implant-supported overdentures. OHIP-14 and OSS scores obtained after conventional complete denture and implant-supported locator-retained overdenture use were compared with statistical analysis.

Results: Ninety-six patients were included in the study. OHIP-14 scores were statistically higher in conventional complete denture group than in implant-supported locator-retained overdenture group ($p<0,05$). Two implant-supported locator-retained overdenture group showed statistically higher OSS scores than conventional complete denture group except ease of hygiene maintenance ($p<0,05$). Ease of hygiene maintenance scores were significantly higher in conventional complete denture group ($p<0,05$).

Conclusion: The use of implant-supported locator-retained overdentures shows increased levels of oral health-related quality of life and patient satisfaction than the use of conventional complete dentures except ease of hygiene maintenance in the same patient population. The reason for this may be the difficulty of cleaning the overdenture prosthesis due to the retentive parts of the locator components.

Key Words: Complete denture, edentulous, mandible, oral health impact profile, overdenture

1. Introduction

The implant-supported overdenture prosthesis is an effective treatment method in the rehabilitation of mandibular edentulism (1). They were recommended as the first choice of treatment in mandibular edentulism unless full-mouth implantation is indicated (2). However, it is suggested that there is still a need for future studies that investigate the patient satisfaction and cost-effectiveness on mandibular implant-supported overdentures and conventional dentures (3).

Many types of individual attachment systems that bind the overdenture prosthesis and implant abutment are used in implant-supported overdentures. As one of these systems, the locator retainer is a type of press-fit attachment used to stabilize the implant-supported overdentures. Usage of locator retention system proves to be a viable option in mandibular implant-supported overdentures and provides several advantages such as the chance of implant angulation correction and increased retention (4,5).

The impact on oral health-related quality of life and patient satisfaction in patients treated with implant-supported overdentures with conventional attachment types such as ball attachments and bars and conventional complete dentures were compared in several studies (1,6-9). However, the number of studies that compare the level of the impact on oral health-related quality of life and patient satisfaction in patients treated with implant-supported locator-retained overdentures and conventional complete dentures is limited (10). We hypothesized that there was no difference between conventional complete dentures and 2 implant-supported locator-retained overdentures in regards to impact on oral health-related quality of life and patient satisfaction for patients treated with both conventional complete dentures and implant-supported locator retained overdentures.

The aim of this study is to evaluate the impact on oral health-related quality of life and patients satisfaction in patients both used conventional total prosthesis and implant-supported locator-retained overdentures in mandibular edentulism.

2. Materials and Methods

2.1. Ethical Approval

The study protocol was approved by the Local Research Ethics Committee with approval number 2018-110 and was performed following the ethical standards laid down in the 1964 Declaration of Helsinki and its later amendments. All patients signed informed consent forms.

2.2.Patients and quality of life assessment

The clinical data of all patients treated with both conventional complete denture and 2 implant-supported locator-retained overdenture prosthesis between 01/01/2015 and 01/04/2018 were retrieved from the archieves and evaluated. Inclusion criteria of the study were;

1- Mandibular and maxillary edentulous patients who had used provisional conventional complete mandibular dentures for 3-6 months before using locator retained implant-supported overdentures for 3-6 months.

2- Patients without any systemic disease and medical prescription

3- Patients with unharmed clinical follow-up record

There are no gold standard method used for the measurement of the impact on oral health-related quality of life and patient satisfaction. However, the oral health impact profile (OHIP) and oral satisfaction scale (OSS) questionnaires are the most common tests that demonstrate patient satisfaction and acceptance of the prosthesis. OHIP-14 questionnaire and OSS were taken from the patients by self-assessment after 3-6 months use of conventional complete prosthesis and 2 implant-supported locator-retained overdentures. In this context, quality of life questionnaires were routinely taken from all patients using implant-supported or conventional total dentures in our institution.

The OHIP-14 self-reporting questionnaire was used to assess the impact on oral health-related quality of life. The Turkish version of the questionnaire has been validated (11) and used in several studies with good results (12-14) .

The OHIP-14 questionaire has 14 questions which are answered by patients using a Likert scale that includes 5 points, each expresses a positive or negative judgment (0-none, 1-rarely, 2- sometimes, 3-frequently, 4- generally) about the question. Quality of life decreases with the increase in the scores. The questionnaire comprises 7 levels of impact as functional limitation, physical pain, psychological discomfort, physical disability, psychological disability, social disability, and handicap, respectively. The scoring was evaluated by calculating both the scores of these 7 levels seperately and the total score.

The OSS is a visual analog scale that allows participants to weight their perceived oral satisfaction. The Turkish version of the oral satisfaction scale was used for measuring the self-assessment of oral satisfaction (13-15). A 100 mm visual analog scale with determinants of “0” defining completely unsatisfied-worst possible level and “100” defining completely satisfied-best possible level was prepared for the patient scoring. The questionnaire comprised 7 questions that includes 7 levels of impact that are explained as general comfort, esthetics, retention, speech, ease of hygiene maintenance, pain, and chewing.

2.3.Surgery and prosthetic procedure

A crestal incision with releasing vertical incisions and periosteal flap reflection were made to expose the interforaminal mandibular crestal bone under local anesthesia (Maxicaine forte, Vem Pharmaceuticals, Istanbul). Two dental implants (Osseospeed®, AsraTech dental implants, Dentsply,

Sweden) were inserted with drilling equipment under physiological saline irrigation with manufacturer's instructions in the interforaminal region. Flap was closed with 3-0 silk sutures after dental implant placement. The sutures were removed 1 week after surgery.

Routine prosthodontic clinical steps were performed by one experienced prosthodontist. Provisional conventional maxillary and mandibular complete dentures were fabricated using a standard prosthetic technique which included balanced articulation using the anatomically shaped acrylic resin artificial teeth (Merz Integral, Germany) and maximal extension of the denture base using functional impression methods before the dental implant surgery. Three-six months after the fabrication of conventional complete dentures, dental implant surgery was performed. As a standard loading protocol, three-months after dental implant insertion, the mandibular conventional complete denture that the patient was using was converted into a implant-supported locator-retained overdenture using a chair-side processing method. In this method, the patrix component of the locator system (Figure 1) was attached to the conventional denture with self-curing acrylic resin. The press-fit adaptatipon of patrix and matrix (Figure 2) components were established in the clinical setting.

2.4.Statistical Analysis

An independent statistician reviewed the methodology and results of the study. SPSS version 21.0 Statistical Software (IBM, Chicago, USA) was used for statistical analysis of the results. A Shapiro–Wilk test ($P < 0.05$) and a visual inspection of the histograms, normal Q–Q plots, and box plots showed that the exam scores were not normally distributed for all scores. Wilcoxon signed-rank test was used for statistical analysis.

3. Results

Ninety-six patients were included in the study. Mean age was 64,4 ±6,4. Forty-nine (51%) of the study patients were male and 47 (49%) of them were female. OHIP-14 scores were statistically higher in conventional complete denture group compared to implant-supported locator-retained overdentures in terms of total score and scores of 7 domains (functional limitation, physical pain, psychological discomfort, physical disability, psychological disability, social disability and handicap) ($p<0,05$) (Table1). Two implant-supported locator-retained overdenture usage showed statistically higher OSS scores in regards to general comfort, esthetics, retention, speech, chewing and pain, whereas conventional complete denture usage showed significantly higher OSS scores than 2 implant-supported locator-retained overdenture usage with regards to ease of hygiene maintenance ($p<0.05$) (Table 2).

4. Discussion

Implant-supported overdentures are commonly used with increased stability and function in the treatment of edentulism and it was advocated that they should be provided only for patients with major problems with their conventional prosthesis (5).

Meijer et al. (6) reported that patients treated with conventional complete dentures showed decreased levels of oral satisfaction scores than patients treated with 2 implant-supported overdentures in a 10-year period. As a contradictory report, Assunçao et al. (7) compared the quality of life and satisfaction levels in two groups of total denture users and users of implant-supported overdentures opposed with a conventional total denture, and suggested that there was no significant difference between quality of life and patient satisfaction levels for both groups. Fernandez-Estevan et al.

(10) compared the quality of life with an OHIP-20 questionnaire and OSS between separate groups of patients with conventional complete dentures and implant-supported locator-retained overdentures and reported that patients with implant-supported locator-retained overdentures had significantly higher satisfaction levels and significantly lower levels of impact on quality of life than conventional complete dentures. The patients included in this study used provisional complete dentures prior to the implant insertion and subsequent implant-supported overdenture fabrication. In that sense, patient satisfaction and quality of life were measured on the same patient who used the two types of prosthesis in different time periods. This is the first study that focuses on the impact on oral health-related quality of life and patient satisfaction between conventional dentures and locator-retained two implant-supported overdentures in the same patient population to our knowledge.

5. Conclusion

In the current study, the oral health-related quality of life was significantly superior in 2 implant-supported locator-retained overdentures than in conventional complete dentures. All domains of patient satisfaction were also significantly higher in 2 implant-supported locator-retained overdentures except ease of hygiene maintenance. The reason for this may be the difficulty of the cleaning of the retentive regions of male and female parts of the locator system.

The use of implant-supported locator-retained overdentures showed increased levels of oral health-related quality of life than the use of conventional complete dentures in the same patient population.

Patient satisfaction showed higher levels in the implant-supported locator-retained overdentures except ease of hygiene maintenance. This situation may be because of the difficulty of the cleaning of the retentive regions of the locator system.

6. References

1. Allen PF, Thomason JM, Jepson NJ, Nohl F, Smith DG, Ellis J. A randomized controlled trial of implant-retained mandibular overdentures. J Dent Res 2006;85:547-551.
2. Feine JS, Carlsson GE, Awad MA, Chehade A, Duncan WJ, Gizani S, et al. The McGill consensus statement on overdentures. Mandibular two-implant overdentures as first choice standard of care for edentulous patients. Montreal, Quebec, May 24-25, 2002. Int J Oral Maxillofac Implants 2002;17:601-602.
3. Emami E, Heydecke G, Rompré PH, de Grandmont P, Feine JS. Impact of implant support for mandibular dentures on satisfaction, oral and general health-related quality of life: a meta-analysis of randomized-controlled trials. Clin Oral Implants Res. 2009;20:533-544.
4. Miler AMQP, Correia ARM, Rocha JMC, Campos JCR, da Silva MHGF. Locator® attachment system for implant overdentures: a systematic review. Stomatologija. 2017;19:124-129.
5. Trakas T, Michalakis K, Kang K, Hirayama H. Attachment systems for implant retained overdentures: a literature review. Implant Dent. 2006;15:24-34.
6. Meijer HJ, Raghoebar GM, Van 't Hof MA. Comparison of implant-retained mandibular overdentures and conventional complete dentures: a 10-year prospective study of clinical aspects and patient satisfaction. Int J Oral Maxillofac Implants. 2003;18:879-885.

7. Assunção WG, Zardo GG, Delben JA, Barão VA. Comparing the efficacy of mandibular implant-retained overdentures and conventional dentures among elderly edentulous patients: satisfaction and quality of life. Gerodontology. 2007;24:235-238.
8. Awad MA, Lund JP, Dufresne E, Feine JS. Comparing the efficacy of mandibular implant-retained overdentures and conventional dentures among middle-aged edentulous patients: satisfaction and functional assessment. Int J Prosthodont. 2003;16:117-122.
9. Visser A, Meijer HJ, Raghoebar GM, Vissink A. Implant-retained mandibular overdentures versus conventional dentures: 10 years of care and aftercare. Int J Prosthodont. 2006;19:271-278.
10. Fernandez-Estevan L, Selva-Otaolaurruchi EJ, Montero J, Sola-Ruiz F. Oral health-related quality of life of implant-supported overdentures versus conventional complete prostheses: Retrospective study of a cohort of edentulous patients. Med Oral Patol Oral Cir Bucal. 2015;20:e450-e458.
11. Mumcu G, Inanc N, Ergun T, Ikız K, Gunes M, Islek U, et al. Oral health related quality of life is affected by disease activity in Behçet's disease. Oral Dis. 2006;12:145-151.
12. Ustaoğlu G, Göller Bulut D, Gümüş KÇ, Ankarali H. Evaluation of the effects of different forms of periodontal diseases on quality of life with OHIP-14 and SF-36 questionnaires: A cross-sectional study. Int J Dent Hyg. 2019;17:343-349.
13. Geckili O, Cilingir A, Erdogan O, Kesoglu AC, Bilmenoglu C, Ozdiler A, et al. The influence of momentary retention forces on patient satisfaction and quality of life of two-implant-retained mandibular overdenture wearers. Int J Oral Maxillofac Implants. 2015;30:397-402.
14. Kilic K, Kurtulus IL, Eraslan R, Zararsiz G, Kesim B. Effects of attachment type and palatal coverage on oral perception and patient satisfaction in maxillary implant-supported complete denture patients. Niger J Clin Pract. 2019;22:669-674.
15. Mumcu E, Bilhan H, Geckili O. The effect of attachment type and implant number on satisfaction and quality of life of mandibular implant-retained overdenture wearers. Gerodontology. 2012;29:e618-e623.

7. Figures

Figure 1. The male (patrix) component of the locator system is adapted into the conventional complete denture with cold acrylic resin.

Figure 2. The female (matrix) component of the locator system is adapted as abutment 3 months after surgery.

8. Tables

Table 1. Comparison of conventional complete dentures used provisionally before implant placement and 2 implant-supported locator-retained overdenture prosthesis with regards to OHIP-14 quality of life questionnaire.

OHIP-14 impact level	Conventional complete dentures used 3-6 months before implant surgery (mean±std)	Two implant-supported locator -retained overdentures used 3-6 months after prosthesis delivery (mean±std)	P*
Functional limitation	2.91±1.65	1.23±1.26	<0.001
Physical pain	2.45±1.69	0.96±1.31	<0.001
Psychological discomfort	2.13±1.45	1.34±1.37	<0.001
Physical disability	1.61±2.02	1±1.24	<0.001
Psychological disability	1.46±1.40	0.76±1.13	<0.001
Social disability	0.72±1.41	0.37±0.94	<0.001
Handicap	0.81±1.11	0.5±1.05	<0.001
OHIP-14 total score	12.13±8.30	6.18±6.5	<0.001

*****Wilcoxon signed rank test

P<0.05 was statistically significant.

Table 2. Comparison of conventional complete dentures used provisionally before implant placement and 2 implant-supported locator-retained overdenture prosthesis with regards to oral satisfaction scores obtained with VAS.

OSS impact level	Questionnaire	Conventional complete dentures used 3-6 months before implant surgery (mean±std)	Two implant-supported locator -retained overdentures used 3-6 months after prosthesis delivery (mean±std)	P*
General Comfort	Are you satisfied with your prosthesis?	79.11±20.3	86.69±15.02	<0.001
Retention	Are you satisfied with the immobility of your prosthesis when functioning?	70.88±21.74	86.09±21.91	<0.001
Chewing	Can you perform the chewing function with your prosthesis?	71.67±17.38	91.83±10.49	<0.001
Speech	Are you satisfied with your speaking function with your prosthesis?	79.84±16.97	91.06±12.78	<0.001
Hygiene maintenance	Are you having difficulty in cleaning of your prosthesis?	89.65±16.32	86.94±18.91	0.015
Esthetics	Does your prosthesis meet your esthetic expectations?	91.05±13.99	91.81±12.86	0.043

Pain	Do you experience pain when using the prosthesis?	10.37±15.42	5.55±8.54	<0.001

*Wilcoxon signed rank test

P<0.05 was statistically significant.

OP-45

Effective Management of Extensive Odontogenic Cysts Using Surgical Enucleation Three Cases Report

Onur Yeşiltaş[a], Hilal Alan[a]

Department of Oral and Maxillofacial Surgery, Inonu University Faculty of Dentistry Malatya, Turkey, onur.yesiltas@inonu.edu.tr

Abstract

Objective: Odontogenic cysts are the most common form of cystic lesions that affected the maxillofacial region. They are classified traditionally into a developmental group, including keratocysts and dentigerous cysts, and an inflammatory group including radicular, residual, paradental cysts. Inflammatory odontogenic cysts are benign osteolytic asymptomatic lesions, but that, depending on the size, they can destroy the surrounding bone and let it infected. Developmental cysts are usually asymptomatic, but have the potential to become extremely large and cause cortical expansion and erosion. Radicular cysts are most common cysts of the jaw. Our aim in this presentation is to evaluate the treatment results of 3 patients who were diagnosed as odontogenic cyst in the maxilla or mandible that we followed and treated in our clinic, as well as the clinical and surgical features, and to present it in the light of the literature.

Case Report: 3 cases will be presented including 2 male and 1 female patient. The cyst in each case is larger than 3 cm in diameter. Enucleation treatment was applied in one session in all patients.

Conclusion: Given the large size of the odontogenic lesion, decompression can be done before enucleation to reduce the size of the lesion. However, this treatment disadvantageously causes morbidity in the patient due to the long recovery time and decompression stents. To achieve a successful outcome, the surgeon must evaluate all factors such as age, the patient's general medical condition, and the size and diagnosis of the lesion.

Keywords: Enucleation, Odontogenic Cysts, Dentigerous Cyst, Radicular Cyst

1. Introduction

Odontogenic Cyst are the most common cystic lesions that influence the maxillofacial area (1). Developmental cyst are usually asymptomatic, however have the potential to become extremely large and cause cortical expansion and erosion (2). Jaw cysts are more common man than woman, with a ratio of 1.6:1. Most cases are described in the fourth decade to sixth decade of life. Most odontogenic cysts are encountered in the maxillary anterior region, followed by the mandibular molar region. Radicular cysts, dentigerous cysts, odontogenic keratocysts, and

residual cysts are the most frequently described odontogenic cysts (3). Radicular cysts are the most common cyst of the jaw and are caused by inflammatory processes. All radicular cysts are associated with non vital teeth and identified at the apex of tooth. Decaying process or trauma triggers the residual epithelial remnants at the periapical region and stimulates and proliferates epithelial ruins, leading to cyst formation (4). Dentigerous cyst is the second most prevalent cyst of the jaw and has a developmental origin. Approximately all of the dentigerous cyst surrounds the crown of an impacted tooth and the radiolucent area is attached to the tooth at the cementoenamel junction (CEJ) (5). Dentigerous cysts are mostly asymptomatic unless infected (6). Extraction with inadequate curettage may lead to persistent cyst in jaw, leading to formation of residual cyst. The cyst may continue asymptomatic unless the cyst enlarges and causes pressure effects. Radiologically residual cyst reveals well-defined, unilocular radiolucency at the extraction sites (7).

2. Case Reports

Case 1: A 38-year-old male patient who was referred to our clinic from another clinic did not have any symptoms. The patient's anamnesis revealed Hypogonadotropic hypogonadism on his story. On panoramic radiography and CT examination, there was a 50x40 mm diameter radiolucent lesion in the left mandible starting from the angulus and completely covering the corpus, also mandibular canal was surrounded with lesion but there was no numbness in left side (Fig 1-2). The patient was underwent incisional biopsy under local anesthesia with a preliminary diagnosis of odontogenic cyst. The lesion was enucleated after the resulting pathology outcome (Fig 3-4). PRF membrane was placed into the lesion cavity (Fig 5). The incision area was closed in layers with 4.0 silk suture. A radiograph was taken post operatively 8 months showed clear bone recovery (Fig.6).

Case 2: A 34-year-old male patient applied to our clinic with complaints of occasional pain in his teeth. The extraoral examination revealed a swelling that causes facial asymmetry at the right side of the maxilla. On the intraoral clinical examination, a swelling between the buccal side of the first incisor and the right canine was observed. On the panoramic radiograph and CT, an extensive radiolucency starting from the resorbed root apex of the central incisor, continuing with the lateral incisor and right canine and the right nasal floor and extending up until the inferior concha, was observed (Fig 8-9). The lesion diameter was 32x28 mm. Initially, root canal treatment was applied to the teeth. The patient was operated under local anesthesia with a

preliminary diagnosis of odontogenic cyst. The lesion was enucleated (Fig 10-11). A radiograph was taken post operatively 10 months showed clear bone recovery (Fig 12).

Case 3: When a 44-year-old female patient applied to our clinic, a lesion was attempted to be opened and removed at another clinic, but the physician failed and sent it to us. When evaluated by panoramic radiography and CT, 21x30 mm in diameter radiolucent lesion located in the anterior maxilla was present (Fig 14-16). Also there was odontoma with the lesion. After the tissue healing of the first operation, the operation area was opened again and enucleated. Odontogenic cyst, odontoma and impacted tooth were removed (Fig 17). Flap completely closed with 3.0 silk suture (Fig 18).

3. Discussion

Marsupialization or enucleation are surgical approaches to cystic lesions of the jaws (8). The treatment management of choice is dependent on the size and localization of the lesion, the bone stability of the cystic wall and its closeness to vital structures. In cases of extensive lesions, CBCT scans are more beneficial for the assessment of details about the size, localisation, origin and content of the lesion, as well as the status of the cortical bone plates and relationship of the lesion with the adjacent anatomic structures (9). In the treatment of bone defects, it is shown that the bone gap is filled and the primary closure of the defect results in faster recovery and faster ossification in the cavity. Autogenous bone graft is the most preferred method of filling the bone defect and the gold standard is accepted (10, 11). However, in these cases, we achieved complete recovery of large defects without using grafts.

4. Conclusion

Given the large size of the odontogenic lesion, decompression can be done before enucleation to reduce the size of the lesion. However, this treatment disadvantageously causes morbidity in the patient due to the long recovery time and decompression stents. To achieve a successful outcome, the surgeon must evaluate all factors such as age, the patient's general medical condition, and the size and diagnosis of the lesion.

Considering the bone regeneration and preservation of vital structure after extensive cyst management in the literature, each new case may be important for documenting similar conditions.

5. References

1. High A, Robinson P, Klein C. Discrimination of parakeratinised odontogenic keratocysts from other odontogenic and non-odontogenic cyst types by expression of a 38kd cell-surface glycoprotein. Journal of oral pathology & medicine. 1993;22(8):363-7.
2. Shear M. Developmental odontogenic cysts. An update 1. Journal of oral pathology & medicine. 1994;23(1):1-11.
3. Tamiolakis P, Thermos G, Tosios KI, Sklavounou-Andrikopoulou A. Demographic and clinical characteristics of 5294 jaw cysts: a retrospective study of 38 years. Head and neck pathology. 2019;13(4):587-96.
4. Bilodeau EA, Collins BM. Odontogenic cysts and neoplasms. Surgical pathology clinics. 2017;10(1):177-222.
5. Vasiapphan H, Christopher PJ, Kengasubbiah S, Shenoy V, Kumar S, Paranthaman A. Bilateral dentigerous cyst in impacted mandibular third molars: a case report. Cureus. 2018;10(12).
6. Narang RS, Manchanda AS, Arora P, Randhawa K. Dentigerous cyst of inflammatory origin—a diagnostic dilemma. Annals of diagnostic pathology. 2012;16(2):119-23.
7. Karam N, Karam F, Nasseh I, Noujeim M. Residual cyst with a misleading clinical and radiological appearance. Journal of Oral and Maxillofacial Radiology. 2013;1(1):17.
8. Bodner L. Cystic lesions of the jaws in children. International journal of pediatric otorhinolaryngology. 2002;62(1):25-9.
9. Freitas D, Tempest L, Sicoli E, Lopes-Neto F. Bilateral dentigerous cysts: review of the literature and report of an unusual case. Dentomaxillofacial Radiology. 2006;35(6):464-8.
10. Chima KK, Seldin EB, Dodson TB. Comparison of wound management methods after removal of maxillofacial osseous lesions. Journal of oral and maxillofacial surgery. 2006;64(9):1398-403.
11. Pradel W, Eckelt U, Lauer G. Bone regeneration after enucleation of mandibular cysts: comparing autogenous grafts from tissue-engineered bone and iliac bone. Oral Surgery, Oral Medicine, Oral Pathology, Oral Radiology, and Endodontology. 2006;101(3):285-90.

6. Figures

Case 1:

Figure 1: Pre operative panoramic xray showing a large radiolucency

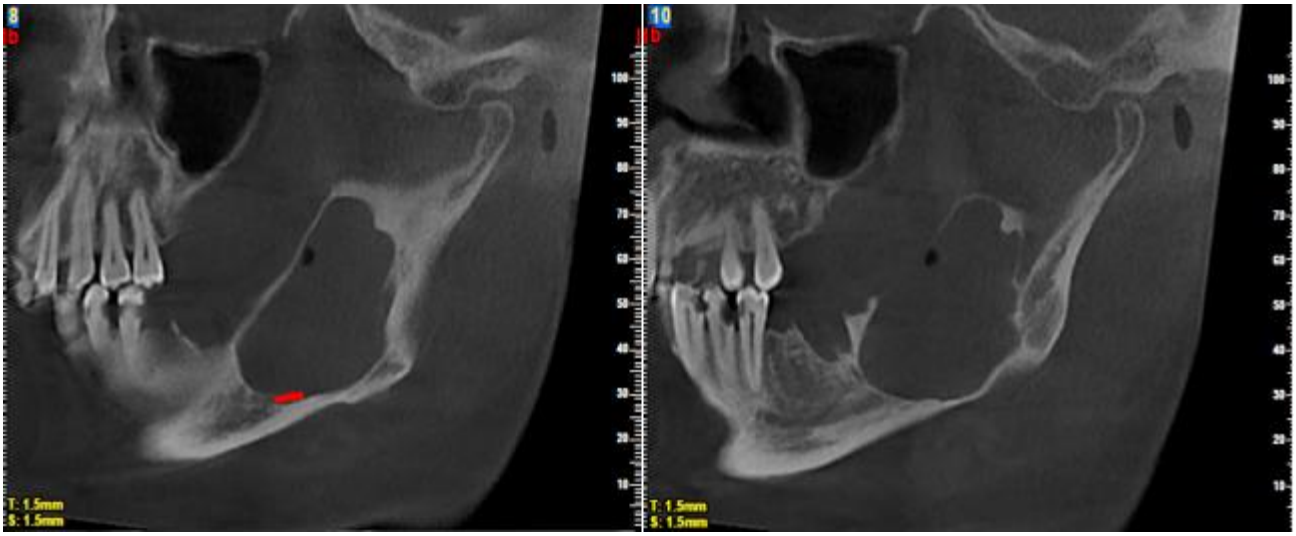

Figure 2: Preoperative sagittal CBCT shows 5 cm in diameter of an extensive radioluncecy with a large perforation of the eroded cortical plate

Figure 3: Inferior alveolar nerve

Figure 4: Surgical specimen after enucleation

Figure 5: PRF membrane was placed into the lesion cavity.

Figure 6: Post operative panoramic xray after 8 months from enucleation

Figure 7: Intraoral view after 8 months from enucleation

Case2:

Figure 8: Preoperative orthopantomogram of an unilocular appearing radicular cyst associated with an maxillar incisors.

Figure 9: Sagittal CBCT showing the cyst associated with maxillar incisor

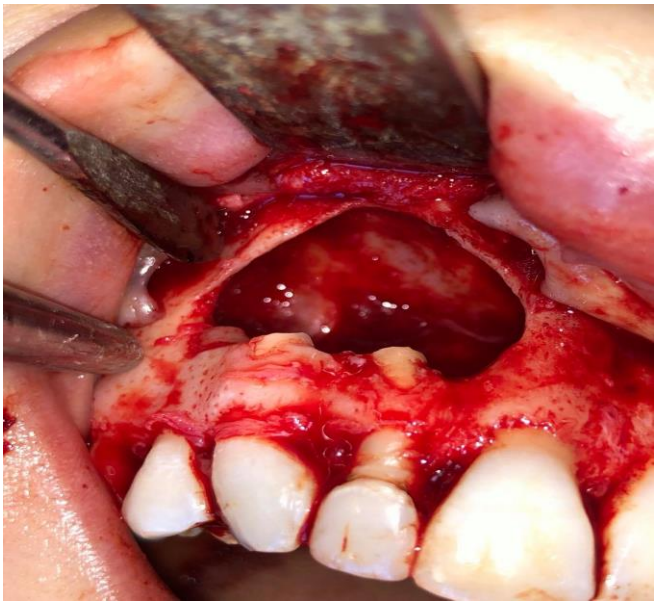

Figure 10: Enucleation of the lesion.

Figure 11: Surgical specimen after enucleation

Figure 12: Post operative xray after 10 months from enucleation.

Figure 13: Intraoral view after 10 months from enucleation

Case 3:

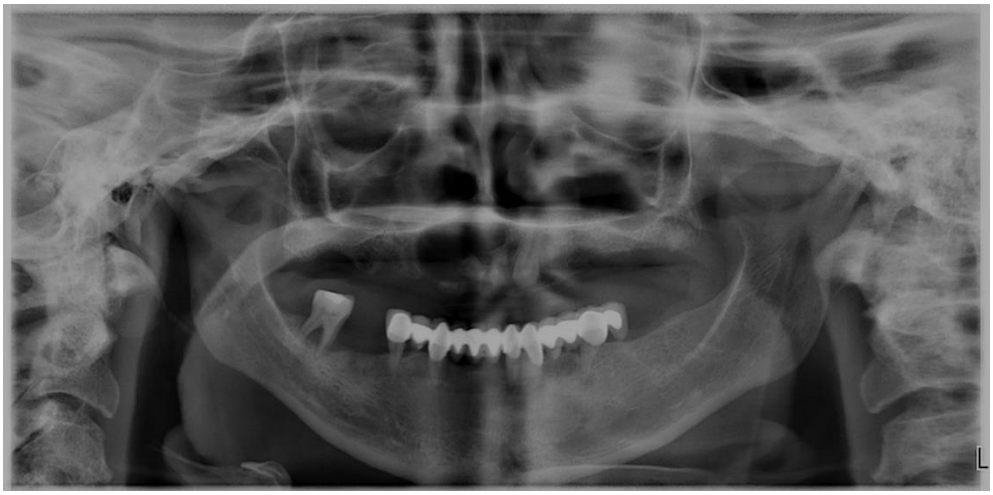

Figure 14: Pre operative panoramic xray showing a large radiolucency with an embedded canine and odontoma

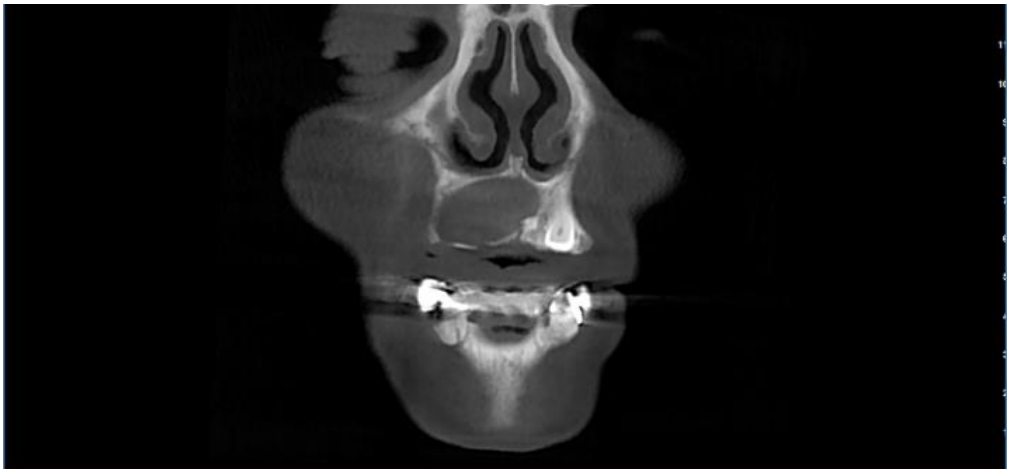

Figure 15: Coronal CBCT showing well defined unilocular radiolucency.

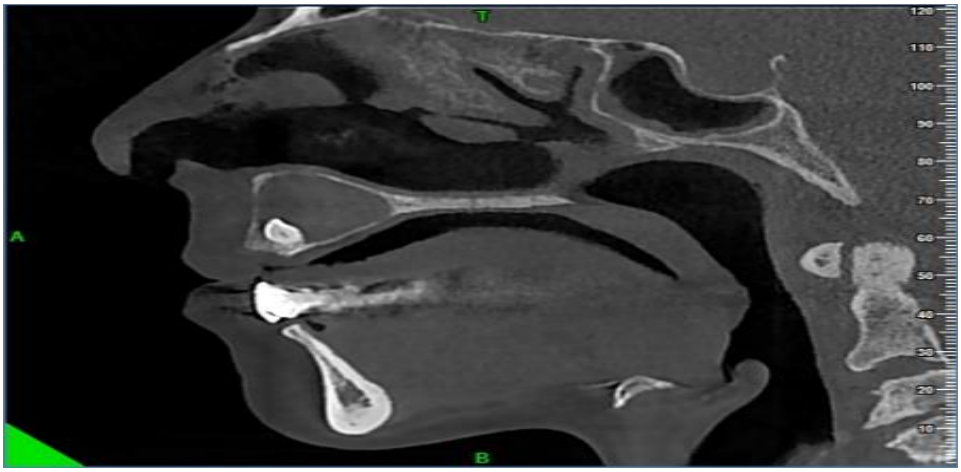

Figure 16: Sagittal view of CBCT showing embedded odontoma into the lesion

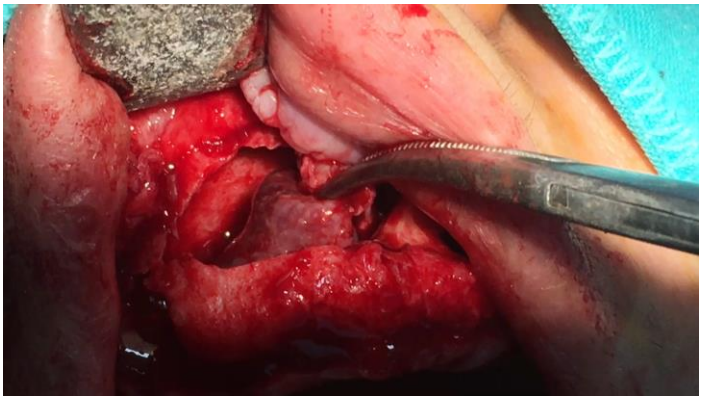

Figure 17: Enucleation of the lesion

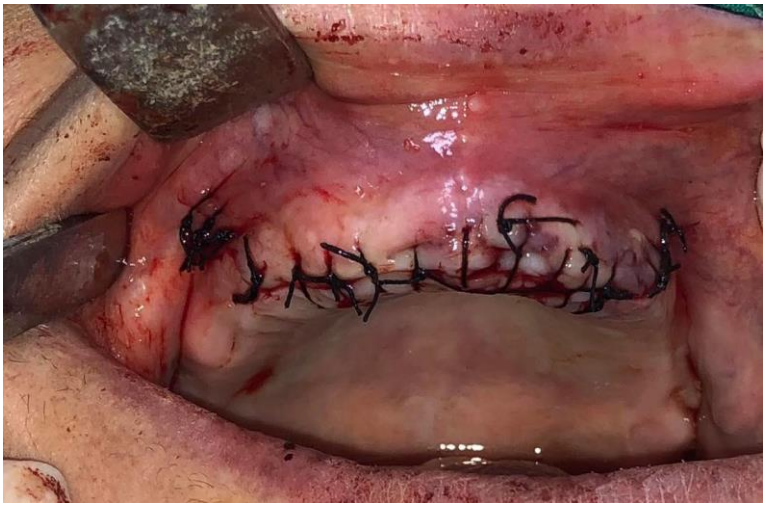

Figure 18: Flap completely closed with 3.0 silk suture

OP- 46

EFFECT OF INJECTABLE PLATELET RICH FIBRIN APPLICATION FOLLOWING ARTHROCENTESIS ON QUALITY OF DAILY LIFE OF TMD PATIENTS

Damla Torul[a], Burak Cezairli[b], Kadircan Kahveci[c]

[a]Ordu University, Faculty of Dentistry, Department of Oral and Maxillofacial Surgery, Ordu, Turkey

damlatorul@odu.edu.tr

[b]Ordu University, Faculty of Dentistry, Department of Oral and Maxillofacial Surgery, Ordu, Turkey

burakcezairli@odu.edu.tr

[c]Ordu University, Faculty of Dentistry, Department of Oral and Maxillofacial Surgery, Ordu, Turkey

kadircankahveci@odu.edu.tr

Abstract

Objectives: Temporomandibular Disorders (TMD) represent various functional changes and pathological conditions that can also affect the joint, masticatory muscles and other components of the maxillofacial system. The aim of this study is to evaluate the effects of Injectible Platalet Rich Fibrin (I-PRF) into the joint capsule after arthrocentesis on the individuals' quality of life using the Mandibula Function Impairment Questionnaire (MFIQ).

Materials and Methods: The patients were divided into two groups as only arthrocentesis-control (9) and I-PRF group (11) which I-PRF injected into the superior joint space after the arthrocentesis. All patients underwent standard arthrocentesis treatment and 1 cc I-PRF was injected for the I-PRF group. Statistical analyses were done using the repeated measures ANOVA test. The comparisons between the groups in each time period were analysed with t-test.

Results: The comparisons within the groups for the MFIQ scores showed significant differences among the 4 measurement points ($P < .05$). Statistically significant differences were also found between the groups for first month ($P = .002$) and third months ($P = .001$) measurements. The other measurements did not show significant differences.

Conclusion: The intra-articular I-PRF injection to be applied following arthrocentesis may be more effective than arthrocentesis alone in terms of the management of TMD in long-term.

Key words: Arthrocentesis, injectable platalet rich fibrin, TMJ

1. Intoduction

Temporomandibular Disorders (TMD) represent various functional changes and pathological conditions that can also affect the Temporomandibular Joint (TMJ), masticatory muscles and other components of the maxillofacial system. (1, 2). While TMD can cause various symptoms such as pain, restricted mouth opening, joint sounds, open and closed locking, it can also negatively affect the quality of life of the individuals. (3).

Disc Displacement with Reduction (DDR) and Disc Displacement without Reduction (DDwR) are commonly seen conditions as condyle-disc incompatibility in TMJ (4). DDR refers to the situation in which the disc is positioned anterior to the condyle in the mouth closed position, with the joint disc slipping completely forward from the space covered or pushed forward by the condyle head. The disc is positioned anterior to the condyle during the opening and closing of the mouth in DDwR (2, 4). If condyle-disc incompatibilities are not treated, the perforation of the disc or the degenerative changes may occur (5). As a result of these non-physiological conditions, the blood supplying of the disc and

surrounding structures is disturbed and intra-articular irregularities increase. Thus, the oxidative radicals arising from these destructions, synovial fluid decreases, pain mediators and cytokinins can be released. (6-8).The purpose of the treatment of TMD is to relieve pain and correct mandibular dysfunction. (9, 10). Temporomandibular joint arthrocentesis, which is the most commonly used minimally invasive technique for the treatment of TMD, is a treatment protocol in which the adhesions and pain mediators are removed by entering the superior joint space (11, 12). It is considered as the primary treatment option especially in cases of unsuccessful conservative treatments and acute closed lock (13). The potential healing effects of Platelet Rich Plasma (PRP) on tissue remodeling, matrix production and cartilage formation have been demonstrated by providing faster cell migration, proliferation and differentiation (14-16). The effects of PRP, which are widely used in the field of maxillofacial surgery, have been reported to have a positive effect on reducing the severity of pain in the patients (17).

Recently, different types of PRF have been developed with different centrifuge procedures to better clinical and physiological effects. Injectable PRF (I-PRF) is an injectable biomaterial obtained with a lower centrifuge speed than PRF. It is claimed that the I-PRF contains more platelets and growth factors compared to the PRF. However, using of this material in injectable form also provides an advantage for different clinical situations. (18).

The aim of this study is to evaluate the effects of I-PRF injection into the joint capsule after arthrocentesis on the individuals' quality of life using the Mandibula Function Impairment Questionnaire (MFIQ).

2. Materials and Methods

The prospective clinical study was carried out with 20 patients who referred to Ordu University Faculty of Dentistry, Department of Dental and Oral Surgery with the complaints of TMJ. The patients were divided into two groups as only arthrocentesis-control (9) and I-PRF group (11) which I-PRF injected into the superior joint space after the arthrocentesis. The inclusion criteria of the study sample were the following: Pain in TMJ and restricted mouth opening, Disc Displacement Without Reduction, aged between 18-40, ASA-I classification according to American Society of Anesthesiology (ASA). The exclusion criteria included: Myofascial pain and dysfunction, acute capsulitis, benign or malignant

TMJ lesions, hematological or autoimmune diseases such as rheumatoid arthritis, TMJ surgery, medication related TMJ, not cooperative patients. The preoperative and postoperative first week, first month and third months measurements were performed using the Mandibular Function Impairment Questionnaire to evaluate the quality of life. Statistical analyses were done using the repeated measures ANOVA test. The comparisons between the groups in each time period were analysed with t-test.

For all groups, the injection area was cleaned with the antiseptic, and then entry points were marked. The first entry point was located 2 mm below the tragus-cantus line, 10 mm in front of the ear, and the second entry point was 20 mm ahead and 6 mm below. The auriculotemporal nerve block was performed with 1/100.000 Articaine Hydrochloride solution containing epinephrine (Ultracain D-S Forte, Aventis, Istanbul, Turkey). The 18 gauge needle was inserted into the superior joint cavity, and the volume of the cavity was expanded with 5 cc isotonic solution for providing the easier procedure. The second 18 gauge needle was inserted through the second entry point and the isotonic solution was released.

The superior joint cavity was irrigated with 100 ml of isotonic solution. All participants were asked for opening their jaw maximally and do basic exercises movement during the procedure. After the arthrocentesis, the second 18 gauge needle at the located anterior entry point was removed and 1 cc I-PRF was injected for the I-PRF group. All patients were informed about the jaw exercises that should do for one week after the procedure.

1.2 Preparing of I-PRF

The blood samples (~ 9.0 mL) were centrifuged immediately with an I-PRF centrifuge system (I-PRF, PRF DUO Gioffredo, Nice, France) to be collected sterile uncoated plastic tubes (Dr. Choukroun Plastic I-PRF Tubes) with 3-minute and 700 rpm. Two layers obtained after centrifuge, the red blood cell and I-PRF were separated. Thus, the remaining liquid platelet-rich fibrin was collected with the help of an 18 gauge needle, and the I-PRF injected into the superior joint space with the needle at the first entry point.

3. Results

A total of 20 patients (Mean age 34.5 ± 13.99) were included in the present study. The preoperative and postoperative first week, first month, third month MFIQ scores recorded. The comparisons within the groups for the MFIQ scores showed significant differences among the 4 measurement points ($P < .05$). Statistically significant differences were also found between the groups for first month ($P = .002$)

and third months (P =.001) measurements. The other measurements did not show significant differences.

4. Discussion

I-PRF contains more platelets and growth factors compared to PRF and is obtained with low centrifugation time. Recently, it has started to be used quite frequently in maxillofacial surgery, and the injectable form also provides an advantage for different clinical situations (19). Abd El Raouf et al. (20) reported that the use of I-PRF significantly increased chondrocyte activity and was more effective in cartilage regeneration compared to PRP. In the in vitro study, Miron et al. (21) stated that I-PRF has been found to have the ability to release higher concentrations of various growth factors and to induce PDGF, TGF and collagen expression with higher fibroblast migration. Also, there is only one study that includes the use of I-PRF to suppress the inflammatory condition caused by intra-articular irregularities, eliminate pain mediators, and synovial fluid damage.

The findings of this pilot study support that I-PRF shows long-term analgesic effects in most patients with painful TMD (6). We aimed to evaluate the effects of I-PRF injection into the joint capsule after arthrocentesis on the individuals' quality of life using the Mandibula Function Impairment Questionnaire.

In the clinical study of Pihut et al. (17), the effects of intra-articular PRP injection have been studied, and it has been reported that PRP has a positive effect on reducing the severity of pain in the patients. In another study, Hancı et al. (18) reported that PRP injection reduces pain intensity and joint sounds and increases maximum mouth opening in the patients with DDR. In this study, it was observed that I-PRF injection effected positively to inflammatory response in TMJ.

5. Conclusion

Although arthrocentesis treatment alone is quite effective in pain elimination in acute periods; it can not rehabilitate the impaired TMJ structure. We think that intra-articular I-PRF injection to be applied following arthrocentesis may be more effective than arthrocentesis alone in terms of the management of TMD in long-term.

6. References

1. Tvrdy P, Heinz P, Pink R. Arthrocentesis of the temporomandibular joint: a review. Biomed Pap Med Fac Univ Palacky Olomouc Czech Repub. 2015;159(1):31-4.

2. Liu F, Steinkeler A. Epidemiology, diagnosis, and treatment of temporomandibular disorders. Dental Clinics. 2013;57(3):465-79.

3. Tatli U, Benlidayi M, Ekren O, Salimov F. Comparison of the effectiveness of three different treatment methods for temporomandibular joint disc displacement without reduction. International journal of oral and maxillofacial surgery. 2017;46(5):603-9.

4. Sanders B, editor Management of internal derangements of the temporomandibular joint. Seminars in orthodontics; 1995: Elsevier.

5. De Riu G, Stimolo M, Meloni SM, Soma D, Pisano M, Sembronio S, et al. Arthrocentesis and temporomandibular joint disorders: clinical and radiological results of a prospective study. International journal of dentistry. 2013;2013.

6. Albilia JB, Vizcaíno CH-, Weisleder H, Choukroun J, Ghanaati S. Liquid platelet-rich fibrin injections as a treatment adjunct for painful temporomandibular joints: preliminary results. CRANIO®. 2018:1-13.

7. Nitzan DW, Marmary Y. The “anchored disc phenomenon”: a proposed etiology for sudden-onset, severe, and persistent closed lock of the temporomandibular joint. Journal of oral and maxillofacial surgery. 1997;55(8):797-802.

8. Israel HA, Langevin C-J, Singer MD, Behrman DA. The relationship between temporomandibular joint synovitis and adhesions: pathogenic mechanisms and clinical implications for surgical management. Journal of oral and maxillofacial surgery. 2006;64(7):1066-74.

9. Karlis V, Glickman R. Nonsurgical management of temporomandibular disorders. Peterson's principles of oral and maxillofacial surgery 2nd ed Hamilton: BC Decker. 2004:949-50.

10. Miloro M, Ghali G, Larsen P, Peterson LJ, Waite P. Peterson's principles of oral and maxillofacial surgery: PMPH-USA; 2004.

11. Nagori SA, Chattopadhyay P, Kumar S, Kamalpathey K. Custom-made mouth prop for TMJ arthrocentesis: a technical note. Oral and maxillofacial surgery. 2017;21(1):75-7.

12. Tozoglu S, Al-Belasy FA, Dolwick MF. A review of techniques of lysis and lavage of the TMJ. British Journal of Oral and Maxillofacial Surgery. 2011;49(4):302-9.

13. Barkin S, Weinberg S. Internal derangements of the temporomandibular joint: the role of arthroscopic surgery and arthrocentesis. Journal (Canadian Dental Association). 2000;66(4):199-203.

14. Anitua E, Andia I, Ardanza B, Nurden P, Nurden AT. Autologous platelets as a source of proteins for healing and tissue regeneration. Thrombosis and haemostasis. 2004;91(01):4-15.

15. Frank C, McDonald D, Shrive N. Collagen fibril diameters in the rabbit medial collateral ligament scar: a longer term assessment. Connective tissue research. 1997;36(3):261-9.

16. Marx RE. Platelet-rich plasma: evidence to support its use. Journal of oral and maxillofacial surgery. 2004;62(4):489-96.

17. Pihut M, Szuta M, Ferendiuk E, Zeńczak-Więckiewicz D. Evaluation of pain regression in patients with temporomandibular dysfunction treated by intra-articular platelet-rich plasma injections: a preliminary report. BioMed research international. 2014;2014.

18. Hancı M, Karamese M, Tosun Z, Aktan TM, Duman S, Savaci N. Intra-articular platelet-rich plasma injection for the treatment of temporomandibular disorders and a comparison with arthrocentesis. Journal of Cranio-Maxillofacial Surgery. 2015;43(1):162-6.

19. Choukroun J, Ghanaati S. Reduction of relative centrifugation force within injectable platelet-rich-fibrin (PRF) concentrates advances patients' own inflammatory cells, platelets and growth factors: the first introduction to the low speed centrifugation concept. European Journal of Trauma and Emergency Surgery. 2018;44(1):87-95.

20. Abd El Raouf M, Wang X, Miusi S, Chai J, Mohamed AbdEl-Aal AB, Nefissa Helmy MM, et al. Injectable-platelet rich fibrin using the low speed centrifugation concept improves cartilage regeneration when compared to platelet-rich plasma. Platelets. 2017:1-9.

21. Miron RJ, Fujioka-Kobayashi M, Hernandez M, Kandalam U, Zhang Y, Ghanaati S, et al. Injectable platelet rich fibrin (i-PRF): opportunities in regenerative dentistry? Clinical oral investigations. 2017;21(8):2619-27.

OP- 48

A NEW TREATMENT APPROACH FOR INFERIOR ALVEOLAR NERVE INJURIES: A PILOT STUDY

Gözde Işık[a], Selin Kenç[b], Tayfun Günbay[c]

A- Ege University, Faculty of Dentistry, Department of Oral and Maxillofacial Surgery, Turkey, gozde.isik@ege.edu.tr

B- Ege University, Faculty of Dentistry, Department of Oral and Maxillofacial Surgery, Turkey, selin.kenc@ege.edu.tr

C- Ege University, Faculty of Dentistry, Department of Oral and Maxillofacial Surgery, Turkey, tayfun.gunbay@ege.edu.tr

Abstract

Objective: The purpose of this present study was to analyze the clinical outcomes of injectable platelet-rich fibrin (i-PRF) injection used in the management of inferior alveolar nerve injuries after surgical interventions.

Materials and Methods: This experimental pilot study was conducted in patients with altered nerve sensation after third molar removal, implant surgery or block bone graft harvesting from mandibular ramus. Injection of i-PRF was performed into mental foramen once a week for a month. Clinical sensory tests (static two-point discrimination (TPD), static light touch (SLT), brush directional stroke (BDS), pinprick (PP), thermal cold discrimination (TCD) and thermal hot discrimination (THD)) were

performed to analyze nerve alterations at preoperatively and 6 months postoperatively. Also, demographic and perioperative variables were noted. Statistical significance was set at .05.

Results: A total of eight patients underwent i-PRF injection. The sensory tests revealed that the positive responces were recorded in SLT, PP and thermal discrimination tests for all patients, while negative responces were occured for TPD and BDS tests in 2 patients (25%). The differences were statistically significant ($p<0.001$ and $p = 0.01$, respectively).

Conclusion: The results of the study showed that i-PRF may be carried out a treatment method in peripheral nerve injuries. Further randomized clinical studies with a large sample are needed to assess the affect of i-PRF on nerve tissue.

Key words: Inferior alveolar nerve; peripheral nerve injuries; injectable platelet-rich fibrin

1. Introduction

Peripheral nerve injuries are clinical complications that can be occur in invasive interventions such as dentoalveolar, implant or orthognathic surgeries, or simple interventions such as local anesthesia (1). These injuries might result in sensory changes such as pain, dysesthesia, paresthesia, hypoesthesia, or anesthesia, and according to the rate of the injuries, speech or taste disturbance can be occur (2).

Peripheral nerve injuries are rare complications (3), however, due to the frequency of surgical procedures, a significant number of patients might affect this complication which reduces the quality of life. Therefore, it is an important factor to the management of treatment protocols.

The purpose of the treatment methods is to repair the function of the damaged nerve, improve the quality of life and reduce neuropathic pain (4,5). Recently, several methods have been introduced for the treatment of peripheral nerve injuries; use of analgesics or vitamins (6); low-level laser therapy for biostimulations (7) or microsurgery (8). These methods seems to improve the clinical findings, however, there is no proof for complete of tissue healing (4).

In the last decades, novel techniques have been presented on nerve injuries by stimulating cell proliferation and migration by use of stem cells or growth factors. Several studies are reported that injectable platelet-rich fibrin (i-PRF) has capability of tissue regeneration within the content of growth factors (15-17).

Based on these results, the purpose of our study was to analyze the clinical outcomes of i-PRF injection in the treatment of inferior alveolar nerve (IAN) injuries after surgical interventions.

2. Materials and Methods

This experimental pilot study was carried out in the Department of Oral and Maxillofacial Surgery from June 2019 to February 2020. The inclusion criteria were as follows; a) inferior alveolar nerve (IAN) injury following third molar surgery, implant surgery or block bone graft harvesting from mandibular ramus; b) sensory loss more than 6 months; c) a platelet count of at least 150,000 mm^3; and d) ability to understand and accept the requirements of the study. The exclusion criteria were as follows; a) any signs of infection in the injection site; b) under 18 years old; c) pregnant or lactating.

All patients were informed about the study protocol and the i-PRF injections were performed following to obtain a written consent form.

2.1. Surgical Protocol

The injection of i-PRF was performed under local anesthesia by a same oral surgeon. Before the injection, the patient's venous blood was collected in a 10-milliliter (mL) tube without anticoagulant, by a surgical nurse. This tube was immediately centrifuged at 700 rpm (50 RCF) for 3 minutes (min) in a special device (EBA 200®, Hettich, Tuttlingen, Germany). Then, 1 mL of i-PRF was collected from the upper part of the tube as described earlier (16).

i-PRF was injected into the mental foramen without pressure. This injection were repeated once a week for a month. All patients were informed about the received paracetamol for pain control, and soft diet was also recommended.

2.2. Data Analysis

Data were analyzed by an examiner blinded to study protocol. Demographic (age and gender) and perioperative variables (the duration of blood collection, anesthesia and injection) were noted for each patient.

Sensory changes were evaluated by using clinical sensory tests as described earlier (18,19). Six different sensory tests were carried out, three times for each evaluation area, onthe chin, as follows: two-point discrimination (TPD), static light touch (SLT), brush directional stroke (BDS), pinprick (PP), thermal cold discrimination (TCD) and thermal hot discrimination (THD). The tests were performed to analyze nerve alterations at preoperatively and 6 months postoperatively. As an additional source of information, direct questions were addressed to the patients to assess reductions in nerve sensation in the lower lip and chin. All answers were noted with simple choice options such as 'yes' or 'no' to record the patients' own experience of their current state. Those findings were compared with the clinical tests.

2.3. Statistical Analysis

Statistical analysis was performed using the IBM SPSS Statistics 25.0 programme (IBM SPSS Statistics for Windows, Version 25.0. Armonk, NY: IBM Corp.). McNemar test was used to analysis of the sensory changes. Data were summarized as a mean, standard deviation, frequency and percentage (%). Statistical significance was set at .05.

3. Results

A total of eight patients (1 male, 7 female; age range 38-56; mean age 47.4 ± 4.8) underwent i-PRF injection. Sensory changes were reported as follows; three patients (37.5%) after third molar surgery; three patients (37.5%) after implant surgery and two patients (25%) after block bone graft harvesting from the mandibular ramus. Of the 8 patients, 5 (62.5%) had hypoesthesia, 1 (12.5%) had dysesthesia and 2 (25%) had paresthesia in IAN.

A total of 32 i-PRF injectons were performed and there was no signs of infections such as pain or erythema. No differences were reported in the duration of blood collection, anesthesia and injection (a mean score of 2.3 and 2.5 minutes) as perioperative variables.

As a result of the sensory tests, negative responses were observed for each patient prior to i-PRF injection. At postoperatively 6 months, positive responses with SLT, PP and thermal dicrimation tests were recorded for each patient. The difference was statistically significant ($p<0.001$). There was negative responses with TPD and BDS tests for two patients (25%) who had paresthesia, while positive

responses were recorded for six patients. This difference was statistically significant ($p = 0.01$). Data of the sensory tests were summarized (Table 1).

4. Discussion

Recently, several studies have been reported the use of stem cells and growth factors for nerve tissue repair and regeneration (9-14). The injection of growth factors is a physiologically approvable method as a treatment of peripheral nerve injuries (14). Many studies have been reported that the injection of growth factors presents the promising results to regeneration of IAN. However, the injected growth factors are easily and shortly metabolized (12). Moreover, this method might result in secondary trauma, inflammation, local damage, and pain, possibly even infection, at the injection site (12). Therefore, the use of platelet concentrates, which can prolong the duration of release of growth factors without side effects, might be an alternative treatment method (17).

Based on these results, our study demonstrated that positive responses were recorded with i-PRF injection and no complications were noted during or after the injections. Therefore, this result suggessted that i-PRF injection can be used as a reliable method in order to ensure the regeneration of IAN.

The injection of growth factors has been reported to improve sensory innervation by accelerating nerve regeneration (12,13). Du et al. (12) reported that growth factors given systemically can accelerate the recovery of the inferior alveolar nerve in rabbits after mandibular distraction osteogenesis. Similarly, Wang et al. (13) reported that growth factor injection might provide the regeneration in nerve fibers and accelerate the morphological recovery of the IAN in the early period. Consistent with these results, our study showed that after i-PRF injection, positive responses were recorded for 6 patients who had hypoesthesia and dysesthesia. Although, i-PRF presents an effective results on nerve regeneration, it is important to support with histological analysis.

As a contrary, Hergt et al.(14) reported that regeneration of the IAN with the injection of growth factors is possible, but without achieving preoperative thresholds. The results of our study demonstrated that negative responses with TPD and BDS tests in two patients had paresthesia, might be result of the failure to achieve the required threshold level for sensory innervation. Moreover, before the injections, sensory changes were classified with clinical findings, but no additional analyze was performed to observe the rate of nerve damage, radiographically. Therefore, this factor could be affecting on the clinical outcomes.

Some limitations of the study have to be addressed. The number of the participants was too small to generalize the results of the study. Also, the data on the clinical effect of i-PRF was limited, since there was no control group in the study. Therefore, further studies with a large sample are needed to analyze clinical results of i-PRF and improve these findings.

5. Conclusion

The results of the study showed that i-PRF may be carried out a treatment method in peripheral nerve injuries. Further randomized clinical studies with a large sample are needed to assess the affect of i-PRF on nerve tissue.

6. References

1. Akal, U.K., Sayan, N.B., Aydogan, S., Yaman Z. Evaluation of the neurosensory deficiencies of oral and maxillofacial region following surgery. Int J Oral Maxillofac Surg 2000: 29:331-336.

2. Schultze-Mosgau, S., Reich, R.H. Assessment of inferior alveolar and lingual nerve disturbances after dentoalveolar surgery, and of recovery of sensitivity. Int J Oral Maxillofac Surg. 1993: 22:214-217.

3. Kushnerev, E., Yates, J.M. Evidence-based outcomes following inferior alveolar and lingual nerve injury and repair: a systematic review. J Oral Rehabil. 2015: 42:786-802.

4. Zochodne, D.W. The challenges and beauty of peripheral nerve regrowth. J Peripher Nerv Syst. 2012: 17:1-18.

5. Scheib, J., Höke, A. Advances in peripheral nerve regeneration. Nat Rev Neurol. 2013;9:668-676.

6. Kang, W.B., Chen, Y.J., Lu, D.Y., Yan, J.Z. Folic acid contributes to peripheral nerve injury repair by promoting Schwann cell proliferation, migration, and secretion of nerve growth factor. Neural Regen Res. 2019: 14:132-139.

7. Seo, N.R., Lee, S.H., Ju, K.W., Woo, J.M., Kim, B.J., Kim, S.M., Jahng, J.W., Lee, J.H. Low-

frequency pulsed electromagnetic field pretreated bone marrow-derived mesenchymal stem cells promote the regeneration of crush-injured rat mental nerve. Neural Regen Res. 2018: 13:145-153.

8. Bagheri, S.C., Meyer, R.A., Cho, S.H., Thoppay, J., Khan, H.A., Steed, M.B. Microsurgical repair of the inferior alveolar nerve: success rate and factors that adversely affect outcome. J Oral Maxillofac Surg. 2012: 70:1978-1990.

9. Saez, D.M., Sasaki, R.T., Martins, D.O., Chacur, M., Kerkis, I., da Silva, M.C.P. Rat Facial Nerve Regeneration with Human Immature Dental Pulp Stem Cells. Cell Transplant. 2019: 28:1573-1584.

10. Boldyreva, M.A., Bondar, I.V., Stafeev, I.S., Makarevich, P.I., Beloglazova, I.B., Zubkova, E.S., Shevchenko, E.K., Molokotina, Y.D., Karagyaur, M.N., Ratner, E.I., Parfyonova, Y.V. Plasmid-based gene therapy with hepatocyte growth factor stimulates peripheral nerve regeneration after traumatic injury. Biomed Pharmacother. 2018: 101:682-690.

11. Byun, J.H., Lee, J.H., Choi, Y.J., Kim, J.R., Park, B.W. Co-expression of nerve growth factor and p75 NGFR in the inferior alveolar nerve after mandibular distraction osteogenesis. Int J Oral Maxillofac Surg. 2008: 37:467–472.

12. Du, Z.J., Wang, L., Lei, D., Liu, B., Cao, J., Zhang, P., Ma, Q. Nerve growth factor injected systemically improves the recovery of the inferior alveolar nerve in a rabbit model of mandibular distraction osteogenesis. Br J Oral Maxillofac Surg. 2011: 49:557-561.

13. Wang, L., Zhao, Y., Cheng, X., Yang, Y., Liu, G., Ma, Q., Shang, H., Tian, L., Lei, D. Effects of locally applied nerve growth factor to the inferior alveolar nerve histology in a rabbit model of mandibular distraction osteogenesis. Int J Oral Maxillofac Surg. 2009: 38:64-69.

14. Hergt, A.C., Beck-Broichsitter, B.E., Raethjen, J., Kaser, N., Hülsmann, M., Wiltfang, J., Heine, J., Becker, S.T. Nerve regeneration techniques respecting the special characteristics of the inferior alveolar nerve. J CranioMaxilloFac Surg. 2016: 44:1381-1386.

15. Miron, R.J., Fujioka-Kobayashi, M., Hernandez, M., Kandalam, U., Zhang, Y., Ghanaati, S., Choukroun, J. Injectable platelet rich fibrin (i-PRF): opportunities in regenerative dentistry? Clin Oral Investig. 2017: 21:2619-2627.

16. Choukroun, J., Ghanaati, S. Reduction of relative centrifugation force within injectable platelet-rich-fibrin (PRF) concentrates advances patients' own inflammatory cells, platelets and growth factors: the first introduction to the low speed centrifugation concept. Eur J Trauma Emerg Surg. 2018: 44:87-95.

17. Fujioka-Kobayashi, M., Miron, R.J., Hernandez, M., Kandalam, U., Zhang, Y., Choukroun, J. Optimized platelet rich fibrin with the low speed concept: growth factor release, biocompatibility and cellular response. J Periodontol. 2017: 88:112-121.

18. Noia, C.F., Ortega-Lopes, R., Olate, S., Duque, T.M., de Moraes, M., Mazzonetto, R. Prospective clinical assessment of morbidity after chin bone harvest. J Craniofac Surg. 2011: 22:2195-2198.

19. Poort, L.J., van Neck, J.W., van der Wal, K.G.H. Sensory testing of inferior alveolar nerve injuries: A review of methods used in prospective studies. J Oral Maxillofac Surg. 2009: 67:292-300.

7. Tables

Table 1: Sensory test results

	Mechanoceptive tests			Nociceptive tests		
Evaluation	TPD† (n=8)	SLT‡ (n=8)	BDS§ (n=8)	PP¶ (n=8)	TCD†† (n=8)	THD‡‡ (n=8)

Preoperatively	-	-		-	-	-
6th month	6 (75%)	8 (100%)	6 (75%)	8 (100%)	8 (100%)	8 (100%)
P	0.01	<0.001	0.01	<0.001	<0.001	<0.001

Abbreviations: n: number; %: percentage; †: two-point discrimination; ‡: static light touch; §: brush directional stroke; ¶: pinprick; ††: thermal cold discrimination; ‡‡: thermal hot discrimination.

OP-51

DEMOGRAPHIC CHARACTERISTICS AND ETIOLOGICAL FACTORS OF 374 CASES WITH MAXILLOFACIAL FRACTURE: A 11 YEAR RETROSPECTIVE STUDY

Rıdvan Güler[a], Kamil Serkan Ağaçayak[b]

A- Dicle University, Faculty of Dentistry, Department of Oral and Maxillofacial Surgery, Turkey, ridvanguler06@gmail.com

B- Dicle University, Faculty of Dentistry, Department of Oral and Maxillofacial Surgery, Turkey, serkanagacayak@gmail.com

Abstract

Objective: The purpose of this retrospective study was to evaluate and discuss the demographic distribution and treatment methods of patients with maxillofacial fracture who admitted to the Dicle University, Faculty of Dentistry, Deparment of Oral and Maxillofacial surgery due to trauma between 2008-2019.

Materials and Methods: The file documents of 374 maxillofacial trauma cases admitted to our clinic were collected and examined. The data obtained were analyzed according to gender, age, etiology, season, anatomical localization and treatment options.

Results: As a result of statistical analysis, 400 maxillofacial fractures were detected in 374 patients, of whom 257 (68.7%) were male and 117 (31.3%) were female. The mean age was 25 (7-68) years. When etiological causes were listed, fall was in the first place with 129 patients (34.5%). Then, respectively, interpersonal violence with 124 patients (33%), traffic accident with 69 patients (18.4%), sports accident with 21 patients (5.6%), occupational accident with 12 patients (3.2%), horse kick with 12 patients (3.2%), gunshot wounds with 4 patients (1%) and jaw fractures that occured after tooth extraction with 3 patients (0.8%) were among the etiological causes. Of the 400 fractures treated, 334 (83%) were seen in the mandible, 46 (11%) were in the maxilla, 3 (1%) were in the zygomatic bone, 3 (1%) were in the orbit and finally 14 (4%) were multiple fractures.

Conclusion: The incidence, etiology and demographic characteristics of maxillofacial fractures vary according to regions.

Key Words: Etiology, Maxillofacial fractures, Retrospective study

1. Introduction

Maxillofacial traumas have become an important health problem frequently encountered at the present day. While a portion of the patients exposed to trauma isolated maxillofacial fracture patients, an important part of them are patients with multitrauma. Fractures in the maxillofacial area cause aesthetic changes in the patient's facial appearance. If it is not treated or if wrong treatments are applied, it may cause important functional and aesthetic problems. When the literature on maxillofacial trauma is reviewed, the common opinion reached in terms of etiology is that traffic accidents take the first place. (1)

The etiology and incidence of maxillofacial fractures depend on social, cultural, economic and environmental factors and differ between the regions where they live. Fracture of the nasal bone is the most common result of maxillofacial trauma.(2) This is followed by mandible, zygomatic bone and maxilla fractures, respectively.(2,3) Looking at the age distribution of patients with maxillofacial fractures, it is seen that most of them are over 25 years old. (3) If in the pediatric age group, the number of patients is quite low.

The diagnosis of maxillofacial fracture is made by physical examination, direct radiography and computed tomography (CT). CT, which has become widespread recently, reveals the fracture lines much more clearly. For treatment, reduction and fixation of the fracture is required after the general condition of the patient stabilizes. (4) The treatment may vary depending on the type of fracture, its location, the age of the patient, the condition of the teeth, whether there is a systemic disease, and the time from fracture formation to treatment. (5)

2. Materials and Methods

The medical records of patients who were examined in our clinic between January 2008 and January 2019, diagnosed and treated in the light of clinical and radiological findings were examined. Data on gender, age, etiology, season, anatomical location and treatment options of the patients were recorded. Fractures were divided into mandible, maxilla, zygoma, orbital and multiple fractures according to the bone. These were also reclassified as corpus, symphysis, parasymphysis, ramus, condyle, angulus, lefort, tuber and complicated fractures according to their anatomical localization. Etiological reasons were classified as falling, assault, traffic accidents, sports accidents, occupational accidents, horse recoil, gunshot injury and jaw fracture after tooth extraction. Treatments were basically classified into 2 groups as closed reduction and open

reduction. Closed reduction treatment was divided into two groups as internal maxillary fixation (IMF-Archbar) and ıvy loop ligature treatments.

3. Results

Medical records of 400 maxillofacial fractures in 374 patients treated in our Oral and Maxillofacial Surgery clinic between January 2008 and January 2019 were examined. The patients were classified and analyzed according to gender, age, etiology, season, anatomical location and treatment options. 257 of the patients were male (68.7%) and 117 were female (31.3%). The average age of the patients was 25, and the youngest was 7 years old and the oldest was 68 years old. While the average female age was 28, the average male age was 26 (Figure 1). When etiological reasons were investigated, falling took the first place with 129 patients (34.5%). Subsequently, assault with 124 patients (33%), traffic accident with 69 patients (18.4%), sports accident with 21 patients (5.6%), work accident with 12 patients (3.2%), 12 patients (3.2%) with horse rebound, 4 patients (1%) with gunshot injuries, and finally, 3 patients (0.8%) had jaw fractures after tooth extraction (Figure 2). Considering the seasons and months in which the trauma occurred, it was observed that the trauma was more common in July - August. Then the months of March, May and September come in order.

Of the 400 treated fractures, 334 (83%) were seen in the mandible, 46 (11%) in the maxilla, 3 (1%) in the zygomatic bone, 3 (1%) in the orbit, and finally 14 (4%) were seen as multiple fractures. (Figure 3). Angulus fractures were determined as the most common localization in mandibular fractures according to localization with 85 patients (23%). In order of frequency, other localizations in the mandible were condyle 65 (18%), parasymphysis 62 (17%), symphysis 61 (16%), corpus 32 (9%), ramus 16 (4%) and other fractures 13 (1%). ın maxilla fractures, it was analyzed that there were maxillary segmental fractures in 25 (7%), maxillary alveolar fractures in 14 (4%), tuber fractures in 4 (1%) and lefort 1 fractures in 3 (1%) patients (Figure 4). 244 of the patients were treated with closed reduction. It was found that 225 of them were treated with the intermaxillary fixation method (IMF-Archbar) and 19 of them with ıvy loop ligatures. 77 patients were treated with open reduction (Miniplak and Vida). Apart from these, 2 of 3 zygoma fracture patients were treated with Gillies technique and 1 with Hook traction. Barton bandage was recommended for 1 patient. No treatment was applied to 49 patients, a soft diet and follow-up were recommended (Figures 5, 6). Except for patients who underwent closed reduction, all patients were operated under general anesthesia. Only closed reduction was applied in condyle fractures that did not damage the joint and non-displaced fractures in which occlusion was preserved. In the statistical analysis, the effect of the etiology and the treatment options applied on the genders was examined and a significant difference was found (Table 1-2).

4. Discussion

The distribution of maxillofacial fractures according to gender male to female varies between 2: 1 and 9: 1. (6) We think that this is due to the fact that the male population is more in an outdoor environment and the probability of encountering etiological factors such as traffic accidents and assault is high. When we look at the distribution of patients by gender in our study, it was seen that 257 patients (69%) were male and 117 patients (31%) were female. This overlaps with previous studies. (4,7,8) In the literature studies, it has been reported that maxillofacial fractures are more common in the 20-30 age group. (7,9) In our study, similar to the literature, we determined the average age of patients with fractures as 25. While the average female age was 28, the average male age was 26.

When the current literature is examined, traffic accidents, beating and falling are among the most important etiological factors. (4,10,11) It has been shown that these etiological factors are affected by the socioeconomic, cultural and environmental factors of the country. While the traumas due to traffic accidents are less visible in developed countries, traffic accidents take the first place in the etiology of maxillofacial fractures in developing countries. In our study, falling took the first place with 129 patients (35%). With 124 patients (33%), battering took the second place etiologically. Then come traffic accident and other etiological reasons.

In another study in which Erol and Ark examined 2308 cases with maxillofacial fractures, 79.1% of the patients were male, 20.9% were female, and the age range frequencies were 0-10 years (27.4%), 21-30 years (26.9%), 11-20 years (18.8%) and 31-40 years (14.7%). They reported that 71.9% of these patients had fractures in the mandible and 9.8% in the maxilla. They reported that 34.3% of the fractures in the mandible occurred in the corpus, 23.6% in the symphysis, 19.5% in the condyle and 14% in the angulus mandible. (9)

In our study, a total of 400 fractures were detected in 374 patients. When we examine the distribution of the observed fractures, it was determined that 83% occurred in the mandible. This ranking is followed by the maxilla with 11%. This result is in agreement with the results of other studies. In our study, when we list the mandibular fractures according to their localization, angulus fractures are in the first place with 85 patients and condyle fractures are in the second place with 65 patients. These are followed by parasymphysis (n = 62), symphysis (n = 1), corpus (n = 32), ramus (n = 16) fractures.

5. Conclusion

The incidence, etiology and demographic characteristics of maxillofacial fractures vary according to regions. We think that multicentre studies involving fields with geographic, social and economic variables will contribute to both the treatment of patients and the literatüre by providing a more detailed understanding of the differences between regions.

6. References

1. Arden R, Mathog RH. Maxillary fractures. In: PaparellaMM, ed. Otolaryngology. Vol 4. 3th ed. Philedelphia: WB Saunders; 1991. p.2927-38
2. Dierks EJ. Mandibular fractures. In: Bailey BJ, ed. Head & Neck Surgery-Otolaryngology. Vol 1. Philedelphia: JB Lippincott Company; 1993. p.961-72.
3. Thaller SR. Management of mandibular fractures. Arch Otolaryngol Head Neck Surg 1994; 120(1):44-8.
4. Özgül Ö. Çene yüz kırıklarının demografik özellikleri ve etiyolojik faktörleri: Retrospektif çalışma. Selcuk Dent J, 2018; 5: 67-72
5. Mackay, IS. Bul, TR. Fractures of the facial skeleton. Scott-Brown's Otolaryngology Rhinology. V ol.4. 6th ed. London: ButterworthHeinemann; p.1-32.
6. Boffano P, Roccia F, Zavattero E et al. European Maxillofacial Trauma (EURMAT) project: a multicenter and prospective study. J Craniomaxillofac Surg 2015; 43: 62-70.
7. Erol B, Tanrikulu R, Görgün B. Maxillofacial fractures. analysis of demographic distribution and treatment in 2901patients (25-year experience). J Cranio-Maxillofacial Surg 2004; 32: 308–13.
8. Yaman F, Atılgan S, Yılmaz N, Görgün B. Mandibular kondil fraktürleri: Retrospektif analiz. Turkiye Klinikleri J Dental Sci 2007;13:48-54.
9. Erol B, Özer N, Tanrıkulu R, Gülsün B, Atay Ç. Maksillo-fasiyal fraktürler: 2308 olgu ile ilgili retrospektif bir çalışma. Ulus Travma Acil Cerrahi Derg 1998;4:162-67.
10. Komut S, Sönmez BM, Erenler AK, Komut E. Clinical and Demograhical Characteristics of Patients with Maxillofacial Trauma in the Emergency Department. Open Journal of Emergency Medicine, 2019 7, 28-39.
11. Hoşgör H, Coşkunses FM, Kan B. Evaluation of maxillofacial fracture cases: A retrospective study. Yeditepe J Dent, 2019

7. Figures

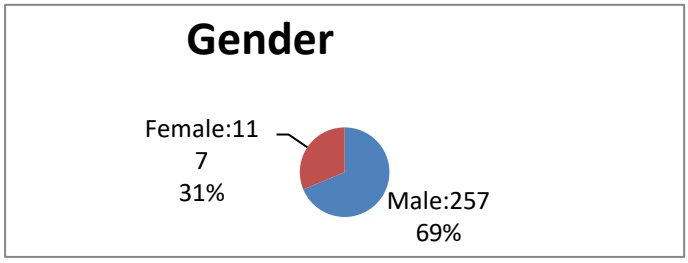

Figure 1: Distribution of 374 patients with maxillofacial fractures by gender

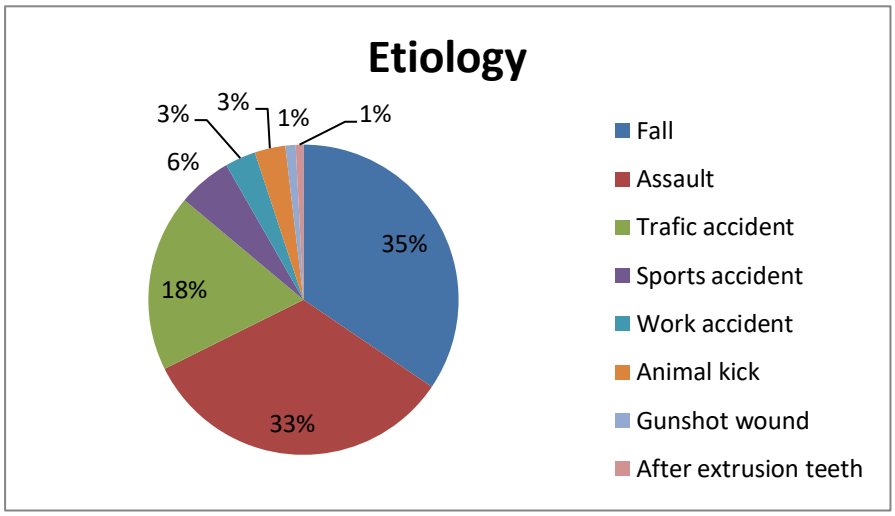

Figure 2: Etiological distribution of 374 maxillofacial fracture

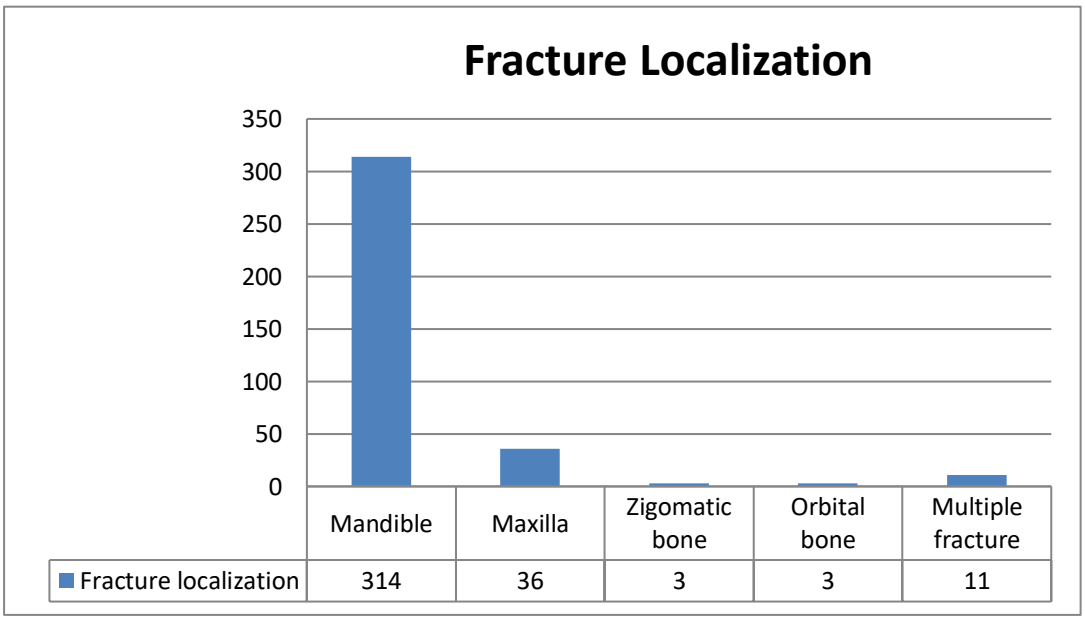

Figure 3: Distribution of 374 patients with maxillofacial fractures according to their anatomical location

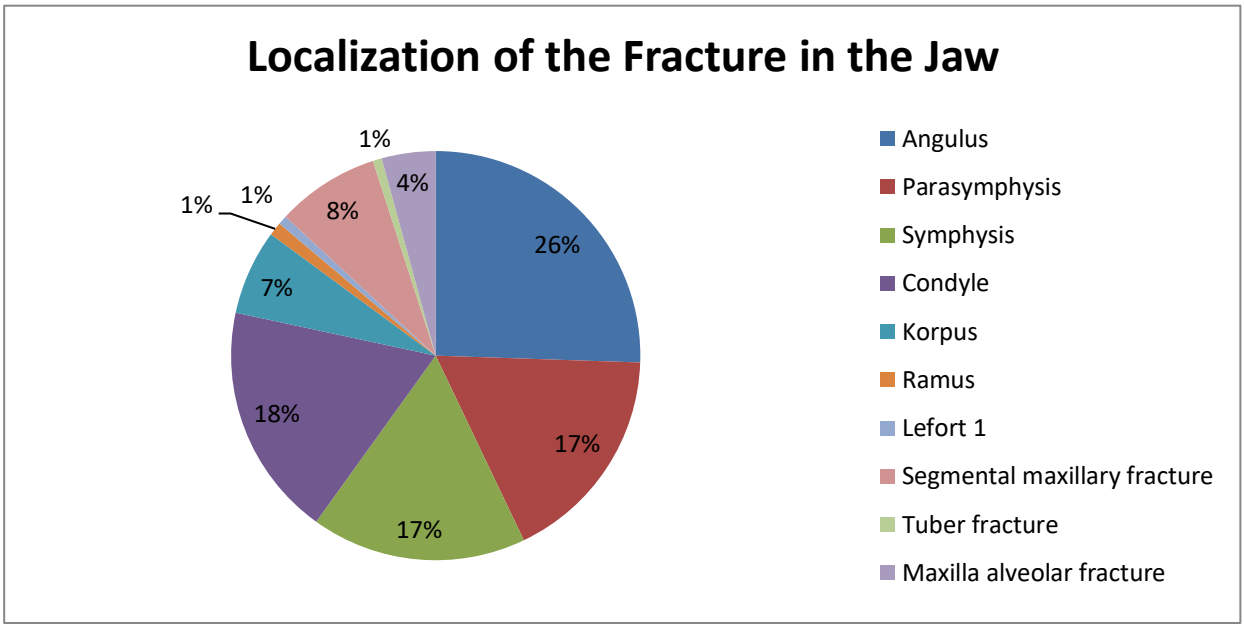

Figure 4: Distribution of 374 patients with maxillofacial fracture localization in the jaws

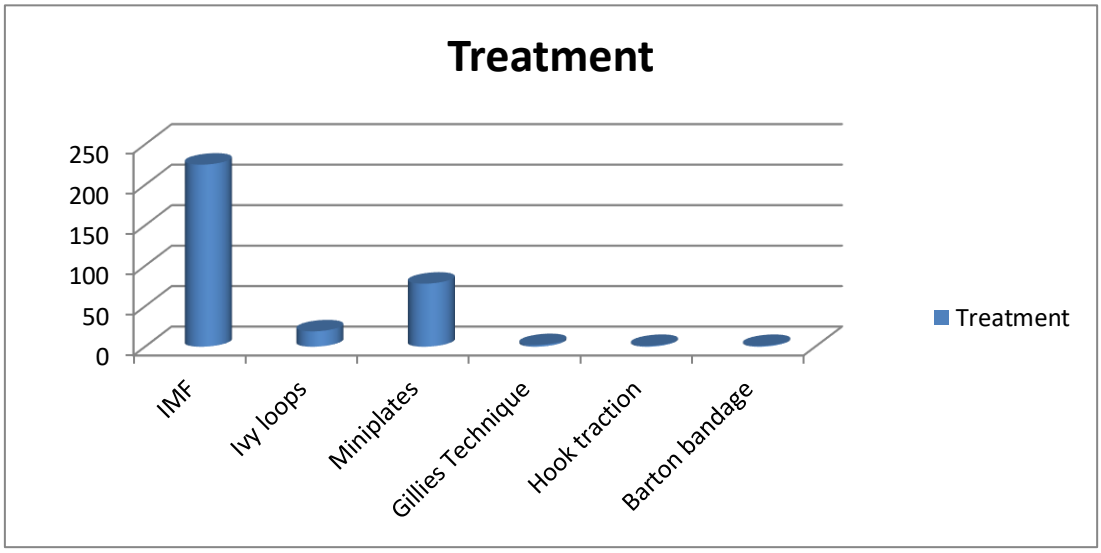

Figure 5: Distribution of 374 patients with maxillofacial fractures according to treatment types

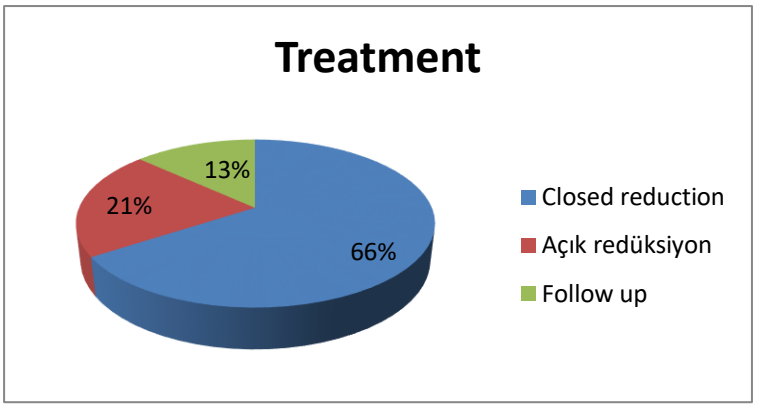

Figure 6: Distribution of 374 maxillofacial fractures according to reduction types

7. Tables

	Male (257, % 68,7)		Female (117,% 31,3)		P
Assault	94	36,5	30	25,6	0.006
Fall	76	29,5	53	45,3	
Trafic accident	51	19,8	18	15,3	
Sports accident	15	5,8	6	5,1	
Work accident	12	4,6	0		
Animal kick	6	2,3	6	5,1	
Gunshot wound	2	0,7	2	1,7	
After extrusion teeth	1	0,3	2	1,7	

Table 1: Changes between the sexes according to their etiology

	Male (257, % 68,7)		Female (117,% 31,3)		P
Follow up	32	12,4	17	14,5	0.331
IMF	150	58,3	75	64,1	
Mini Plate+Screws	58	22,5	19	16,2	
Ivy loop	15	5,8	4	3,4	
Barton Bandage	0		1	0,8	
Gillies Technique	1	0.3	1	0,8	
Hook Traction	1	0,3	0		

Table 2: Treatment differences according to gender

OP-54

ORTHOGNATHIC SURGERY: CASE SERIES

Hilal Türker Alan [a], Ayşegül Evren [b], Burak Ünlütürk [c]

A- Inonu University, Faculty Of Dentistry, Department Of Oral And Maxillofacial Surgery, Turkey, hilalturker@hotmail.com

B- Inonu University, Faculty Of Dentistry, Department Of Orthodontics, Turkey, ayseguldalkilic@hotmail.com

C- Inonu University, Faculty Of Dentistry, Department Of Oral And Maxillofacial Surgery, Turkey, burak.unluturknonu.edu.tr

Abstract

Objectives: Orthognathic surgery is a frequently used procedure for the treatment of skeletal angle class II and III deformities, dentomaxillofacial deformities and maxillofacial asymmetries. It is also possible providing aesthetic facial contour and ratio, correcting dental malocclusion, and treating obstructive sleep apnea via orthognathic surgery. Orthognathic surgical complications have been reported at a very low rate and are generally considered reliable.

Cases: Skeletal deformities were detected in clinical and radiographic examinations of patients who applied to our faculty with dysfunction in their jaws and aesthetic complaints. After orthodontic treatments, it was decided to operate the patients under general anesthesia. Bimaxillary osteotomy was performed in 4 patients and bilateral sagittal split ramus osteotomy was performed in 1 patient. At least six months before the operation, impacted wisdom teeth extractions on osteotomy line were performed. After the operation, the patients were hospitalized and followed up.

Results: Correction of function and occlusion and temporomandibular joint mechanics are basic concepts for success in orthognathic surgery applications. The compatibility of the surgeon and the orthodontist and the involvement of the patient in this team work bring the postoperative expectations to a more reasonable level.

1. Introduction

Orthognathic surgery is a treatment applied for the treatment of skeletal angle class II and III deformities, dentomaxillofacial deformities and maxillofacial asymmetries, however, requires multidisciplinary work. of the orthodontist and surgeon (1). Orthognathic surgical treatment is generally the first option in patients with advanced skeletal disorders that have completed their growth and development (2). In orthognathic surgery, optimization of function and occlusion and temporomandibular joint mechanics are basic concepts. Skeletal changes can be achieved with functional orthodontic treatment during the growth and development period. However, orthodontic treatment is not sufficient for skeletal change in adult individuals, and reposition of the jaws may be required surgically (3). Le Fort I osteotomy, bilateral sagittal split osteotomy and osseous genioplasty constitute orthognathic surgical procedures (4).

2. Case Report

Clinical and radiological examinations of 5 patients who applied to Inonu University Faculty of Dentistry with dysfunction and aesthetic complaints in their jaws were performed in the orthodontic clinic and oral and maxillofacial surgery clinic. All patients had skeletal angle class III malocclusion (Figures 1a,1b,2a,2b,3a,3b,4a,4b,5a,5b). Patients were treated with surgery intermediate treatment procedure. According to this practice, patients received orthodontic treatment before and after surgery. On the 2. postoperative day, maxillomandibular fixation was performed using orthodontic tires and continued for an average of 4 weeks.

Surgical procedure: Only one patient was performed mandible osteotomy, and the other patients had bimaxillary osteotomy. The operations were performed under general anesthesia with endotracheal intubation. Local anesthetics with vasoconstrictor content were performed in related areas for bleeding control. In Le Fort I osteotomy, soft tissue incision was performed between the upper first molar teeth about 4 mm above teeth roots by preserving the infraorbital vascular neurovascular bundle with monopolar electrocautery and a 15 blade. The full thickness flap was removed. Osteotomy line was signed with a pen or bur at least 5 mm superior to canine rooth apex. Nasal mucosa epithelium was removed with a periosteal elevator.

Osteotomy was performed from the pterygomaxillary junction to the edge of the apertura priformis using a surgical saw. Subsequently, vertical osteotomy was performed with a combination of curved tip osteotomes on pterygomaxillary junction. The same osteotomies were performed on the contralateral side. The nasal mucosa was removed posteriorly and horizontal osteotomies were performed on the medial nasal wall with nasal osteotomes. Downfracture was provided with a bone hook. Maxilla was mobilized with rowe forceps. The intermediate splint was attached to the jaws with orthodontic wires. In the new position of the maxilla, rigid fixation was achieved with miniplates and screws. The intermediate plate was removed and bilateral sagittal split ramus osteotomy was started. Soft tissue incision was made up to the first molar distal with electrocautery and scalpel, with reference to the ramus anterior and external oblique linea. The full-thickness flap was removed from the external oblique linea to the coronoid notch. The dissection was made from the mandible basis to the posterior border of the ramus. After the soft tissue dissection was completed, a retractor was placed in medial border of the ramus to protect the inferior alveolar neurovascular bundle and provide surgical vision. Horizontal osteotomy was performed with surgical handpiece parallel to occlusal plane from above lingula in medial border of ramus mandible. The osteotomy was continued from external oblique linea to second molar level with piezosurgery device. Vertical osteotomy was performed at second molar tooth level up to the basis of mandible. Finally, distal and proximal segments were carefully separated by osteotomes. Same procedures were applied on contralateral side. The prepared final splint was attached to jaws and fixed to new position of mandible with miniplates and screws. Wound regions were disinfected with Baticon solution. Primary wound closure was achieved. There was no intraoperative and postoperative complication.

Case 1: A healthy 27-year-old woman underwent bimaxillary surgery after orthodontic treatment. Maxillary advancement was 2 mm and impaction was 2 mm. Mandibulary setback was 5 mm. After surgery, patient's orthodontic treatment was continued (Figures 1c,1d).

Case 2: A healthy 23-year-old woman underwent bimaxillary surgery after orthodontic treatment. Maxillary advancement was 6 mm and impaction was 4 mm. Mandibulary setback was 3 mm. After surgery, patient's orthodontic treatment was continued (Figures 2c,2d).

Case 3: A healthy 22-year-old woman underwent only bilateral sagittal split ramus osteotomy after orthodontic treatment. Mandibulary setback was 9 mm. Orthodontic treatment had continued after surgery (Figures 3c,3d).

Case 4: A healthy 22-year-old male patient underwent bimaxillary surgery after orthodontic treatment. Thus, 4 mm advancement, 4 mm impaction on the right side, 3 mm impaction on the left side and 2 mm left rotation were performed in maxilla. Right rotation and counterclockwise rotation were performed in mandible. Orthodontic treatment of the patient continued after surgery (Figures 4c,4d).

Case 5: A systemically healthy 26-year-old male patient underwent bimaxillary surgery after orthodontic treatment. Maxilla was 3 mm advanced and 8 mm mandibulary setback was performed. Afterwards, orthodontic treatment continued (Figures 5c,5d).

3. Discussion

Orthognathic surgery for dentofacial deformities is a treatment that requires the reposition of the dental and skeletal components with bimaxillary surgery in order to ensure the function and aesthetics of these components of the face. In our study, only mandibular osteotomy was performed in one of our cases and bimaxillary osteotomy was performed in the others (5). In bimaxillary osteotomies, the issue of which jaw will be repaired first is controversial (6). In our cases, we preferred to perform Le Fort I osteotomy firstly.

Orthognathic surgical treatment is mainly used for surgery intemediate, where orthodontic treatment is applied before and after surgery; and surgery first, which is performed before orthodontic treatment, is divided into two (7). All of our cases were treated according to surgery intermediate procedure.

Removal of the third molar teeth are usually done a few months before orthognathic surgery. However, it has been reported that simultaneous removal with surgery does not increase duration of surgery, does not increase risk of negative results, and does not cause a poor course of postoperative (8). In our cases, we prefered necessary teeth removal 6 months before surgery.

4. Conclusion

Orthognathic surgery is a popular treatment method used only for adults with dentofacial deformity where orthodontic treatment is not sufficient (9). Treatment plan is issued after detailed clinical and radiological examination. The compatibility of surgeon and orthodontist and involvement of the patient in this team work bring postoperative expectations to a more reasonable level.

5. References

1. Jędrzejewski M, Smektała T, Sporniak-Tutak K, Olszewski R. Preoperative, intraoperative, and postoperative complications in orthognathic surgery: a systematic review. Clin Oral Investig. 2015: 19(5):969–77.

2. Bishara SE, Burkey PS, Kharouf JG. Dental and facial asymmetries: a review. Angle Orthodontist. 1994: 64:89–98.

3. Zhou Y, Hägg U, Rabie A. Patient satisfaction following orthognathic surgical correction of skeletal Class III malocclusion. Int J Adult Orthodon Orthognath Surg. 2001: 16(2):99–107.

4. Steinhauser EW. Historical development of orthognathic surgery. 1996. Vol. 24, J Cranio Maxillofac Surg. 1996: 24(4):195–204.

5. Sonego CL, Bobrowski ÂN, Chagas OL, Torriani MA. Aesthetic and functional implications following rotation of the maxillomandibular complex in orthognathic surgery: a systematic review. Int J Oral Maxillofac Surg. 2014: 43:40–5.

6. Naran S, Steinbacher DM, Taylor JA. Current concepts in orthognathic surgery. Plast Reconstr Surg. 2018: 141(6):925e-936e.

7. Hernández-Alfaro F, Guijarro-Martínez R. On a definition of the appropriate timing for surgical intervention in orthognathic surgery. Int J Oral Maxillofac Surg. 2014: 43(7):846–55.

8. Steinbacher DM, Kontaxis KL. Does simultaneous third molar extraction increase intraoperative and perioperative complications in orthognathic surgery? J Craniofac Surg. 2016: 27(4):923–6.

9. Bartlett SP. Craniofacial and Maxillofacial Surgery in Children and Young Adults (Volumes I and II). Plast Reconstr Surg. 2002: 109(2):810–1.

6. Figures

Figure 1.a: Preoperative intraoral view

Figure 1.b: Preoperative lateral cephalometric view.

Figure 1.c: Postoperative intraoral view.

Figure 1.d: Postoperative lateral cephalometric view.

Figure 2.a: Preoperative intraoral view

Figure 2.b: Preoperative lateral cephalometric view.

Figure 2.c: Postoperative intraoral view.

Figure 2.d: Postoperative lateral cephalometric view.

Figure 3.a: Preoperative intraoral view.

Figure 3.b: Preoperative lateral cephalometric view.

Figure 3.c: Postoperative intraoral view.

Figure 3.d: Postoperative lateral cephalometric view.

Figure 4.a: Preoperative intraoral view.

Figure 4.b: Preoperative lateral cephalometric view.

Figure 4.c: Postoperative intraoral view.

Figure 4.d: Postoperative lateral cephalometric view.

Figure 5.a: Preoperative intraoral view.

Figure 5.b: Preoperative lateral cephalometric view

Figure 5.c: Postoperative intraoral view.

Figure 5.d: Postoperative lateral cephalometric view.

OP-57

TONGUE REDUCTION BEFORE ORTHOGNATHIC SURGERY IN THE TREATMENT OF MANDIBULAR PROGNATHY AND MACROGLOSSIA

Mustafa Sancar Ataç [a], Bedreddin Cavlı [b], Elif Peker Tunç [c], Emre Çakır [d]

A- Gazi University, Faculty of Dentistry, Department of Oral and Maxillofacial Surgery, Ankara, Turkey msatac@gmail.com

B- Gazi University, Faculty of Dentistry, Department of Oral and Maxillofacial Surgery, Ankara, Turkey bedreddincavli@gmail.com

C- Oral and Maxillofacial Surgeon, Ankara, Turkey, peker_elif@yahoo.com

D- Orthodontist, Ankara, Turkey, dremrecakir@gmail.com

Abstract

Objectives: Macroglossia can cause dentofacial deformities, such as anterior open bite, mandibular or bimaxillary prognathy. In addition, it affects the results obtained with orthognathic surgery and orthodontic treatment in the long term, and may cause recurrence of skeletal and dental disorders. For this reason, tongue reduction surgery can be used in congenital and acquired macroglossia cases or in the treatment of dentofacial deformities. In this case report, we aimed to present the treatment of the patient with advanced skeletal class 3 deformity, including tongue reduction, maxillary advancement and mandibular setback surgeries.

Case Report: Clinical and radiological examination of a 23-year-old female patient, whose main complaint was impaired jaw profile and masticatory functions, revealed severe mandibular prognathy, maxillary retrusion, and pseudomacroglosis. The tongue was reduced 6 months before the planned orthognathic surgery. In the postoperative period, tongue movement, sensory, taste and pronunciation functions were recorded. She experienced mild hypoesthesia and pronunciation problems in the early postoperative period. The symptoms disappeared completely in the third month follow-up.

Conclusion: Soft tissues play an important role in the growth, development and deformities of dentofacial skeletal structures. In tongue reduction surgery, the keyhole technique is the most preferred method, involving both wedge-shaped resection in the anterior region and tissue reduction in the central region. The technique provides a significant debulking of the tongue volüme, and the protection of the neurovascular bundles located laterally.

Key words: macroglossia, tongue reduction, orthognathy

1. Introduction

Tongue structures are known to affect skeletal and dental structures with their size and location (1). It affects the airway, speech and the relationship between the jaws according to the expansion of the tongue dimensions in different directions, causing both functional and cosmetic deformities (2,3).

Makroglossia is largely divided into two as true macroglossia and pseudomacroglossia. The true macroglossia may be vascular malformation, Beckwith-Wiedemann and congenital condition caused by muscle hypertrophy. It can also be associated with acquired conditions such as amyloidosis, neurofibromatosis, acromegaly, hypothyroidism, and myxedema (2).

In pseudomacroglossia or relative macroglossia, the tongue sizes are within normal limits but larger compared to surrounding anatomical structures. This may be due to severe transverse, vertical or anteroposterior deficiency of maxillary and mandibular arches or severe mandibular retrusion that reduces the volume of the oral cavity, (2).

It is important to clarify the signs and symptoms of macroglossia to determine whether a reduction glossectomy is required. Wolford and Cottrell (2) have described several clinical and cephalometric features for macroglossia. Clinical features include the presence of a distinctly wide, thick and flat tongue, open bite disorders, mandibular prognathism, the presence of a notched image formed by the tooth arch on the lateral sides of the tongue, and glossitis. Cephalometric radiographic findings; mandibular dentoalveolar protrusion includes advanced angulation of anterior teeth and increased gonial, mandibular plane and occlusal plane angles.

Partial glossectomy can reduce postoperative recurrence in mandibular setback surgeries performed for mandibular prognathy (4). Most reports were of two-stage surgery, because of concern about postoperative airway obstruction secondary to tongue edema and bleeding immediately after surgery. In our presented case, partial glosectomy was performed 6 months before the planned mandibular setback surgery.

2. Case Report

A 21-year-old female patient was admitted to our clinic with complaints of dentofacial deformity characterized by incompatibility in the relations between the jaws, and associated disorders of chewing and speech functions. Severe mandibular prognathy (-12 mm negative overjet) and anterior open bite (-6mm over bite) were observed in the patient who did not have any known syndrome and congenital disease. It showed all of the clinical signs of macroglossia except glossitis (Figüre 1) (2). In lateral cephalometric analysis, severe mandibular prognati (ANB: -3°) an increase in the mandibular plane, occlusal and gonial angles (40°, 17°, 138°) was detected.

First, the anterolateral corners of the tongue were determined and stretched with sutures. The projection of vascular structures with the ventral face was shown in the dorsum of the tongue with the vertical placement of two dental injector needles.

The cut lines were marked prior to surgery, starting from both anterolateral corners of the tongue, advanced in the posteromedial direction, and marked to unite at the posterior of the tongue. Instead of a sharp-angle, however, intersection of these lines at the tongue base should be circular. The lines were joined on the ventral face of the tongue, without involving tongue root and connective tissue attachments.

During the follow-up of the patient, tongue muscle, sensory, taste and pronunciation functions were evaluated. Although the patient experienced hypoesthesia and pronunciation problems in the early postoperative period, the related symptoms disappeared in the third month of follow-up (Figure 2, 3).

3. Discussion

The effect of glossectomy on skeletal and dental stability after orthodontic treatment and orthognathic surgery is still controversial in patients with pseudomacroglossia. Kawakami et al. (5). argued that there was no difference in dental and skeletal stability in patients with and without glosectomy, and the hyoid bone adapted within 1 year. In another study, it was stated that in cases where maxillary advancement is also included in the planning, the anterior teeth will be under less pressure due to the enlargement of the tongue area (6).

Other research has suggested that tongue plays an important role in relapse after orthodontic treatment or orthognathic surgery (4,7,8). With mandibular setback surgery, the area of the tongue is narrowed and recurrences can be seen in the deformities with the increased pressure of the tongue on the anterior teeth. The recurrence risk is higher in cases of open bite and severe prognathism. Our case had pseudomacroglosis with anterior open bite and mandibular prognathism. Partial glossectomy was performed before orthognathic surgery in our case because of the significant risk in terms of postoperative relapse and airway problems.

Wolford and Cottrell (2) defined 3 types of surgery sequences. These; performing glossectomy first, performing orthognathic surgery first and both operations are performed in one session. In single-stage surgeries, the number of general anesthesia decreases and inter-session adaptations and relapses seen in double-stage surgeries are not observed. However, the degree of obstruction of the airway cannot be predicted due to both mandibular setback and postoperative edema and bleeding in the tongue.

With the development of rigid fixation systems in orthognathic surgeries, the need for postoperative intermaxillary fixation has decreased. For this reason, all 3 planning can be applied today (9,10).

Various tongue reduction techniques have been described (11). The most preferred technique in partial glossectomy is the "keyhole" technique, in which the tip of the tongue is also excised (10). The technique may result in ankylosed and globulear tongue with sensory disorders. Although mostly no loss of taste is observed, some reported cases have decreased the perception of bitter and salty flavors (12). For this reason, central excision techniques are described that do not touch tip of the tongue (10,13). Tongue volume can also be reduced by the extraoral approach by excision of the muscle structures in the submucosal area (14).

Although mild hypoesthesia and pronunciation problems were observed in the follow-up of our case, the symptoms disappeared within 3 months.

4. Conclusion

Soft tissues play an important role in the growth, development and deformities of dentofacial structures. The first aim of the surgical procedures is to correct the existing deformity, but it should also be aimed to prevent long-term stability and avoid possible complications in planning. The keyhole technique is a specific technique used in the treatment of macroglossia, which includes both wedge-shaped resection in the anterior region and tissue reduction in the central region. The technique provides a significant debulking of the tongue volume and the protection of the neurovascular bundles located laterally.

5. References

1. Kawakami, S., Yokozeki, M., Takahashi, T., Horiuchi, S., Moriyama, K. Siblings with spaced arches treated with and without partial glossectomy. American journal of orthodontics and dentofacial orthopedics, 2005:127(3), 364-373.
2. Wolford, L. M., Cottrell, D. A. Diagnosis of macroglossia and indications for reduction glossectomy. American journal of orthodontics and dentofacial orthopedics, 1996:110(2), 170-177.
3. Harada, K., Enomoto, S. A new method of tongue reduction for macroglossia. Journal of oral and maxillofacial surgery, 1995:53(1), 91-92.
4. Swanson, L. T., Murray, J. E. Partial glossectomy to stabilize occlusion following surgical correction of prognathism: Report of a case. Oral Surgery, Oral Medicine, Oral Pathology, 1969:27(6), 707-715.
5. Kawakami, M., Yamamoto, K., Noshi, T., Miyawaki, S., Kirita, T. Effect of surgical reduction of the tongue on dentofacial structure following mandibular setback. Journal of oral and maxillofacial surgery, 2004:62(10), 1188-1192.
6. Cho, H. J. Long-term stability of surgical mandibular setback. The Angle Orthodontist, 2007:77(5), 851-856.
7. Hotokezaka, H., Matsuo, T., Nakagawa, M., Mizuno, A., Kobayashi, K. Severe dental open bite malocclusion with tongue reduction after orthodontic treatment. The Angle Orthodontist, 2001:71(3), 228-236.

8. Ruff, R. M. Orthodontic treatment and tongue surgery in a class III open-bite malocclusion. A case report. The Angle Orthodontist, 1985:55(2), 155-166.
9. Petdachai, S., Inoue, Y., Inoue, H., Sakuda, M. Orthognathic surgical approach and partial glossectomy to a skeletal 3 adult open bite. The Journal of Osaka University Dental School, 1993:33, 14.
10. Jung, Y. W., On, S. W., Chung, K. R., Song, S. I. Simultaneous Glossectomy With Orthognathic Surgery For Mandibular Prognathism. Maxillofacial Plastic And Reconstructive Surgery, 2014;36(5), 214–218.
11. Wang, J., Goodger, N. M., & Pogrel, M. A. The role of tongue reduction. Oral Surgery, Oral Medicine, Oral Pathology, Oral Radiology, and Endodontology, 2003:95(3), 269-273.
12. Matsune, K., Miyoshi, K., Kosaki, R., Ohashi, H., & Maeda, T. Taste after reduction of the tongue in Beckwith–Wiedemann syndrome. British Journal of Oral and Maxillofacial Surgery, 2006:44(1), 49-51.
13. Mixter, R. C., Ewanowski, S. J., Carson, L. V. Central tongue reduction for macroglossia. Plastic and reconstructive surgery, 1993:91(6), 1159-1162.
14. Robinson, S. (2008). External Submucosal Glossectomy. Sleep Apnea and Snoring: Surgical and Non-Surgical Therapy. New York: Elsevier, 292-300.

POSTER PRESENTATION

PP- 0095

PERIPHERAL DENTINOGENIC GHOST CELL TUMOUR

Gözde Işık[a], Selin Kenç[b], Tayfun Günbay[c]

A- Ege University, Faculty of Dentistry, Department of Oral and Maxillofacial Surgery, Turkey, gozde.isik@ege.edu.tr

B- Ege University, Faculty of Dentistry, Department of Oral and Maxillofacial Surgery, Turkey, selin.kenc@ege.edu.tr

C- Ege University, Faculty of Dentistry, Department of Oral and Maxillofacial Surgery, Turkey, tayfun.gunbay@ege.edu.tr

Abstract

Objective: Dentinogenic ghost cell tumour (DGCT) is a rare, locally invasive neoplasm. To our knowledge, only 88 cases of DGCT have been reported in the literature. The purpose of this case presentation is contribute that DGCT cases and help to understand the biological behavior of these lesions better.

Case: A 77 year-old male was referred to School of Dentistry, with a complaint of the soft tissue growth that cause functional disorders including to use of a total prosthesis, during six months. Intraoral examination was revealed that a solitary, sessile, globular and exophytic soft tissue mass present in edentulous anterior region of the mandible. There was no signs of bleeding or any complaint for pain. Also, there was no clinical symptoms of regional lymphadenopathy. Radiographic examination was revealed a multilocular mixed radiolucency through canine tooth with the perforation of buccal cortex. Benign odontogenic tumours, central giant cell granuloma and fibrous lesions were considered in clinical differential diagnosis. Excisional biopsy was done under local anesthesia and curretage was performed to remove the tissue debris. After then, the bleeding foci were cauterized and the surgical site was sutured primarily. The histopathological impression was that of a peripheral DGCT.

Conclusion: DGCT is an uncommon odontogenic neoplasma which can be characterized benign or malignant and local recurrences may be observed even from tumour totally excised. This present case reported a benign form of peripheral DGCT. After 1-year follow-up, no recurrence has been observed.

Key words: Odontogenic tumour, dentinogenic ghost cell tumour, diagnosis

1. Introduction

Calcified odontogenic cyst (COC), that is an odontogenic tumor (1,2), was firstly described in 1962 by Gorlin et al.(3). COC, which is defined as calcified ghost cell odontogenic cyst (CGCOC), is a heterogeneous lesion with a cystic or solid variant. This benign tumour occurs during the seventh decade of life and is more common in males than in females (4). This tumour is mostly observed in the anterior regions of maxilla and mandible (5). Central lesions are generally seen as asymptomatic with a bone expansion, while peripheral lesions appear a solitary, sessile, globular and exophytic soft tissue mass (4).

There is no consensus in the literature whether COC is a cyst or a tumour, since all CGCOC lesions are not cystic and their biological behavior is often inconsistent with the cyst (3). Two different classification have been introduced as follows; monistic and dualistic (6). According to the monistic definition, the World Health Organization (WHO) classification defines that all COCs are neoplastic despite the fact that they are mostly cystic and non-neoplastic (7) In a contrary, according to the dualistic definition accepted by most authors, COC have a cystic and neoplastic content (8). Therefore, the cystic lesions of COC are introduced “calcified cystic odontogenic tumors” and the neoplastic lesions are introduced “dentinogenic ghost cell tumor” (DGCT) (5,6). DGCT is a rare and locally invasive odontogenic tumor. DGCT constitutes 2% to 14% of all COCs in which categorized as central or peripheral tumors (9). This tumour can be either benign or malignant, depending on the histopathological features (4).

This case report presents a benign form of peripheral DGCT in the anterior region of the mandible. The purpose of this case report is contribute that DGCT cases and help to understand the biological behavior of these lesions better.

2. Case Report

A 77 year-old male was referred to School of Dentistry, with a complaint of the soft tissue growth that cause functional disorders including to use of a total prosthesis, during six months. Medical history revealed that anticoagulant drugs have been used over the past 10 years and the laboratory tests were normal. Intraoral examination was revealed that a solitary, sessile, globular and exophytic soft tissue mass present in edentulous anterior region of the mandible. There was no signs of bleeding or any complaint for pain. Also, there was no clinical symptoms of regional lymphadenopathy. Radiographic examination was revealed a multilocular mixed radiolucency through canine tooth with the perforation of buccal cortex. According to clinical appereance of the lesion, benign odontogenic tumors, central giant cell granuloma and fibrous lesions were considered in the differential diagnosis.

Based on the clinical and radiological findings, excisional biopsy was performed under local anesthesia, after the patient signed an informed consent agreement. The curretage was done under sterile saline irrigation. Then, the bleeding foci were cauterized and the surgical site was sutured primarily. Postoperatively, antibiotic and analgesic were prescribed twice a day for a week. Also, soft diet was recommended.

The biopsy sample was referred to the Pathology Department of the Faculty of Medicine. The samples showed odontogenic epithelial follicles and ameloblast-like cells with hyperchromatic nuclei. A basaloid cell layers and ghost cells within irregular dentinoid layer were observed throughout the section. was observed in tissue sections. The histopathological diagnosis was peripheral DGCT.

At postoperatively two weeks, the sutures were removed and the follow-up visits were scheduled at the 6-month intervals. There was no signs of inflammation or healing disorders in the surgical site. At postoperatively 12 months follow-up, no recurrence was observed.

3. Discussion

DGCT is a rare odontogenic tumor that constitutes 2% to 14% of all COCs (1) This tumor is categorized into two groups as follow; central and peripheral lesions (4). According to the our literature search on central DGCTs, only 16 cases have been reported (10). Peripheral DGCT, is observed as a solitary, sessile, globular and exophytic soft tissue mass at the gingival mucosa or the alveolar mucosa of edentulous ares in the anterior region of the mandible (11). This tumour is more common in males than in females (4). This case report presents a 77-year-old male patient with a peripheral DGCT in the anterior region of the mandible.

As a treatment method, total or partial radical resection as an en block excision or conservative treatment option, as excisional biopsy, curettage, and enucleation have been reported in the literature (12,13). Local excision or curettage was mostly recognised as the best treatment option for peripheral DGCT. Also, local excision has been reported after diagnosis by incisional biopsy in the patients (11,14). In this case report, excisional biopsy was performed and curettage was carefully executed to remove the tissue debris.

DGCT can be either benign or malignant, depending on the histopathological features (9). Comparing central and peripheral DGCT, the behavior of the peripheral form is a less aggressive and the relapse therefore, is a very low (13). However, malignant transformation of a benign DGCT has also been reported in the literature (9). Therefore, the follow-up has a great importance. In this case report, clinical and radiographical examination was performed during 12 months of follow-up and no evidence of recurrence was observed.

4. Conclusion

DGCT is an uncommon odontogenic neoplasma which can be characterized benign or malignant and local recurrences may be observed even from tumour totally excised. This present case reported a benign form of peripheral DGCT. After 1-year follow-up, no recurrence has been observed.

5. References

1. Bussari, S., Thakur, S.M., Koshy, A.V., Shah, A.A. Dentinogenic ghost cell tumor – A case report and review of literature. J Oral Maxillofac Pathol. 2019: 23:66-68.

2. Gorlin, R.J., Pindborg, J.J., Clausen, F.P., Vickers, R.A. The calcifying odontogenic cyst - a possible analogue of the cutaneous calcifying epithelioma of Malherbe. An analysis of fifteen cases. Oral Med Oral Pathol. 1962: 15:1235-1243.

3. Rai, S., Prabhat, M., Goel, S., Bhalla, K., Panjwani, S., Misra, D., Agarwal, A., Bhatnagar, G. Dentinogenic ghost cell tumor - A neoplastic variety of calcifying odontogenic cyst: Case presentation and review. N Am J Med Sci. 2015: 7:19-23.

4. Kler, S., Palaskar, S., Shetty, V.P., Bhushan, A. Intraosseous calcifying cystic odontogenic tumor. J Oral Maxillofac Pathol. 2009: 13:27-29.

5. Thinakaran, M., Sivakumar, P., Ramalingam, S., Jeddy, N., Balaguhan, S. Calcifying ghost cell odontogenic cyst: A review on terminologies and classifications. J Oral Maxillofac Pathol. 2012: 16:450-453.

6. Toida, M. So-called calcifying odontogenic cyst: Review and discussion on the terminology and classification. J Oral Pathol Med. 1998: 27:49-52.

7. Speight, P.M., Takata, T. New tumour entities in the 4th edition of the World Health Organization Classification of Head and Neck tumours: odontogenic and maxillofacial bone tumours Virchows Arch. 2018: 472:331-339.

8. Colmenero, C., Patron, M., Colmenero, B. Odontogenic ghost cell tumours. The neoplastic form of calcifying odontogenic cyst. J Craniomaxillofac Surg. 1990: 18:215-218.

9. Patil, K., Mahima, V.G., Srikanth, H.S. Dentinogenic ghost cell tumor: A variant of Gorlin's cyst. J Oral Maxillofac Pathol. 2008: 12:38-40.

10. Kasahara, K., Iizuka, T., Kobayashi, I., Totsuka, Y., Kohgo, T. A recurrent case of odontogenic ghost cell tumour of the mandible. Int J Oral Maxillofac Surg. 2002: 31:684-687.

11. Pommer, B., Dvorak, G., Rappersberger, K., Jordan, R.C., Watzek, G., Pogrel, M.A. Pyogenic granuloma mimicking peripheral dentinogenic ghost-cell tumour recurrence: Case report and meta-analytic literature update. Oral Surg. 2013: 6:98-103.

12. Singhaniya, S.B., Barpande, S.R., Bhavthankar, J.D. Dentinogenic ghost cell tumor. J Oral Maxillofac Pathol. 2009: 13:97-100.

13. Sun, G., Huang, X., Hu, Q., Yang, X., Tang, E. The diagnosis and treatment of dentinogenic ghost cell tumor. Int J Oral Maxillofac Surg. 2009: 38:1179-1183.

14. Iezzi, G., Rubini, C., Fioroni, M., Piattelli, A. Peripheral dentinogenic ghost cell tumor of the gingiva. J Periodontol. 2007: 78:1635-1638.

PP- 0148

PERIPHERAL GIANT CELL GRANULOMA: A CASE REPORT

Yıldız Ünüvar (yldzunuvar2@gmail.com)

Müfide Bengü Erden Şahin

İrem Yaman

Aylin Çalış

Hüseyin Koca

Ege university School of Dentistry, Department of Oral Maxillofacial Surgery, İzmir, Turkey

OBJECTIVE: Peripheral giant cell granuloma is a relatively rare benign reactive tissue growths of the gums against trauma and irritation. The feature that distinguishes this lesion from others is the emergence of multi-core giant cells, but the reason for their existence is unknown. It is more common in the mandibular arch than in the maxillary arch and is often seen in the anterior region up to the permanent first molar. It can cause displacement and mobility in the teeth to which it is associated. In edentulous regions, it can cause resorption in the alveolar crest. It typically appears as masses in colors ranging from red to blue. In differential diagnosis, pyogenic granuloma, peripheral ossifying fibroma, epulis, hemangioma should be considered. These lesions can occur at any age and tend to be more common in women than in men. In this case report, diagnosis and treatment of peripheral giant cell granulomas are presented.

CASE: A 68-year-old male, who was systemically healthy, applied to our clinic with a complaint of swelling that had been in the anterior region of the upper jaw for about 5 months. In the clinical examination, an exophytic lesion with a smooth, shiny surface, hard consistency, blue-purple color, approximately 3 cm in size and stemmed was observed in the anterior region (Figure 1). There was no pain and tenderness in palpation. The patient had no smoking history. In the panoramic radiography (Figure 2) and CBCT image sections of patient, extensive destruction in bone tissue was observed in the bone tissue around the anterior teeth (Figure 3). Teeth number 11, 12, 22, 23 were removed under local anesthesia, and the lesion was enucleated. The specimen was sent to pathology for histopathological examination, and peripheral giant cell granuloma was diagnosed (Figure 4). The patient was followed up.

CONCLUSION: Early and definitive diagnosis of these lesions is important and allows conservative treatment. However, in advanced cases, bone destruction and tooth extraction are inevitable.

Figure 1: Image of the lesion observed in the anterior region

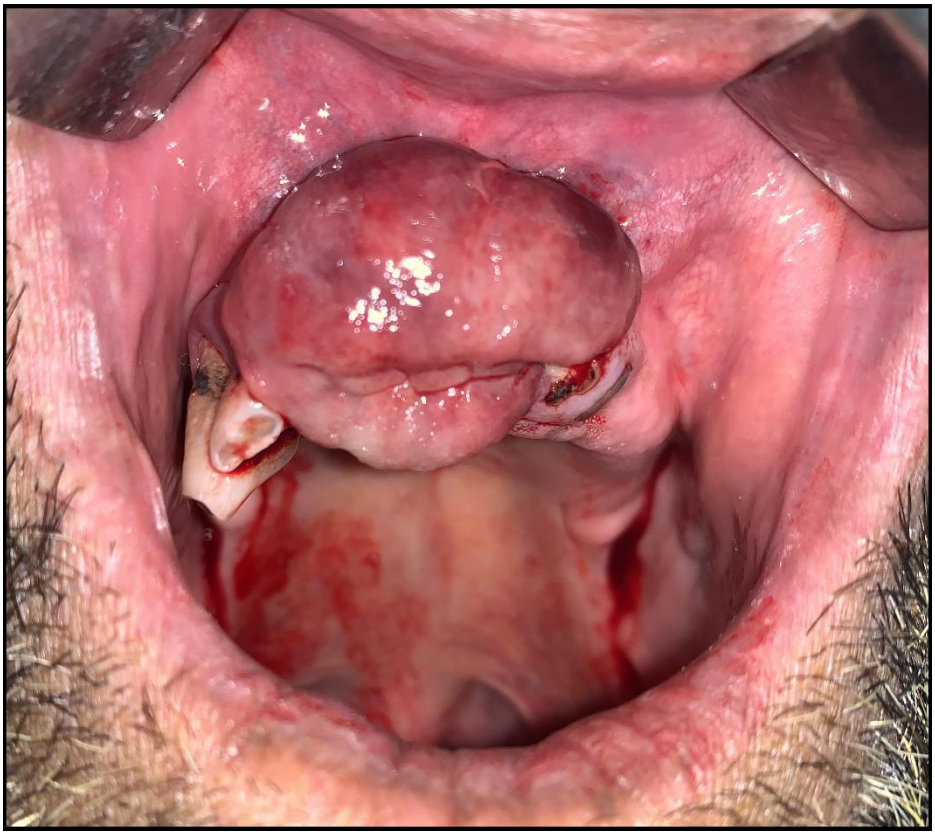

Figure 2: Panoramic radiography of the patient

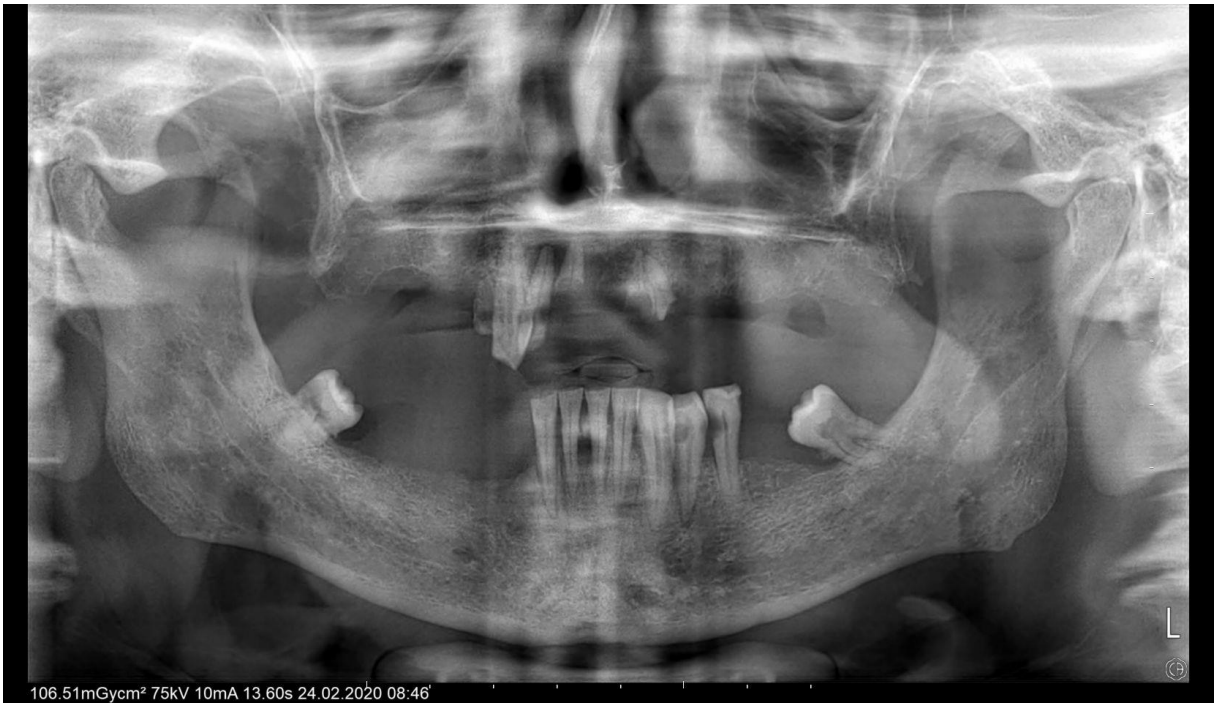

Figure 3: CBCT image of the patient

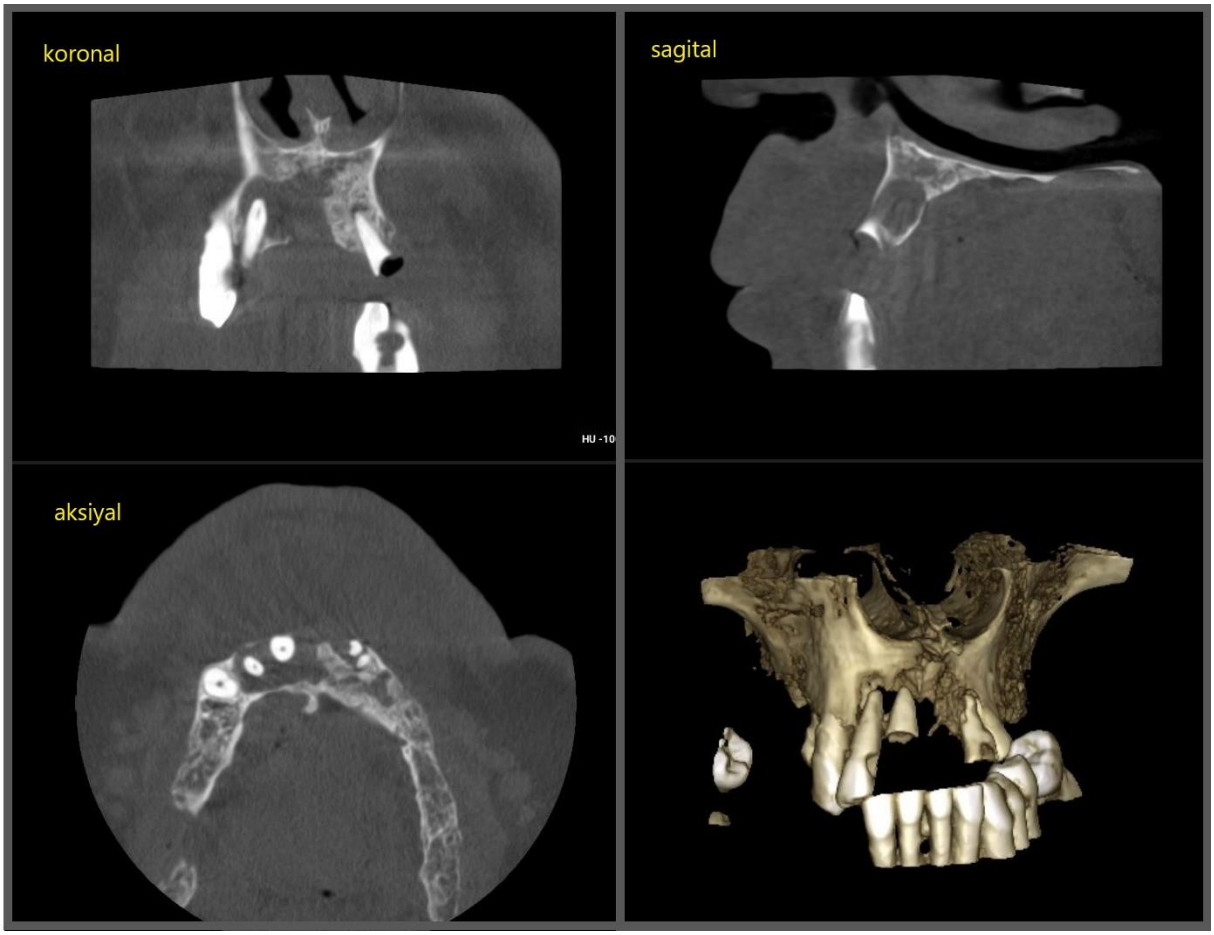

Figure 4: Lesion removed after excision

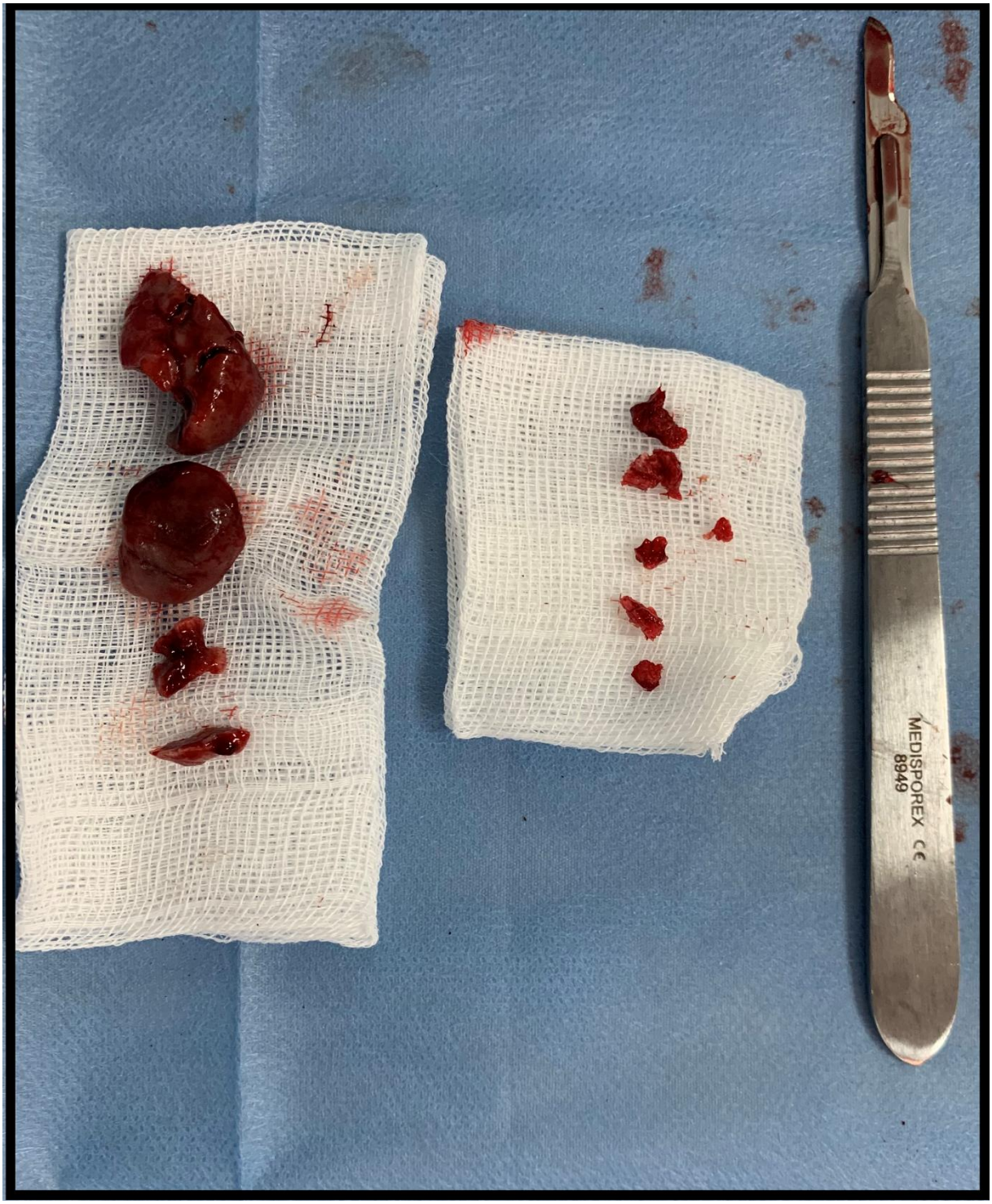

PP- 258

Traumatic Bone Cyst in the Mandible: Case Report

Gülce Ecem Doğancalı[a], Mehmet Ali Erdem[b]

a, Istanbul University, Dentistry Faculty Oral and Maxillofacial Surgery Department, Istanbul/Turkey, gulceecem@gmail.com

b, Istanbul University, Dentistry Faculty Oral and Maxillofacial Surgery Department, Istanbul/Turkey, drmalierdem@gmail.com

Abstract

Objective: Traumatic bone cyst is a rare non-neoplastic lesion of the jaws, which is also considered a "pseudocyst" due to the absence of epithelial lining. This lesion is usually asymptomatic therefore it can be detected in routine dental radiographic examination. They are seen as a unilocular radiolucent area, inserted between the teeth in the form of a comb often in the mandible. However, it can also be seen in patients without a trauma history.

Case: 18-year-old female patient was admitted to the Istanbul University Faculty of Dentistry, Oral and Maxillofacial Surgery Clinic with the complaint of cysts observed on routine radiography in the outer center. In radiographic examination, a radiolucent lesion with prominent borders was observed in the apical of teeth 36 and 37. In vitalometric tests, the teeth were found to be vital. Under local anesthesia, the mucoperiostal flap was elevated in the posterior region of the right mandible, and a 1 cm2 bone window was opened in the teeth area without damaging the roots. And an empty bone cavity without any epithelial flooring was seen. With curettage, blood was filled into the cavity and closed primarily. During the patient's 1-year control, it was observed that ossification was fully completed in the relevant region.

Conclusion: Traumatic bone cysts can often be confused with other cysts. Radiological examination, taking an anamnesis and vitality test have an important role in proper treatment and correct evaluation of prognosis.

Key Words: bone, cyst, trauma

1.Introduction

Traumatic bone cyst is an empty intrabony cavity that lacks of an epithelial lining.(1) Traumatic bone cysts were described in 1929.(2) They are commonly found in the metaphysis of long bones, and in some rare cases in the jaws.(3)

They are usually asymptomatic and appear on routine radiographies. Because of a lack of distinctive clinical and radiographic characteristic, it is important to make the differential diagnosis between traumatic bone cysts and other bone lesions of the jaws. (4)

The pathogenesis is not known, although some cases seem to be associated with trauma. Assuming this, a traumatically induced hematoma has been hypothesized as forming within the intramedullary portion of bone. Rather than organizing, the clot breaks down, leaving an empty bony cavity. Alternative developmental pathways include cystic degeneration of primary tumors of bone, such as central giant cell granuloma, disorders of calcium metabolism, and ischemic necrosis of bone marrow. (1)

Histopathologically, only minimal amounts of fibrous tissue from the bony wall are seen. The lesion may occasionally contain blood or serosanguineous fluid. Microscopic examination should identify delicate, well-vascularized, fibrous connective tissue without the evidence of an epithelial component (1)

The treatment of choice for traumatic bone cysts is surgery for curettage of the bone walls, which generally results in short-term healing. (5) Recurrences are rare, and usually occur within three months of surgery. (6)

2. Case Report

The 18-year-old female patient was admitted to the Istanbul University Faculty of Dentistry, Oral and Maxillofacial Surgery Clinic with the complaint of cysts observed on routine radiography in the outer center. In radiographic examination, a radiolucent lesion with prominent borders inserted between the teeth in the form of a comb was observed in the apical of teeth 36 and 37. (Figure 1) Vitalometric test was applied to teeth. And it was seen that teeth are vital. Under local anesthesia, the mucoperiostal flap was elevated in the posterior region of the right mandible, 1 cm2 bone window was opened in the teeth area without damaging the roots. And an empty bone cavity without any epithelial flooring was seen. With curettage, blood was filled into the cavity and closed primarily. During the patient's 1-year control, it was observed that ossification fully completed in the relevant region. (Figure 2)

3. Discussion

The traumatic bone cyst was first described by Lucas in 1929 and later by Rushton. (7) They have been reported in the literature with many different names, such as hemorrhagic bone cyst, extravasation cyst, and simple bone cyst. This suggests that the true etiopathogenesis of this lesion cannot be understood. However, at the present the term traumatic bone cyst is the most widely used one. (8) In the classification suggested by the World Health Organization (WHO), these are included in the group of bone-related lesions, together with the aneurysmal bone cyst, ossifying fibroma, fibrous dysplasia, osseous dysplasia, central giant-cell granuloma, and cherubism. (9)

The incidence of this cyst in the jaws is 1% among all the cyst occurring. Nearly 89% of the lesion occurs in the mandible and 11% in the maxilla. Majority of the lesions occur in the posterior mandible, especially in the premolar–molar region, while in the maxilla, they are more common in the anterior region. (10) In our case, the lesion was seen in the posterior region of the mandible.

The pathogenesis of the traumatic bone cyst is not completely understood. Trauma has been frequently suggested as an etiological factor. (9) In the present case report, there is no history of trauma.

Traumatic bone cysts are mostly detected accidentally, as they are usually asymptomatic. Cases were reported in literature where the lesion was asymptomatic and was detected during routine radiological examination.(7) In our case report, the patient is asymptomtic.

Curretting completely and filling the cavity with blood is the most common method of treating these lesions. Although surgical approach is seen as a safe way of diagnosis and treatment of these lesions, follow-up without surgical intervention may be an option for selected cases based on epidemiological, clinical and radiographic features. When a non-surgical protocol is selected, patients' long-term follow-up is of great importance. (11) In our case it was observed that ossification was fully completed in one year follow with curettage.

4. Conclusion

Traumatic bone cysts can often be confused with other cysts. Radiological examination, right anamnesis and vitality test have an important role in proper treatment and correct evaluation of prognosis.

5. References

1. Regezi, Joseph A., DDS, MS; Sciubba, James J., DMD, PhD; Jordan, Richard C.K., DDS, MSc, PhD, FRCD(C), Oral Pathology. FRCPath. Published January 1, 2017.

2. Lucas CD, Blum T. Do all cysts in the jaws originate from the dental system? J Am Dent Assoc. 1929;16:647-61.

3. Saito Y, Hoshina Y, Nagamine T, Nakajima T, Suzuki M, Hayashi T. Simple bone cyst. A clinical and histopathologic study of fifteen cases. Oral Surg Oral Med Oral Pathol. 1992;74(4):487-91

4. Martins-Filho PR, Santos Tde S, Araújo VL, Santos JS, Andrade ES, Silva LC. Traumatic bone cyst of the mandible: a review of 26 cases. Braz J Otorhinolaryngol. 2012;78(2):16-21.

5. Harnet JC, Lombardi T, Klewansky P, Rieger J, Tempe MH, Clavert JM. Solitary bone cyst of the jaws: a review of the etiopathogenic hypotheses. J Oral Maxillofac Surg. 2008;66(11):2345-8.

6. Baqain ZH, Jayakrishnan A, Farthing PM, Hardee P. Recurrence of a solitary bone cyst of the mandible: case report. Br J Oral Maxillofac Surg. 2005;43(4):333-5

7. Bindra S, Jadaun G, Jois HS, Sen P. Traumatic Bone Cyst of Mandible: A Case Report of Rare Entity and Review of Literature. Contemp Clin Dent. 2019;10(1):3-8. doi:10.4103/ccd.ccd_489_18

8. Satish K, Padmashree S, Rema J. Traumatic bone cyst of idiopathic origin? A report of two cases. Ethiop J Health Sci. 2014;24:183–7.

9. Sebastijan S. Traumatic bone cysts. Acta Stomatol Croat. 2001;35:417–20

10. Shear M. Cysts of the Oral Regions.3rd ed. Oxford: Wright PSG; 1992.

11. Battisti MPL, Soares MQS, Rubira CMF, Bullen IRFR, Lauris JRP, Damante JHJ. Assessment of spontaneous resolution of idiopathic bone cavity. Appl Oral Sci. 2018; 26():e20170288.

6. Figures

Figure 1: First panoramic radiography

Figure 2: 1 year follow up

PP- 0272

ACANTHOMATOUS AMELOBLASTOMA: A RARE CASE PRESENTATION

Ömür Dereci [a], Nesrin Saruhan [b], Görkem Tekin [c]

A-Eskişehir Osmangazi University, Faculty of Dentistry, Department of Oral and Maxillofacial Surgery, Eskişehir, Turkey, omurdereci@hotmail.com

B- Eskişehir Osmangazi University, Faculty of Dentistry, Department of Oral and Maxillofacial Surgery, Eskişehir, Turkey, dt_nesrin@yahoo.com

C-Eskişehir Osmangazi University, Faculty of Dentistry, Department of Oral and Maxillofacial Surgery, Eskişehir, Turkey, dt.gorkemtekin@gmail.com

Abstract

Objective: Ameloblastoma is the most well-known of epithelial odontogenic benign tumors. It has a slow-growing and locally aggressive behaviour. It is frequently found in the mandibular ramus and angulus region. While there are various histopathological variants, acanthomatous ameloblastoma is one of the rarest. This case report presents the treatment by marginal resection in a patient diagnosed with acanthomatous ameloblastoma.

Case: The 32-year-old female patient was referred to our clinic with the complaint of swelling on the left side of her face. Radiological examination revealed multilocular radiolucency with non-corticated borders on the left premolar-molar region. Biopsy was carried out under local anesthesia and the specimen was sent for histopathological examination. The lesion was diagnosed as acanthomatous ameloblastoma as a result of histopathological examination and removed by partial resection under general anesthesia. No relapse was observed in the 6-month follow up period.

Conclusion: Histological and radiographic examination is important in the differential diagnosis of acanthomatous ameloblastoma. Treatment is provided based on clinical, histological and radiological characteristics. Treatment methods consist of conservative surgery, radical surgery, radiotherapy, chemotherapy and their combinations.

Keywords: Acanthomatous ameloblastoma, odontogenic tumor, partial resection

1.Introduction

Ameloblastoma was defined as adamantinoma for the first time by Broca (1868), and it is a rare, benign, epithelial odontogenic neoplasm that was revised later by Churchill (1934)(1). It develops slowly, and by its nature, it is locally aggressive, and it is seen most frequently seen in the posterior mandible(2). With the tendency of expansion and destruction, they are tumors with a high recurrence rate. This neoplasm is unencapsulated, and it occasionally shows local invasive behaviour. The most prevalent symptom is a painless, slow-growing mass. Its typical radiological appearance involves multifocal radiolucent areas in the form of “honeycomb” or “soap bubbles”(3). Its incidence in men and women is equal, and it is more frequently seen in patients over the age of 30(4). Various histological sub-types have been defined, where the follicular type (64.9%) is the most prevalent, and the acanthomatous type (3.9%) is the rarest(5). The incidence of the acanthomatous type was reported as 0.6 cases in a million by Larsonn and Almeren(6) and 0.31 cases in a million by Shear and Singh(3). Its treatment is provided based on clinical, radiological and histological properties. These treatment methods include conservative surgery (curettage/enucleation), radical surgery (total/partial resection), radiotherapy, chemotherapy and their combinations(7). In this study, we are reporting the diagnosis and treatment of a case of acanthomatous ameloblastoma of the mandible occurring in a 32-year-old female patient.

2.Case Report

The 32-year-old female patient was referred to the Department of Oral and Maxillofacial Surgery,Faculty of Dentistry, Eskişehir Osmangazi University with the complaint of swelling in the left mandibular region. In the intraoral examination, a hard swelling on the vestibuleregion in the left mandibular premolar region and a well-demarcated swelling in the lingual region were observed by bidigital palpation. Lymphadenopathy or fistulation was not observed. The patient’s past history and medical history were unremarkable and non-significant. On radiographic examinations, intraoral periapical radiograph revealed multilocular radiolucency in the left premolar region (Figure 1). Panoramic radiograph revealed multilocular radiolucencies with non-corticated but well-defined borders extending from the region of 36 to 33. However, the lower border of the mandible was intact (Figure 2). After the consent of the patient was obtained, biopsy was performed under local anesthesia (Figure 3).

The specimen was sent for histopathological examination. As a result of the histopathological examination, the diagnosis of acanthomatous ameloblastoma was made. Surgical intervention was decided to remove the lesion. Informed and written consent were taken regarding the anesthesia and surgical procedure. General anesthesia was applied on the patient, and partial resection was made by leaving a safe border (Figure 4 and Figure 5). All associated teeth were removed associated with the lesion. No relapse was observed in the panoramic radiography taken 6 months after the operation for check-up (Figure 6).

3.Discussion

Ameloblastoma is a benign epithelial odontogenic neoplasm. It is generally aggressive and destructive. Due to its capacity of invading adjacent structures and leading to bone erosion, it may reach large sizes. It is characterized by its histological similarity to the enamel organ of developing tooth germ, but enamel formation is not observed(8). Ameloblastoma constitutes approximately 1% of all maxillomandibular tumors. Approximately 80% of all cases occur in the mandible, while 70% of these are seen in the ramus(9). According to the odontogenic tumor classification of the World Health Organization (WHO), ameloblastoma cases are divided into four types: solid/multicystic, extraosseous/peripheral, metastatic and unicystic. Histologically, the most prevalently observed types are plexiform and follicular types. Other four types that are not common include the acanthomatous, granular cell, desmoplastic and basal cell types(10). Acanthomatous-type ameloblastoma, which was found in our case, is a very rarely observed type. Although it is usually seen in the mandibular ramus region, observation of it in the mandibular premolar region constitutes the difference of our case based on the literature review.

Acanthomatous ameloblastoma is seen more frequently in elderly patients. Its age of emergence is 61.3 ± 1.2 and in the range of 60-62 years, while the highest incidence of it was observed in the 7th decade of life(11). In our case, the patient was female, and it emerged in the 3rd decade.

With dentigerous cysts and odontogenic keratocysts, when the age, location, size and distribution of the swelling are considered, clinical differential diagnosis could probably be made. Radiological differential diagnosis may include odontogenic myxoma and central giant cell granuloma(12).

4.Conclusion

Histopathological examination is required for definitive diagnosis, and treatment should be planned according to its results.

5.References

1. Regezi JA, Sciubba J, Jordan RC. Oral pathology: clinical pathologic correlations: Elsevier Health Sciences; 2016.
2. Ugrappa S, Jain A, Fuloria NK, Fuloria S. Acanthomatous ameloblastoma in anterior mandibular region of a young patient: A rare case report. Annals of African medicine. 2017;16(2):85.
3. Shear M, Singh S. Age-standardized incidence rates of ameloblastoma and dentigerous cyst on the Witwatersrand, South Africa. Community dentistry and oral epidemiology. 1978;6(4):195-9.
4. Chintamaneni RL, Madala SR, Meka PVP, Bhavana SM. Acanthomatous ameloblastoma: A clinical rarity. Journal of Indian Academy of Oral Medicine and Radiology. 2014;26(2):200.
5. Damm N BATBoOaMPreSLSEp-.
6. Larsson Å, Almerén H. Ameloblastoma of the Jaws: An Analysis of a Consecutive Series of all Cases Reported to the Swedish Cancer Registry during 1958–1971. Acta Pathologica Microbiologica Scandinavica Section A Pathology. 1978;86(1-6):337-49.
7. Williams TP. Management of ameloblastoma: a changing perspective. Journal of oral and maxillofacial surgery. 1993;51(10):1064-70.
8. Pachigolla R, Velugubantla RG, Chennoju SK, Erva S. Acanthomatous ameloblastoma: A rare presentation. Journal of Indian Academy of Oral Medicine and Radiology. 2016;28(1):61.
9. Varkhede A, Tupkari J, Mandale M, Sardar M. Plexiform ameloblastoma of mandible: Case report. 2010.
10. Reichart PA, Philipsen HP. Odontogenic tumors and allied lesions: Quintessence Pub.; 2004.
11. Small IA, Waldron CA. Ameloblastomas of the jaws. Oral surgery, oral medicine, and oral pathology. 1955;8(3):281-97.
12. Malathi N, Giri G, Pandyan DA, Suganya R, Thamizhchelvan H. Acanthomatous Ameloblastoma of Mandible in a Paediatric Patient. Case reports in pediatrics. 2018;2018.

PP- 0273

THE CONCRESCENCE OF DİLATED ODONTOMA AND IMPACTED SECOND MOLAR: A UNİQUE CASE REPORT WİTH CONE BEAM COMPUTERİZED TOMOGRAPHY (CBCT) FİNDİNGS

Ömür Dereci [a], Nesrin Saruhan [b], Görkem Tekin [c]

A-Eskişehir Osmangazi University, Faculty of Dentistry, Department of Oral and Maxillofacial Surgery, Eskişehir, Turkey, omurdereci@hotmail.com

B- Eskişehir Osmangazi University, Faculty of Dentistry, Department of Oral and Maxillofacial Surgery, Eskişehir, Turkey, dt_nesrin@yahoo.com

C-Eskişehir Osmangazi University, Faculty of Dentistry, Department of Oral and Maxillofacial Surgery, Eskişehir, Turkey, dt.gorkemtekin@gmail.com

Abstract

Objective: Dilated odontome is the most severe form of dens invaginatus (dens in dente), which is extremely rare in the mandible, especially in the molar region. The lesion appears as a roughly spherical mass that does not resemble a tooth but looks like a tooth on radiographs due to similar radiodensity.

Case: Twenty-seven years old male patient was referred to Eskişehir Osmangazi University, Faculty of Dentistry, Department of Oral and Maxillofacial Surgery for routine dental examination. An odontoma-like lesion fused with the distal root of the impacted second molar tooth was incidentally observed in the panoromic radiography. Under local anesthesia, the lesion was removed together with the second molar tooth and sent for histopathological examination. A diagnosis of dilated odontoma was made on histopathological examination.

Conclusion: Analysis of a large collection of specimens is needed to clarify the prevalence, characteristics, and occurrence of a dilated odontoma. Histolopathological examination is essential for the correct diagnosis.

Keywords: Dilated odontoma, dens in dente, mandible, molar

1.Introduction

Dens invaginatus (dens in dente, dilated odontoma) is a developmental dental anomaly that shows a wide range of morphological variations caused by the infolding of the enamel organ into the dental papilla before the mineralization phase(1). It has been reported that the incidence of dilated odontoma ranges from 0.25% to 10%(2). The most widely used classification is the classification proposed by Oehlers(3) who defined the anomaly as occuring in 3 forms. In Type 1, a minor form, the enamel-lined invagination is confined within the crown of the tooth without extending beyond the amelocemental junction. In type 2, the enamel-lined invagination extends apically beyond the cementoenamel junction but remains within the root. In Type 3, the enamel-lined invagination extends apically beyond the junction of the enamel-cemental junction and perforates the surface of the root to compose a second apical foramen. In the most severe form, entitled a dilated odontoma, the tooth has a circular or oval shape with a radiolucent interior and usually presents a single structure with a central mass of soft tissue(4). It most frequently affects the permanent maxillary lateral incisors, followed by the maxillary central incisors, premolars and canines, and less often the posterior teeth(5). Although dilated odontoma in the molar region of the mandible is rare, only a few cases have been reported in the recent literature(6).

2.Case Report

Twenty seven years old male patient was referred to Eskişehir Osmangazi University, Faculty of Dentistry, Department of Oral and Maxillofacial Surgery for routine dental examination. An odontoma-like lesion fused with the distal root of the impacted second molar tooth was incidentally observed in the panoromic radiography (Figure 1). Medical and dental anamnesis were non-contributory. Patient was sent for Cone Beam Computerized Tomography (CBCT) imaging for further evaluation.(Planmeca Promax 3D Classic, 84 kV, 16 mA, Finland) The lesion distal to the impacted third molar was a tooth-like structure with a radioluscent chamber surrounded with tooth material in CBCT sections.(Figure 2) Dilated structure was fused and showed continuity with the distal root of impacted left second molar (Figure 3). The lesion was diagnosed as fusion of dilated odontoma and impacted second molar and patient was scheduled for surgical excision.

After regional local anesthesia (Ultracain D-S forte, Sanofi-Aventis GmbH, Germany), an envelope incision with releasing vertical incisions was performed. The upper part of the lesion was exposed after adequate bone removal (Figure 4). Although the complete exposure and intact excision of the lesion was planned before the operation, it was almost impossible to extract the lesion as whole due to anatomical restrictions and inadequate sight of the surgical site. Therefore, lesion was sectioned into several parts and excised (Figure 5).

There was mature dentin in the histopathological diagnosis. The final diagnosis was made as odontoma in the combination of radiological and histopathological findings (Figure 6).

3.Discussion

At first, radiographic appearance reminded type 3 dense in dente, however, there was no sign of enamel elongation or invagination into root structure and there was not any evident connection between peri-radicular tissue and dental pulp. Careful evaluation of CBCT sections revealed that there was a total isolation of radioluscent content of the whole lesion including the bulbous part. Therefore, it can be speculated that the lesion appears to be a shape anomaly of impacted second molar tooth or a fusion anomaly between second molar and malformed impacted third molar tooth. Odontoma fused with impacted third molar may be considered as another option in the differential diagnosis. Odontomas occuring as a fused body with permanent teeth are reported in several studies in the literature (7). However, this hypothesis remains weak because the differentiation level of odontomas does not allow a cavernous malformation with a radioluscent content. The odontogenic tissues of dentin, enamel and cement are randomly dispersed into the collagenous stroma without any sign of tissue organogenesis. The best option in the diagnosis seems to be an aberrant root malformation of impacted second molar.

4.Conclusion

Dental anomalies may be classified according to shape, number and structure. Shape malformations of impacted teeth are rare and confused with odontomas in clinical and radiographic examination.

5.References

1. Matsusue Y, Yamamoto K, Inagake K, Kirita T. A dilated odontoma in the second molar region of the mandible. The Open Dentistry Journal. 2011;5:150.
2. Alani A, Bishop K. Dens invaginatus. Part 1: classification, prevalence and aetiology. International endodontic journal. 2008;41(12):1123-36.
3. Oehlers F. Dens invaginatus (dilated composite odontome): I. Variations of the invagination process and associated anterior crown forms. Oral Surgery, Oral Medicine, Oral Pathology. 1957;10(11):1204-18.
4. Oehlers F. Dens invaginatus (Dilated composite odontome): II. Associated posterior crown forms and pathogenesis. Oral Surgery, Oral Medicine, Oral Pathology. 1957;10(12):1302-16.
5. Hovland EJ, Block RM. Nonrecognition and subsequent endodontic treatment of dens invaginatus. Journal of endodontics. 1977;3(9):360-2.
6. Yamamoto K, Morimoto Y, Kawakami T, Mishima K, Shiotani H, Sugimura M. A case of dilated odontoma arising in buccal region of 3rd molar tooth of mandible. Journal of the Japanese Stomatological Society. 1999;48:395-9.
7. Neugebauer J, Zöller J. Cone Beam Volumetric Imaging in Dental, Oral and Maxillofacial Medicine : Fundamentals, Diagnostics, and Treatment Planning, Second Edition, Quintessence Publishing Co. Ltd., Berlin, p.142

6.Figures

Figure 1. Radiopaque lesion fused with the distal root of the mandibular left second molar tooth

Figure 2. The lesion distal to the impacted second molar was a tooth-like structure with a radioluscent chamber surrounded with tooth material

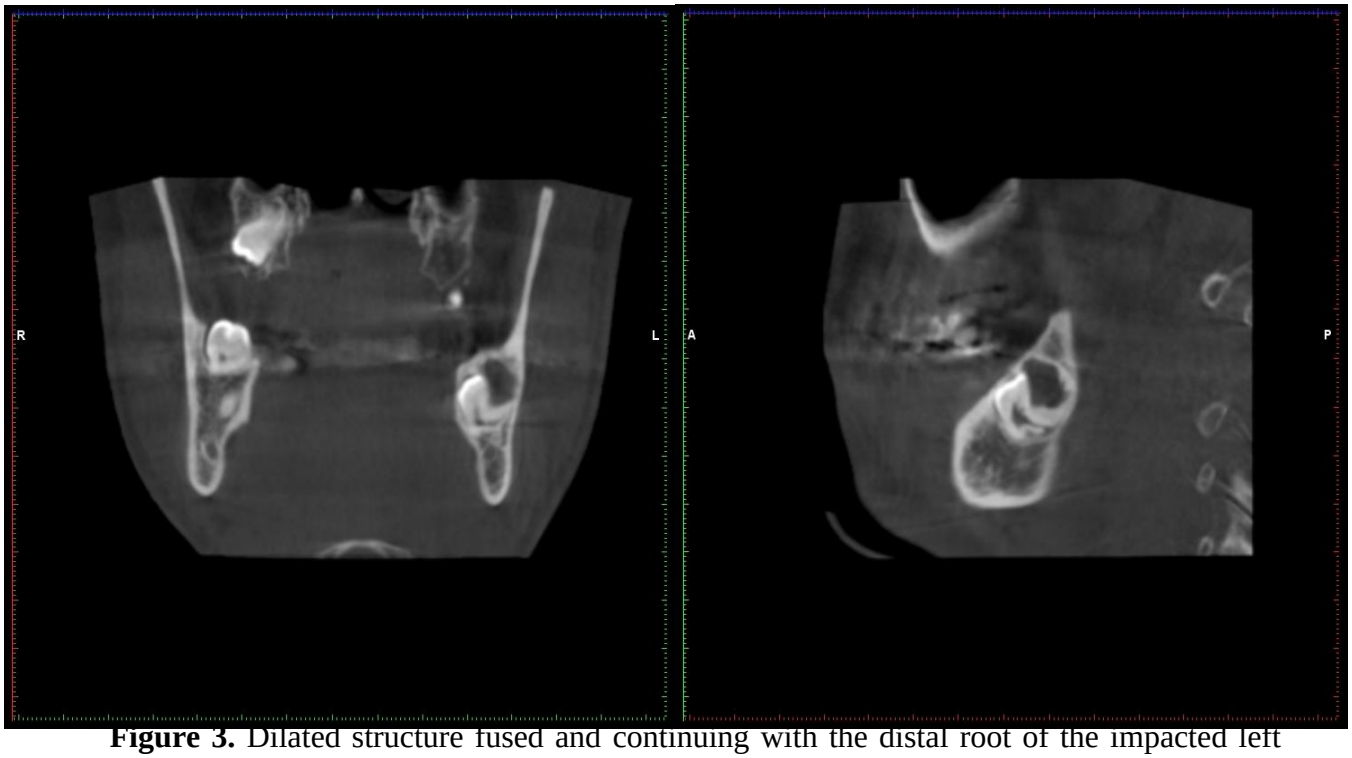

Figure 3. Dilated structure fused and continuing with the distal root of the impacted left second molar

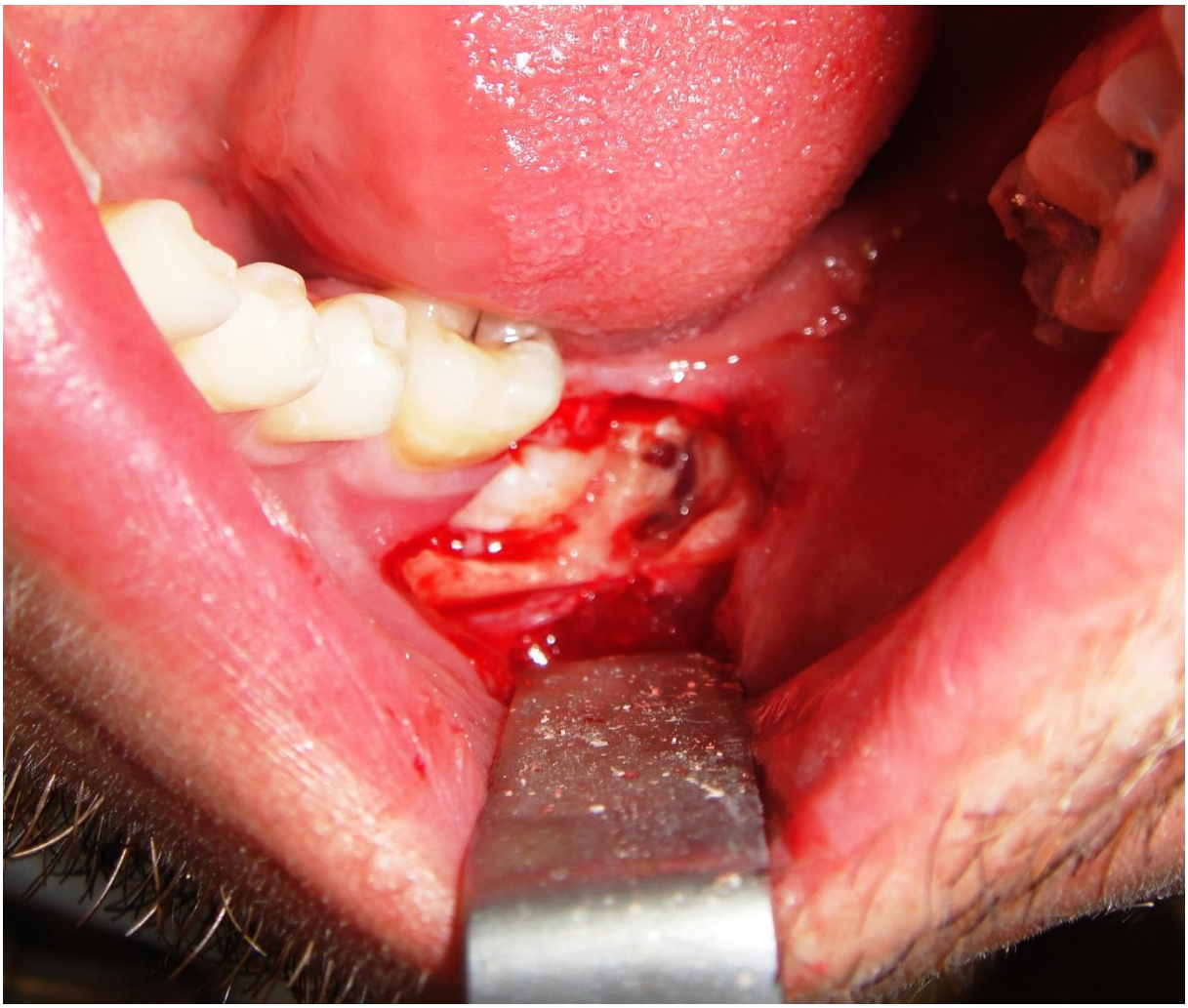

Figure 4. Perioperative intraoral view

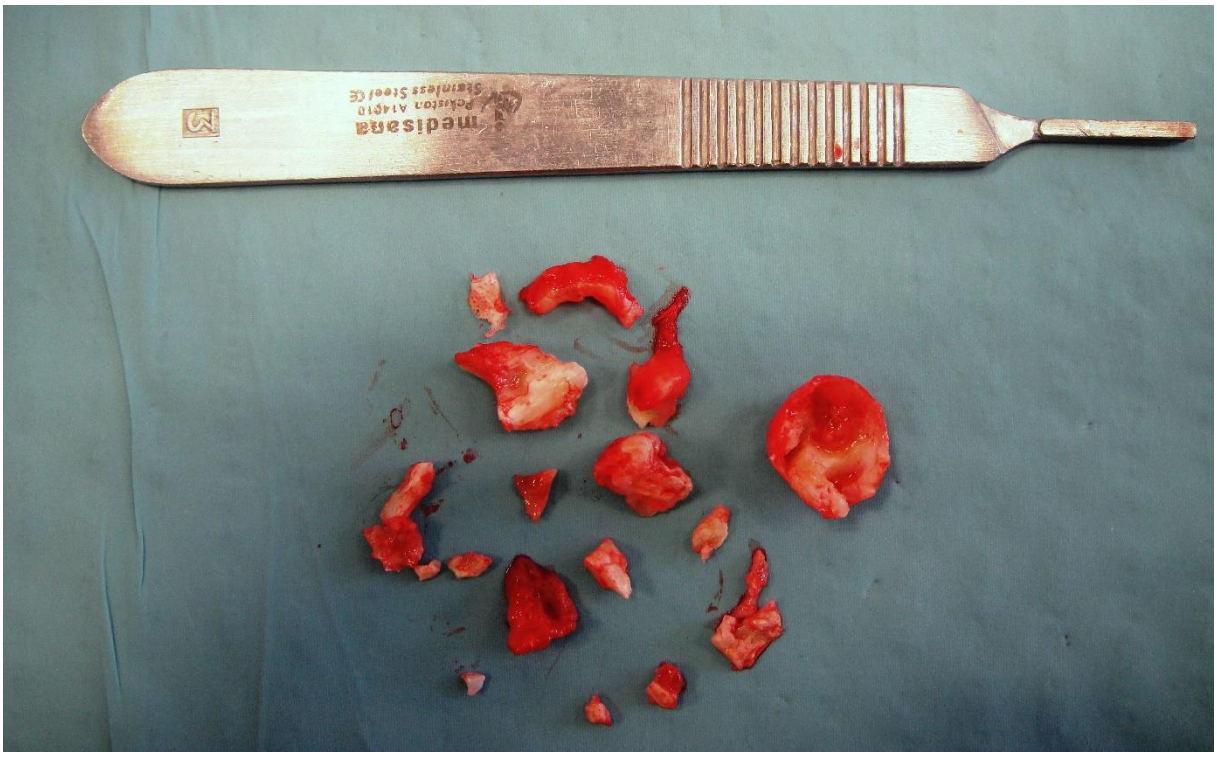

Figure 5. Lesion that is divided into several parts and excised

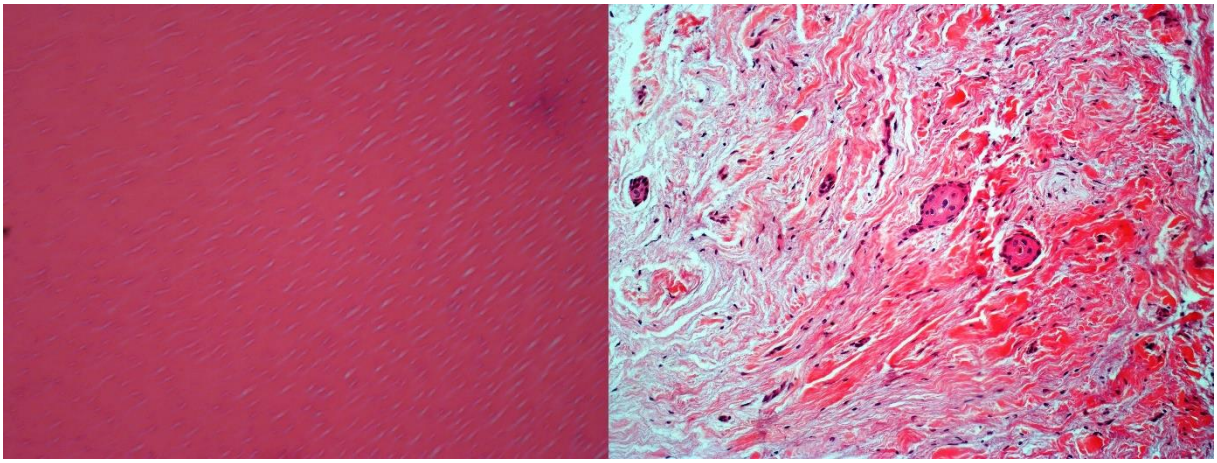

Figure 6. Mature dental tissue elements were seen in the histopathological examination.

6.Figures

Figure 1. Intraoral periapical radiography showing multilocular radiolucency

Figure 2. Panoramic radiography revealed multilocular radiolucencies extending from the region of 36 to 33

Figure 3. Biopsy specimen under local anesthesia

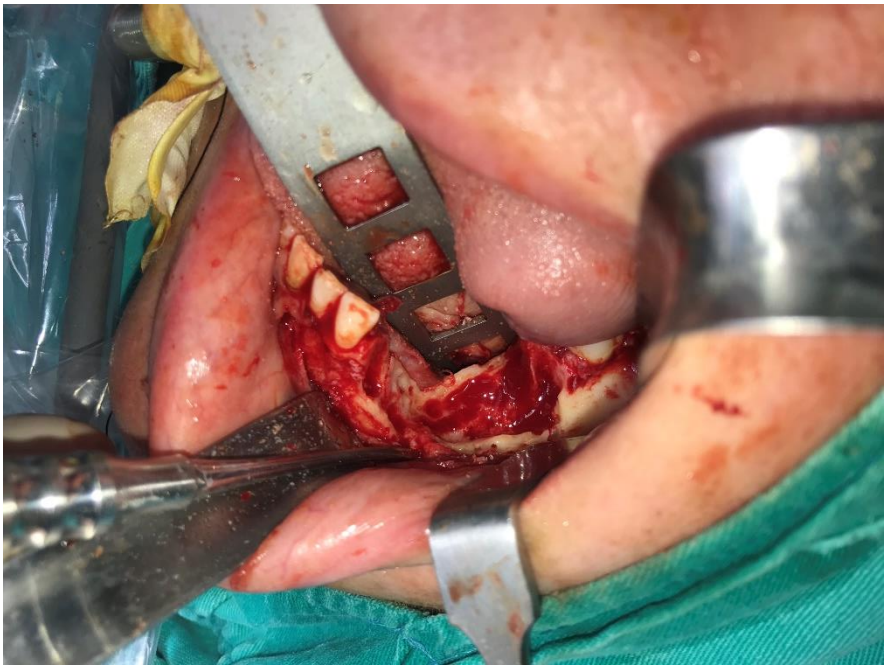

Figure 4. Perioperative intraoral view after the resection of the lesion

Figure 5. Specimens removed during the operation

Figure 6. Posttreatment panoramic radiography

6. Figures

Figüre 1: Preoperative tongue size

Figure 2: Postoperative 5th day

Figure 3: After tongue reduction and orthognathic surgery operations (1 year after tongue reduction)

TAOMS'20

INDEX

www.taoms2020.org

TAOMS’20